



Seven cases illustrating difficulties in the treatment of MPO-ANCA-positive refractory otitis media

メタデータ	<p>言語: English</p> <p>出版者: The Fukushima Society of Medical Science</p> <p>公開日: 2024-12-04</p> <p>キーワード (Ja):</p> <p>キーワード (En): Anti-neutrophil cytoplasmic antibody (ANCA)-associated vasculitis (AAV), myeloperoxidase (MPO)-ANCA, proteinase 3 (PR3)-ANCA, Humans, Female, Male, Middle Aged, Aged, Otitis Media, Peroxidase, Aged, 80 and over, Antibodies, Antineutrophil Cytoplasmic, Anti-Neutrophil Cytoplasmic Antibody-Associated Vasculitis</p> <p>作成者: Otsuki, Koshi, Imaizumi, Mitsuyoshi, Murono, Shigeyuki</p> <p>メールアドレス:</p> <p>所属:</p>
URL	<p>https://fmu.repo.nii.ac.jp/records/2002108</p>



Seven cases illustrating difficulties in the treatment of MPO-ANCA-positive refractory otitis media

Koshi Otsuki¹⁾, Mitsuyoshi Imaizumi²⁾ and Shigeyuki Murono²⁾

¹⁾Otsuki ENT Clinic, ²⁾Department of Otolaryngology Fukushima Medical University, Fukushima, Japan

(Received April 27, 2023, accepted April 12, 2024)

Abstract

There are increasing reports of patients with refractory otitis media caused by anti-neutrophil cytoplasmic antibody (ANCA)-associated vasculitis (AAV), especially myeloperoxidase (MPO)-ANCA-positive middle ear disease. However, making a definitive diagnosis can be difficult, which can adversely affect the outcome of treatment. We reviewed the diagnostic features of MPO-ANCA-positive middle ear disease and here discuss the difficulties of timely diagnosis and treatment. Seven cases were eligible (6 women, 1 man ; aged 57-83 years), and all were MPO-ANCA positive and proteinase 3 (PR3)-ANCA negative. The patients were referred to our institution for management of intractable otitis media (2/7), progressive hearing loss (7/7) with facial palsy (1/7), and/or a high MPO-ANCA titer (5/7). All patients underwent tapering steroid therapy and their MPO-ANCA titer was monitored. Refractory MPO-ANCA-positive otitis media was noted : 5 of 7 cases showed improvement with tapering steroid therapy but cure was not achieved in the remaining 2 cases. This study demonstrates the difficulties in the diagnosis and treatment of localized AAV. Early diagnosis and treatment can improve the prognosis of patients with AAV but global diagnostic criteria for ear disease have not been established. Additional cases should be prospectively examined to establish a treatment for MPO-ANCA-positive middle ear disease.

Key words : Anti-neutrophil cytoplasmic antibody (ANCA)-associated vasculitis (AAV), myeloperoxidase (MPO)-ANCA, proteinase 3 (PR3)-ANCA

Introduction

Patients with refractory otitis media caused by antineutrophil cytoplasmic antibody (ANCA)-associated vasculitis (AAV), and particularly myeloperoxidase (MPO)-ANCA-positive middle ear disease, have been reported recently. AAV is characterized by systemic necrotizing vasculitis and is classified into categories based on histologic features and the size of involved vessels (from largest to smallest). AAV is included in the category of vasculitis syndrome of small vessels and includes microscopic polyangiitis (MPA), eosinophilic granulomatosis with polyangiitis (EGPA ; formerly Churg-Strauss syndrome), and granulomatosis with polyangiitis

(GPA ; formerly Wegener's granulomatosis)¹⁾.

AAV is a clinically important, life-threatening disease, and serious organ dysfunction has been associated not only with the vasculitis itself, but also with its treatment. It is important to know the range of clinical manifestations for the early diagnosis of this disease. While early diagnosis of AAV is extremely important, it is often problematic. Patients with refractory otitis media caused by AAV do not fulfill the ordinary diagnostic criteria for systemic AAV, such as the Japanese Ministry of Health, Labour and Welfare (JMHLW) criteria²⁾ and the Chapel Hill Consensus Conference (CHCC) algorithm³⁾. Because of the recent increase in the number of patients with AAV of the upper respiratory tract alone,

Corresponding author : Koshi Otsuki E-mail : otsuki.jibika@gmail.com

©2024 The Fukushima Society of Medical Science. This article is licensed under a Creative Commons [Attribution-NonCommercial-ShareAlike 4.0 International] license.
<https://creativecommons.org/licenses/by-nc-sa/4.0/>

involving, for example, the ear, nose, and larynx, otolaryngologists can play an important role in early diagnosis and treatment.

In this study, we reviewed the diagnostic features of MPO-ANCA-positive middle ear disease to highlight the diagnostic difficulties often encountered. We discuss the difficulties of treatment and draw the attention of otolaryngologists and other clinicians to issues that are important for the timely diagnosis and treatment of this disease.

Descriptive Characteristics of Cases

We retrospectively investigated the cases of 7 MPO-ANCA-positive patients (6 women, 1 man ; age 57-83 years) who initially complained of otologic symptoms and were referred to Fukushima Medical University. The clinical features of all cases are summarized in Tables 1 and 2. Notably, all cases showed the following findings : positive MPO-AN-

CA (above the reference range of <3.5 EU), negative proteinase 3 (PR3)-ANCA (<10 EU), and middle ear effusion. All patients had tapering steroid therapy and their MPO-ANCA titer was monitored.

Pertinent clinical information and follow-up data were obtained from the hospital charts for all cases. This study was approved by the Fukushima Medical University Ethics Committee (approval number : 2888).

Case 1

A 57-year-old woman was referred to us with intractable bilateral hearing loss with middle ear effusion, following 5 months of treatment. Clinical findings are shown in Fig. 1 (A-E). Examination revealed bilateral middle ear effusion and we performed myringotomy and antibiotic administration, but her condition did not improve. We inserted a tympanic ventilation tube, but the discharge continued. One month later, she experienced in-

Table 1. Clinical features of 7 patients with MPO-ANCA-positive refractory otitis media

No	Age (Yr/Sex)	MPO-ANCA (EU)	PR3-ANCA (EU)	Onset to diagnosis (Mo)	Other Involvement	Bacterial culture test	WBC (/μl)	Eos (%)	CRP (mg/dl)	T-SPOT. TB	Treatment	MPO-ANCA (EU) post treatment
1	57/F	37	—	5	—	—	5,600	2	0.7	—	S	<1.0
2	71/F	285	—	3	—	—	7,100	1	1.09	—	S	<1.0
3	81/F	17	—	4	—	—	9,400	2	0.4	—	S	<1.0
4	69/M	210	—	3	—	—	7,500	0	19.59	—	S+C	237
5	70/F	301	—	8	—	—	9,700	0.7	6.86	—	S	4
6	83/F	192	—	1	—	—	10,200	0	0.83	—	S	92.6
7	81/F	279	—	6	—	—	8,800	0	1.87	—	S+R	1.7

MPO-ANCA : myeloperoxidase anti-neutrophil cytoplasmic antibody, PR3-ANCA : proteinase 3 anti-neutrophil cytoplasmic antibody, WBC : white blood cell, Eos : eosinophils, CRP : C-reactive protein, T-SPOT.TB : commercial interferon-γ assays to diagnose tuberculosis (Oxford Immunotec, Abingdon, UK), S : steroid, C : cyclophosphamide, R : rituximab.

Bacterial culture and T-SPOT. TB tests were performed in all cases, and the results were all negative.

Table 2. Clinical features of hearing loss before and after treatment in our 7 patients

No	Age (Yr/Sex)	Right average hearing level (dB)	Post treatment (dB)	Left average hearing level (dB)	Post treatment (dB)	Treatment effect
1	57/F	37	21	89	81	Recovery (right)
2	71/F	16	34	84	39	Prominent recovery (left)
3	81/F	68	84	105	93	Recovery (left)
4	69/M	72	63	44	42	Unchanged
5	70/F	103	103	102	100	Unchanged
6	83/F	46	38	86	73	Recovery
7	81/F	105	68	103	74	Prominent recovery

total recovery : hearing level at 0.25 kHz, 0.5 kHz, 1 kHz, 2 kHz, and 4 kHz returned to within 20 dB, prominent recovery : when the arithmetic mean of the above five frequencies improves by 30 dB or more, recovery : by 10 to 30 dB, unchanged : by less than 10 dB (criteria for sudden hearing loss and hearing recovery ; Japanese Ministry of Health, Labour and Welfare).

complete facial palsy on her left side. Temporal bone computed tomography (CT) revealed bilateral soft tissue density masses in both the mastoid and middle ear cavities. Exploratory mastoidectomy revealed middle ear granulation tissue, and histopathology showed no specific features of GPA. Serologic examination showed MPO-ANCA 37 EU/ml. She was started on prednisolone 40 mg/d. Her bilateral hearing loss was slightly improved, and the

facial palsy recovered completely. Following treatment, her MPO-ANCA titer returned to the reference range.

Case 2

A 71-year-old woman was referred to us with left hearing loss with intractable otitis media with effusion and tinnitus, following 3 months of treatment. Clinical findings are shown in Fig. 2.

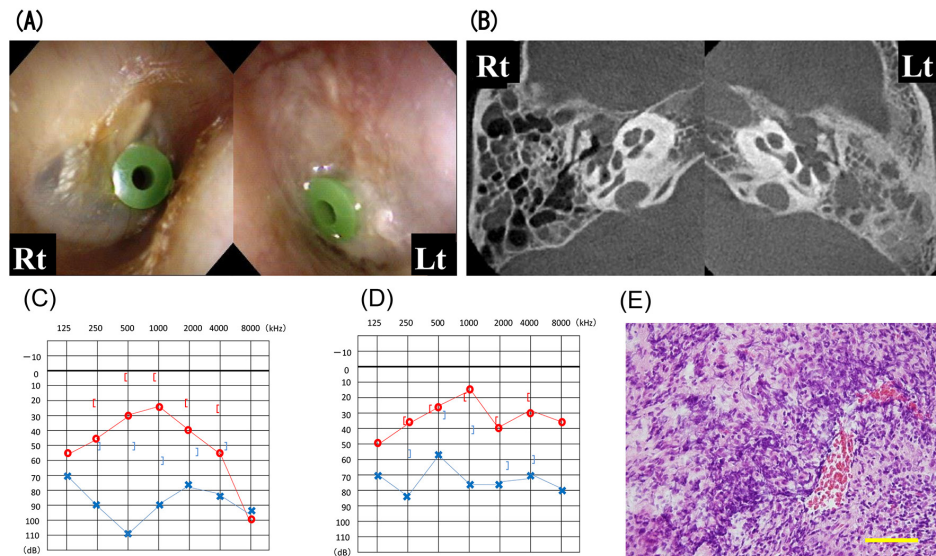


Fig. 1. Representative findings of MPO-ANCA-positive refractory otitis media in Case 1. (A) A reddish eardrum with otitis media with mucinous effusion, with no granulation tissue observed from the tympanostomy incision in the tympanic cavity. (B) Temporal bone computed tomography showing the tympanic cavity and mastoid cells filled with soft tissue material without bone destruction. (C) Audiogram on admission. (D) audiogram after treatment showing slightly improved hearing loss. (E) Mastoid biopsy specimen (H-E stain ; original $\times 400$, Bar 50 μm) showing only non-specific inflammatory cell infiltrates and necrotic tissues.

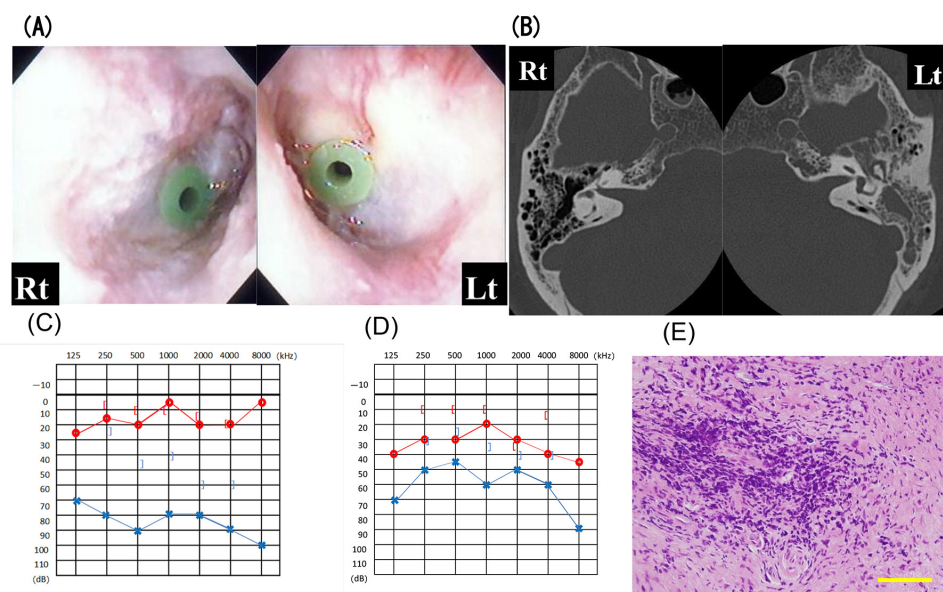


Fig. 2. Corresponding representative findings in Case 2. (A) eardrum, (B) temporal bone computed tomography, (C) audiogram on admission, (D) audiogram after treatment, and (E) mastoid biopsy specimen (H-E stain ; original $\times 400$, Bar 50 μm).

We observed bilateral middle ear effusion on examination. As in Case 1, myringotomy, antibiotics, and a tympanic ventilation tube did not improve her condition, and temporal bone CT revealed bilateral soft tissue density masses in the mastoid and middle ear cavities. Exploratory mastoidectomy also revealed middle ear granulation tissue, and there was no evidence of GPA specifically on histopathology. Serologic examination showed MPO-ANCA 285 EU/ml. She was started on prednisolone 50 mg/d. She recovered some hearing in the left ear (approximately 40-dB improvement) as her MPO-ANCA serum titer decreased. Her MPO-ANCA titer returned to the normal range after treatment.

Case 3

An 81-year-old woman was referred to us with a high MPO-ANCA titer and bilateral hearing loss with intractable otitis media with effusion, following 4 months of treatment. We confirmed bilateral middle ear effusion, which did not improve with myringotomy or antibiotics. Serologic examination showed MPO-ANCA 17 EU/ml. She was started on prednisolone 10 mg/d and her bilateral hearing level recovered slightly. After treatment, her MPO-ANCA titer returned to the normal range.

Case 4

A 69-year-old man recovered spontaneously from right incomplete peripheral facial nerve paralysis, but he subsequently experienced left incomplete peripheral facial nerve paralysis and otalgia. He was referred to us with a high MPO-ANCA titer and right hearing loss. We saw no middle ear effusion on the ENT examination. Serologic examination showed MPO-ANCA 210 EU/ml. Tapered steroid therapy completely resolved the facial palsy and otalgia, but an ENT examination 3 months later revealed bilateral middle ear effusion. Despite myringotomy, his MPO-ANCA titer elevated to 994 EU without any improvement in hearing loss. He is continuing treatment with steroids and cyclophosphamide.

Case 5

A 70-year-old woman was initially treated for left hearing loss and was referred to us with a high MPO-ANCA titer and progressive bilateral hearing loss over 8 months. We observed bilateral middle ear effusion and inserted a tympanic ventilation tube. Serologic examination showed MPO-ANCA 301 EU/ml. She was started on prednisolone 40

mg/d and her MPO-ANCA titer returned to 4.0 EU/ml after treatment but without recovery of the bilateral hearing loss.

Case 6

An 83-year-old woman was referred with a high MPO-ANCA titer and left hearing loss with middle ear effusion, following treatment of left otalgia for 1 month. We found left middle ear effusion on ENT examination. Myringotomy improved the inflammation. Serologic examination showed MPO-ANCA 192 EU/ml and PR3-ANCA < 10 EU. Following a tapered course of prednisolone started at 30 mg/d, her MPO-ANCA titer decreased to 92.6 EU/ml and her bilateral hearing loss recovered slightly. She is continuing with steroid therapy.

Case 7

An 81-year-old woman was referred with a high MPO-ANCA titer and bilateral hearing loss with middle ear effusion, following treatment of otalgia for 6 months. We found left middle ear effusion on ENT examination. Myringotomy improved the inflammation, and we inserted a tympanic ventilation tube. Serologic examination showed MPO-ANCA 279 EU/ml and PR3-ANCA < 10 EU. Following a tapered course of prednisolone and subsequent initiation of rituximab at 40 mg/d, her MPO-ANCA titer returned to 1.7 EU/ml and her bilateral hearing loss showed marked improvement. She is continuing with steroid therapy.

In summary, all 7 cases were MPO-ANCA positive and proteinase 3 (PR3)-ANCA negative. Patients were referred to our institution for management of intractable otitis media (2/7), progressive hearing loss (7/7) with facial palsy (1/7), and high MPO-ANCA titer (5/7). All patients underwent tapering steroid therapy and their MPO-ANCA titer was monitored. Some cases of MPO-ANCA-positive otitis media were refractory: 5 of the 7 cases showed improvement with steroid therapy, but a cure could not be achieved in the 2 remaining cases.

Discussion

PR3-ANCA and MPO-ANCA

AAV is characterized by systemic necrotizing vasculitis and patients fall into two groups: those with PR3-ANCA and those with MPO-ANCA. In the present study, all of our patients with AAV were MPO-ANCA positive, PR3-ANCA negative, and had effusion in the middle ear. In a report on the fre-

quency of ear symptoms in the two groups, Nakamaru *et al.* reported that all patients with chronic otitis media were PR3-ANCA positive, whereas 89% of patients in the MPO-ANCA group had secretory otitis media⁴. Furthermore, previous studies reported that for GPA, the PR3-ANCA titer has 66% diagnostic sensitivity and MPO-ANCA has 24% sensitivity; for MPA, PR3-ANCA has 26% sensitivity and MPO-ANCA 50% to 80% sensitivity^{5,6}.

Most patients (70–80%) with GPA are positive for PR3-ANCA and few (10%) are positive for MPO-ANCA, and it was reported that serum MPO-ANCA was positive in some patients with histopathologically diagnosed GPA^{7–10}. Therefore, MPO-ANCA-positive middle ear disease should be classified as a subtype of GPA despite the lack of histopathological evidence of vasculitis.

Thus, elevation of PR3-ANCA or MPO-ANCA titer is one of the diagnostic criteria for AAV. In our study, all 7 cases with the disorder had ear symptoms that did not conform to the current Japanese diagnostic criteria.

Epidemiology

The epidemiology of systemic vasculitides differs between Japan, Europe, and North America¹¹. For example, Takayasu's arteritis occurs frequently and MPA- and MPO-ANCA-associated vasculitides are more common in Japan, while GPA- and PR3-ANCA-associated vasculitides are more common in the United Kingdom¹².

Watanabe *et al.*¹³ reported that MPO-ANCA-related nephritis constitutes 60% of rapidly progressive glomerulonephritis (RPGN) cases in Japan. In a previous study comparing patient backgrounds regarding ANCA-related vasculitides in Japan and the United Kingdom, Japanese cases were older (72 vs. 61 years), predominantly subtype MPA, and had fewer cases of GPA. In addition, ANCA patterns revealed that 80% of cases in Japan were MPO-ANCA, while about 66% of cases in the United Kingdom were PR3-ANCA¹⁴. GPA usually progresses in the order of upper airway (ear), lung, and kidney. The condition without renal symptoms is referred to as localized GPA, and Japan has a higher incidence of this compared with other countries¹⁵. It is essential, therefore, that otolaryngologists who are familiar with GPA findings be involved early in the diagnostic process.

Pathology

The specimens obtained from the mastoid cavity during mastoidectomy showed only nonspecific

inflammatory cell infiltrates and necrotic tissue in Cases 1 and 2. We opted to perform mastoidectomy for confirmatory diagnosis in Cases 1 and 2 because it is difficult to determine whether AAV-induced intractable otitis media is associated with GPA, MPA, or EGPA at the initial visit. After all, no other AAV-related organ lesions are evident and neither case fulfilled the ordinary diagnostic criteria for systemic AAV, such as the JMHLW criteria and CHCC algorithm.

AAV sometimes develops with initial symptoms affecting the head and neck region¹⁶. It can be difficult to make a diagnosis from tissue biopsied from the affected region, including the upper airway, because the specimens obtained are often small, making it difficult to make a definitive pathological diagnosis in all cases¹⁷. In addition, taking biopsy specimens from the middle ear may result in facial palsy and worsening of ear symptoms associated with AAV¹⁸. Thus, clinicians can find it difficult, or even impossible, to identify the pathologic features of GPA.

It was reported that both vasculitis and necrosis were found in 23% of upper-airway biopsy specimens, vasculitis and granulomatous inflammation were present in 21%, while vasculitis, necrosis, and granulomatous inflammation were present in only 16%^{19,20}. Diagnostically useful tissue in the upper airway was obtained, in decreasing order of frequency, from the paranasal sinuses, nose, and subglottic region. This order may reflect the quantity of tissue usually obtainable by biopsy. For example, previous studies reported that combined vasculitis and necrosis were found in 89% of samples taken from 82 open lung biopsies, whereas vasculitis was identified in only 4 specimens (7%) and granulomas were present in 3 of the 4 specimens of 59 transbronchial biopsies done in 48 patients^{19,21}.

This difficulty in diagnosis often delays the initiation of treatment, occasionally allowing the disease to progress to an irreversible phase. Early diagnosis and treatment can prevent the need for dialysis and improve the prognosis of patients with AAV. CT and magnetic resonance imaging (MRI) are especially important when hypertrophic cranial pachymeningitis is suspected in cases of incurable headache, and cystography should be used for confirmatory diagnosis.

Etiology

A clinical feature of MPO-ANCA-associated hearing loss is that it is reversible if the hearing loss has not progressed to deafness. Significant recov-

ery of hearing from sudden deafness due to ischemia of the cochlear microcirculation typically occurs within 1 to 2 months of onset. On the other hand, AAV patients have exhibited considerable reversibility in hearing levels with immunosuppressive therapy even after several months of hearing loss²². This reversibility indicates the hair cells are intact in the pretreatment state.

In GPA, the ear is frequently affected and many published studies describe clinical findings in this disease. In a clinical study of GPA, otologic involvement was commonly reported, with an incidence ranging from 19% to 47%²³. McDonald *et al.*²⁴ note three basic types of otologic involvement: (1) serous otitis media caused by nasopharyngeal ulceration and obstruction of the eustachian tube, (2) destruction of the middle ear and mastoid caused by actual involvement of the middle ear and mastoid cavity by GPA, and (3) sensorineural deficit caused by inflammation of the cochlear vessels. Common histologic findings are granulation tissue and bone absorption in the middle ear. Very few cases have inner ear lesions.

GPA can involve the middle ear and/or inner ear, causing conductive, sensorineural, or mixed hearing loss. An autoimmune inner ear disease is thought to cause sensorineural hearing loss in GPA. Okamura *et al.*²⁵ reported a patient with GPA in whom sensorineural hearing loss was attributed to angitis based on a positive antihuman neutrophil cytoplasm antibody test and improvement with steroid therapy. Ohtani *et al.*²⁶ reported that the histopathology of GPA showed slightly atrophic stria vascularis and well-preserved spiral ganglion cells. Tympanic granulation tissue and inflammatory substances could also invade the inner ear through the round window. The histopathology of the temporal bone in GPA associated with complete deafness showed tympanic granulation tissue invasion of the round window niche and round window membrane, and projection into the tympanic duct.

Facial nerve palsy has also been reported as an initial symptom in GPA or as a presenting symptom associated with ear symptoms. Ohtani *et al.*²⁶ also reported that the bony canal of the horizontal portion of the facial nerve is destroyed by granulation tissue that fills the tympanic cavity.

Treatment

Five of our 7 cases showed improvement with tapering steroid therapy and MPO-ANCA titer decreased in most cases. Although several clinical practice guidelines for the treatment of systemic

AAV are available, therapies for AAV localized to the upper respiratory tract have not yet been standardized. Harabuchi *et al.* reported that treatment of ANCA-positive middle ear disease with glucocorticoids (GCs) and immunosuppressants could prevent disease relapse and progression of hearing loss more effectively than treatment with GCs alone. Based on the outcomes obtained with recent treatment guidelines, combined administration of both GCs and immunosuppressants is recommended as therapy for ANCA-positive middle ear disease²⁷.

For AAV with lesions localized to the ear, prednisolone (0.3–1 mg/kg/day) and oral cyclophosphamide (25–75 mg/body/day) are recommended for remission induction therapy. For disease limited to the upper respiratory tract, the immunosuppressants recommended by recent clinical guidelines are monthly cyclophosphamide for pulse therapy (15 mg/kg/month) or oral azathioprine (0.5–1.5 mg/kg/day), and methotrexate (15–25 mg/week) every alternate week, as recommended by JMHLW. PSL dose reduction begins 1–2 weeks after local and hearing levels show remission, and the dose is tapered by 5–10 mg weekly up to 15–20 mg/day, which is maintained for at least 3 months².

Prednisolone plus cyclophosphamide therapy is effective and remission can be achieved once in most patients with disease limited to the middle ear. However, long-term administration of cyclophosphamide can easily cause side effects such as infection, hematopoiesis, infertility, and bladder bleeding, and also carries a risk of carcinogenesis (mainly bladder cancer)²⁸.

Harabuchi *et al.* studied 91 patients with GPA who were managed by an otolaryngologist in Japan. The upper respiratory tract alone was involved in 51 cases (56%). Although 21 of the 51 cases (41%) did not meet the Japanese diagnostic criteria initially, 13 of the 21 (62%) subsequently developed additional symptoms and signs during the observation period that did meet these criteria^{27,28}.

Once initial regional AAV progresses systemically to organs, including the lung and kidney, and to the central nervous system in the absence of immunosuppressive therapy, AAV shows high mortality. It is important, therefore, that initial symptoms in the upper airway are considered with the inclusion of AAV in the differential diagnosis so that treatment can be started promptly. As infections are a trigger of AAV, this disease tends to localize in areas around the upper airway. Thus, otolaryngologists should be aware of the characteristic features of AAV-associated head and neck lesions and also that refractory

otitis media is sometimes a presenting symptom of AAV. They should check for the presence of ANCA in such cases as soon as possible. Moreover, since AAV is a systemic disease, multidisciplinary input is required, involving nephrologists, rheumatologists, pulmonologists, and otolaryngologists, among others.

The combination of cyclophosphamide and GCs leads to remission in most patients with ANCA-associated vasculitides. However, even when patients receive maintenance treatment with immunosuppressive drugs, the relapse rate remains high. Rituximab may help to maintain remission. Yashiro-Furuta *et al.* reported that rituximab was effective in Japanese AAV patients and may be useful for prompt tapering of prednisolone, even in elderly patients who develop AAV²⁹⁾. Furthermore, Yoshida *et al.* reported that after starting immunosuppressive therapy, ANCA titers rapidly returned to the normal range and hearing levels improved, but that complete deafness could not be reversed²²⁾. In the present case series, hearing in Case 7 recovered from almost complete deafness after administration of rituximab. However, rituximab plus steroid combination therapy has been recently identified as a risk factor for hepatitis B virus reactivation in HBsAg-negative patients³⁰⁾. Therefore, we should consult internal medicine physicians from the early period of immunosuppressive therapy to avoid the risk of complications.

Conclusion

This case series demonstrates the difficulties in the diagnosis and treatment of localized AAV. Early diagnosis and treatment can improve the prognosis of patients with AAV, although global diagnostic criteria for ear disease have yet to be established. Additional cases should be prospectively examined to establish the treatment for MPO-ANCA-positive middle ear disease.

References

1. Kallenberg CG, Heeringa P, Stegeman CA, *et al.* Mechanism of Disease : pathogenesis and treatment of ANCA-associated vasculitides. *Nat Clin Pract Rheumatol*, **2** : 661-670, 2006.
2. Harigai M, Narita I, Sudo T, *et al.* anti-neutrophil cytoplasmic antibody (ANCA)-associated vasculitis (AAV) Practice Guideline 2023 (In Japanese). *shindan to chiriyosya*, ISBN 978478782573, 2023.
3. Jennette JC. Overview of the 2012 Revised International Chapel Hill Consensus Conference Nomenclature of Vasculitides. *Clin Exp Nephrol*, **17**(5) : 603-606, 2013.
4. Nakamaru Y, Takagi D, Oridate N, *et al.* Otolaryngologic Manifestations of Antineutrophil Cytoplasmic Antibody Associated Vasculitis. *Otolaryngology Head and Neck Surgery*, **146** : 119-121, 2012.
5. Balow JE. Renal vasculitis. *Curr Opin Nephrol Hypertens*, **2** : 231-7, 1993.
6. Kallenberg CG. Pathogenesis of ANCA-associated vasculitides. *Ann Rheum Dis*, **70** : i59-63, 2011.
7. Kallenberg CG. Anti-neutrophil cytoplasmic antibodies : current diagnostic and pathophysiological potential. *Kidney Int*, **46** : 1-15, 1994.
8. Savige J, Gillis D, Benson E, *et al.* International Consensus Statement on testing and reporting of antineutrophil cytoplasmic antibodies (ANCA). *Am J Clin Pathol*, **111** : 507-513, 1999.
9. Rao JK, Weinberger M, Oddone EZ, *et al.* The role of antineutrophil cytoplasmic antibody testing in the diagnosis of Wegener granulomatosis. *Ann Intern Med*, **123** : 925-932, 1995.
10. Hagen EC, Daha MR, Hermans J, *et al.* Diagnostic value of standardized assays for anti-neutrophil cytoplasmic antibodies in idiopathic systemic vasculitis. EC/BCR project for ANCA assay standardization. *Kidney Int*, **53** : 743-753, 1998.
11. Kobayashi S, Fujimoto S. Epidemiology of vasculitides : differences between Japan, Europe and North America. *Clin Exp Nephrol*, **17** : 611-614, 2013.
12. Numano F. Differences in clinical presentation and outcome in different countries for Takayasu's arteritis. *Curr Opin Rheumatol*, **9** : 12-15, 1997.
13. Watanabe K, Tani Y, Kimura H, *et al.* Clinical Outcomes of Japanese MPO-ANCA-related Nephritis : Significance of initial renal death for survival. *Intern Med*, 1969-1976, 2012.
14. Fujimoto S, Watts RA, Kobayashi S, *et al.* Comparison of the epidemiology of anti-neutrophil cytoplasmic antibody-associated vasculitis between Japan and the U.K. *Rheumatology (Oxford)*, **50** : 1916-1920, 2011.
15. Hashimoto H. Study on clinical epidemiology investigation between Japan and Europe of the ANCA-related vasculitis and diagnostic agent and therapy development 2007 (in Japanese).
16. Takagi D, Nakamaru Y, Maguchi S, *et al.* Otolologic manifestations of Wegener's granulomatosis. *Laryngoscope*, **112** : 1684-1690, 2002.
17. Fauci AS, Haynes BF, Katz P, *et al.* Wegener's granulomatosis : prospective clinical and therapeutic experience with 85 patients for 21 years. *Ann Intern Med*, **98** : 76-85, 1983.
18. Nicklasson B, Stangeland N. Wegener's granulo-

- matosis presenting as otitis media : J Laryngol Otol, **96** : 277-280, 1982.
19. Hoffman GS, Kerr GS, Leavitt RY, *et al.* Wegener granulomatosis : an analysis of 158 patients. Ann Intern Med, **116** : 488-498, 1992.
 20. Devaney KO, Travis WD, Hoffman GS, *et al.* Interpretation of head and neck biopsies in Wegener's granulomatosis. A pathologic study of 126 biopsies in 70 patients. Am J Surg Pathol, **14** : 555-564, 1990.
 21. Travis WD, Hoffman GS, Leavitt RY, *et al.* Surgical pathology of the lung in Wegener's granulomatosis. Review of 87 open lung biopsies from 67 patients. Am J Surg Pathol, **15** : 315-333, 1991.
 22. Yoshida N, Hara M, Hasegawa M, *et al.* Reversible Cochlear Function With ANCA-Associated Vasculitis Initially Diagnosed by Otologic Symptoms. Otology & Neurotology, **35** : 114-120, 2013.
 23. McDonald TJ, DeRemee RA. Wegener's granulomatosis. Laryngoscope, **93** : 220-231, 1983.
 24. McDonald TJ, DeRemee RA, Weiland LH, *et al.* Wegener's granulomatosis and polymorphic reticulosis-two disease or one? Arch Otolaryngol, **107** : 141-144, 1981.
 25. Okamura H, Ohtani I, Anzai T, *et al.* The hearing loss in Wegener's granulomatosis : relationship between hearing loss and serum ANCA. Auris Nasus Larynx, **19** : 1-6, 1992.
 26. Ohtani I, Baba Y, Suzuki C, *et al.* Temporal bone pathology in Wegener's granulomatosis. Fukushima J Med Sci, **46** : 31-39, 2000.
 27. Harabuchi Y, Kishibe K, Tateyama K, *et al.* Clinical features and treatment outcomes of otitis media with antineutrophil cytoplasmic antibody (ANCA)-associated vasculitis (OMAAV) : a retrospective analysis of 235 patients from a nationwide survey in Japan. Mod Rheumatol, **27**(1) : 87-94, 2017.
 28. Harabuchi Y, Kishibe K, Tateyama K, *et al.* Clinical characteristics, the diagnostic criteria and management recommendation of otitis media with antineutrophil cytoplasmic antibody (ANCA)-associated vasculitis (OMAAV) proposed by Japan Otological Society. Auris Nasus Larynx, **48** : 2-14, 2021.
 29. Yashiro-Furuya, *et al.* Outcome of rituximab treatment in Japanese patients with ANCA-associated vasculitis in daily clinical practice : A two-centre study in Fukushima, Japan. Mod Rheumatol, **33**(2) : 352-359, 2023.
 30. Kusumoto S, Tanaka Y, Mizokami M, *et al.* Reactivation of hepatitis B virus following systemic chemotherapy for malignant lymphoma. Int J Hematol, **90** : 13-23, 2009.