



Ovarian strumal carcinoid: a case report

メタデータ	<p>言語: English</p> <p>出版者: The Fukushima Society of Medical Science</p> <p>公開日: 2023-04-07</p> <p>キーワード (Ja):</p> <p>キーワード (En): ovarian strumal carcinoid, clinical diagnosis, histopathological feature, treatment, case report</p> <p>作成者: Kanasugi, Masaru, Nishiyama, Hiroshi, Sanpei, Minoru, Asano, Shigeyuki, Honda, Tsuyoshi</p> <p>メールアドレス:</p> <p>所属:</p>
URL	https://fmu.repo.nii.ac.jp/records/2002069

[Case report]



Ovarian strumal carcinoid : a case report

Masaru Kanasugi¹⁾, Hiroshi Nishiyama¹⁾, Minoru Sanpei¹⁾,
Shigeyuki Asano²⁾ and Tsuyoshi Honda¹⁾

¹⁾Department of Obstetrics and Gynecology, Iwaki Kyouritsu Hospital, ²⁾Department of Pathology, Iwaki Kyouritsu Hospital

(Received June 27, 2022, accepted January 24, 2023)

Abstract

Background : Carcinoid tumors of the ovary are rare tumors, histopathologically classified as monodermal teratomas and somatic-type tumors arising from dermoid cysts. Their malignancy varies from borderline to malignant. Carcinoid tumors can occur in young and elderly women, and are sometimes seen in mature teratoma, struma ovarii, or mucinous cystadenoma as a nodule or tumor. Strumal carcinoid and mucinous carcinoid present as special types of carcinoid tumors of the ovary.

Case report : This report describes a 56-year-old woman who presented with a large pelvic mass on abdominal ultrasonography during a medical examination. The diameter of the pelvic tumor was approximately 11 cm and was suspected to be ovarian cancer. The values of CA125 and CEA were above their reference intervals on preoperative examination. Abdominal total hysterectomy and bilateral salpingo-oophorectomy were performed. Intraoperative frozen-section histopathology suggested a diagnosis of mucinous adenocarcinoma ; therefore, partial omentectomy and pelvic lymphadenectomy were also performed. Permanent-section histopathology led to a final diagnosis of strumal carcinoid of the ovary, stage IA (FIGO 2014). Six years post-operation, the patient had no sign of recurrence.

Key words : ovarian strumal carcinoid, clinical diagnosis, histopathological feature, treatment, case report

Introduction

Strumal carcinoid of the ovary is a malignant tumor that is categorized as a germ cell tumor. The histopathological character is a mixture of normal thyroid tissue and carcinoid.

Struma ovarii is a rare tumor comprising about 1% of all ovarian tumors¹⁾. Carcinoid tumor of the ovary is even more rare. The frequency of ovarian strumal carcinoid is thought to be approximately 0.5-1.7% of all carcinoid tumors¹⁾. Typical symptoms of carcinoid syndrome are seldom seen in patients with strumal carcinoid. Instead, patients may experience symptoms caused by tumor size, such as abdominal distension, and the tumor is

sometimes found incidentally.

Ovarian carcinoid tumor cell populations can grow in four histological patterns : insular, trabecular, follicular, and mucinous. Most malignant cases present as mucinous or insular carcinoids. Surgical treatment is an effective therapy, but it may be difficult to determine appropriate surgical care based on intraoperative rapid histopathology alone. Generally, strumal carcinoid is related to a borderline malignant tumor, but sometimes metastases are seen in patients with strumal carcinoids.

Case Report

This report describes the case of a 56-year-old

Corresponding author : Masaru Kanasugi, PhD E-mail : kanasugi@outlook.com

©2023 The Fukushima Society of Medical Science. This article is licensed under a Creative Commons [Attribution-NonCommercial-ShareAlike 4.0 International] license.
<https://creativecommons.org/licenses/by-nc-sa/4.0/>

gravida 4, para 3 woman with no notable medical or family history. The patient had hypertension and hyperlipidemia, conditions for which amlodipine, rosuvastatin, and esomeprazole were taken internally. An asymptomatic pelvic tumor was detected by chance during the abdominal ultrasound of a general medical examination at another internal medicine hospital. For this reason, the patient was referred to the hospital's department of obstetrics and gynecology for further evaluation. Vaginal ultrasonography revealed a large pelvic mass approximately 11 cm in size. It was diagnosed as an ovarian tumor or a degenerated uterine myoma. The patient was subsequently referred to the department of obstetrics and gynecology at our hospital for more detailed examination and medical treatment.

A huge type IV pelvic tumor (as classified by The Japan Society of Ultrasonics in Medicine) measuring 104×118×116 mm was observed by ultrasonography at our hospital. Tumor markers were elevated, with CA125 at 86.1 IU/mL and CEA at 34.7 IU/mL. No apparent metastases were observed on contrast CT (Fig. 1A). MRI identified a suspected right ovarian tumor (Fig. 1B).

Endoscopy was performed preoperatively, and showed no obvious lesions in the lower digestive tract. Thereafter, surgical treatment was performed based on the diagnosis of suspected ovarian cancer. Ascites cytology was performed because there was a small amount of ascites. In addition, rapid histopathological examination was performed during the operation, with a provisional diagnosis of mucinous adenocarcinoma. The findings were as follows: The tumor was solid and cystic. The cysts were filled with mucus. Diffuse proliferation of the ducts of glands was present in the solid part of the tumor.

In accordance with these findings, the operative

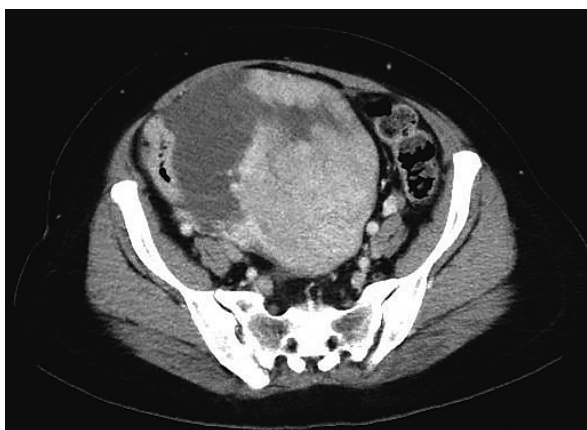

Fig. 1A CT (contrast CT)

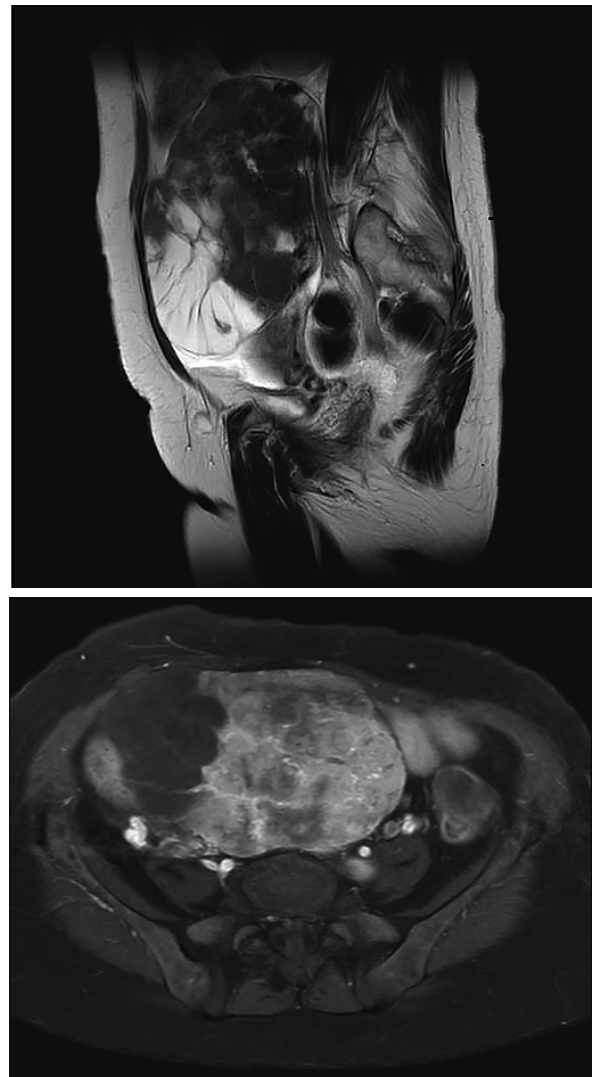


Fig 1B. MRI (upper : T2, lower : T1 with Gd enhancement)

method employed was abdominal total hysterectomy, bilateral salpingo-oophorectomy, partial omentectomy, and pelvic lymphadenectomy. The operating time was 2 h 26 min, and intraoperative bleeding was 171 g. No intraoperative rupture of the tumor was observed. No clear peritoneal lesions were found by visual inspection or palpation. Intra-abdominal adhesions were not observed, including around the tumor. The solid tumor's diameter was about 15 cm, including its partially cystic section (Fig. 2).

The postoperative course was good, and the patient was discharged from the hospital without complications on her 9th postoperative day. Pathological findings showed a mixture of cord-like, island-like, and tubular structures, as well as follicular structures, including colloids (Fig. 3A, B, and C). The results of immunohistochemical staining

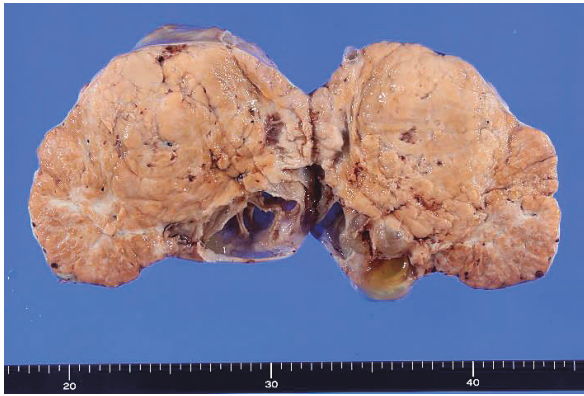

Fig. 2 Macroscopic finding of right ovary

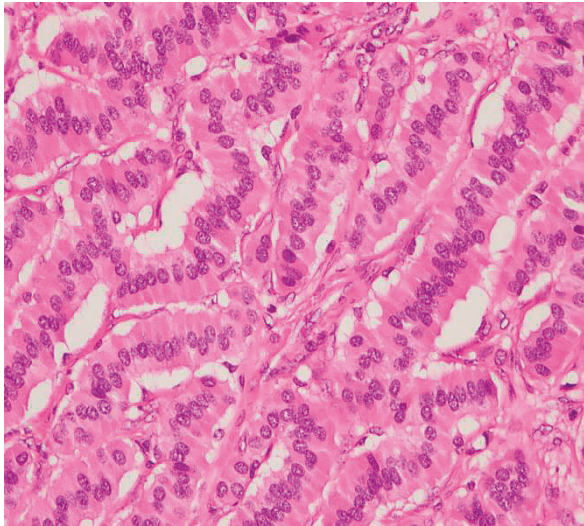


Fig. 3A Cord-like structure in strumal carcinoid (HE, ×400)

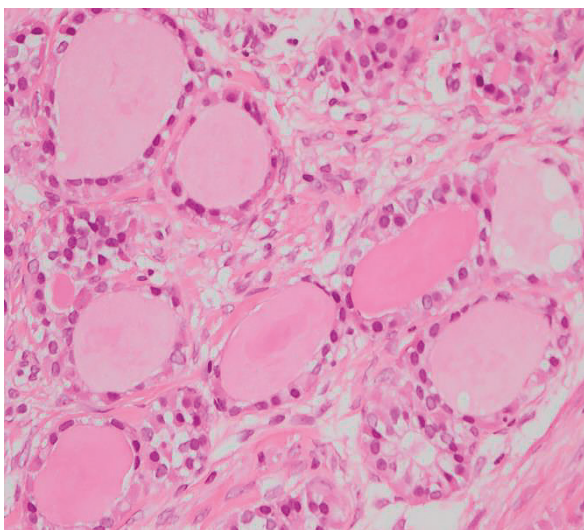


Fig. 3B Colloids in strumal carcinoid (HE, ×400)

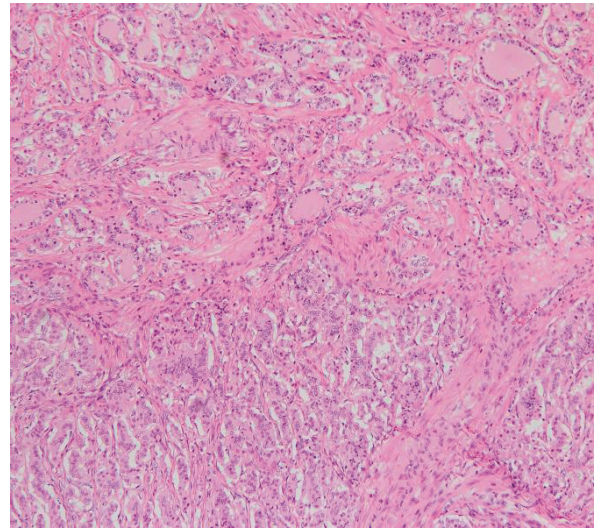


Fig. 3C Mixed structures of colloids and cord-like lesions in strumal carcinoid (HE, ×200)

showed that the structure showing cord and insular sequences was positive for CD56 (Fig. 4A), chromogranin A (Fig. 4B), and synaptophysin (Fig. 4C), whereas the follicular structure was positive for TTF1 (Fig. 4D). The result of histopathological examination was a diagnosis of strumal carcinoid. Lymph node metastasis was negative, and no abnormal findings were observed in the omentum, uterus, or left adnexa. In addition, ascites cytology was negative. Based on these results, the patient was diagnosed with ovarian strumal carcinoid, stage IA, pT1aN0M0. There was no sign of recurrence at 6 years post-operation. Moreover, the patient's tumor markers remained under the threshold of concern.

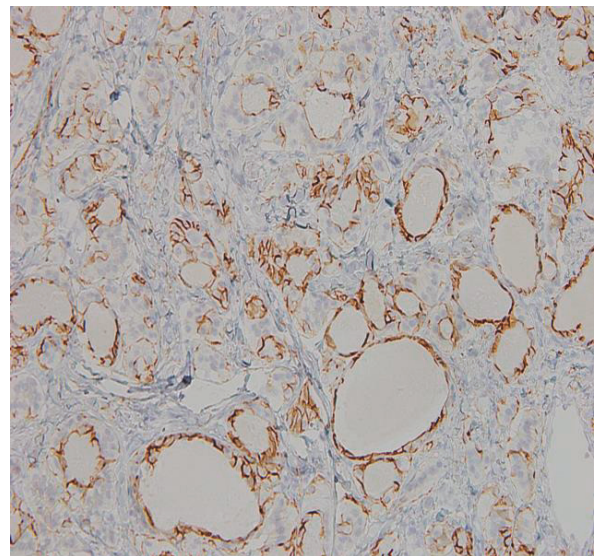


Fig. 4A Insular sequence stained with CD56 × 200

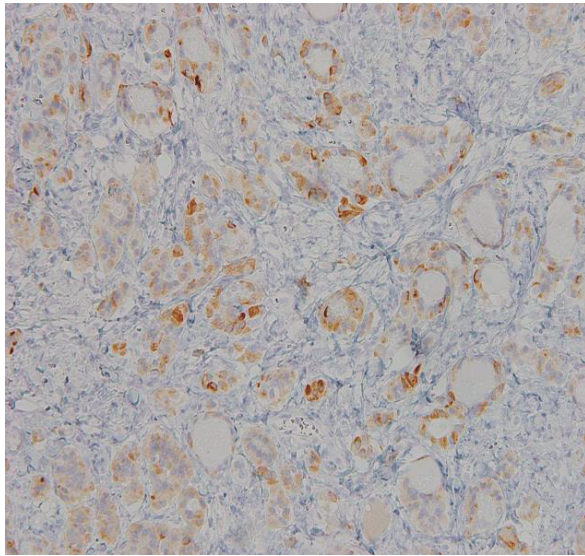


Fig. 4B Cord like structure stained with chromogranin A ($\times 200$)

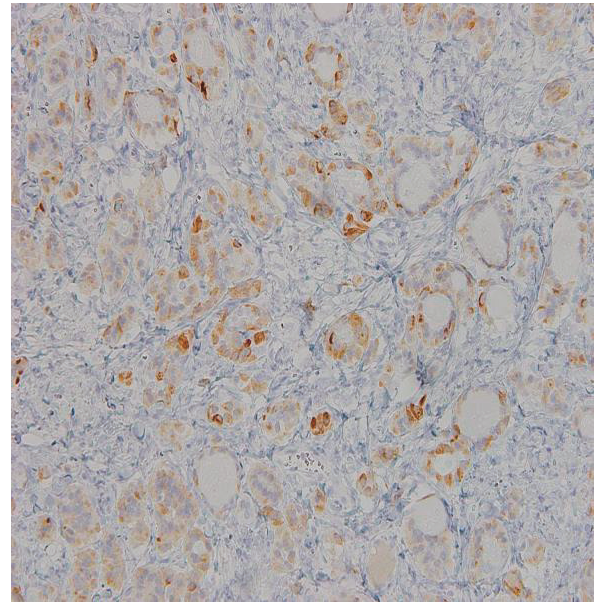


Fig. 4D Colloid stained with TTF 1 ($\times 200$)

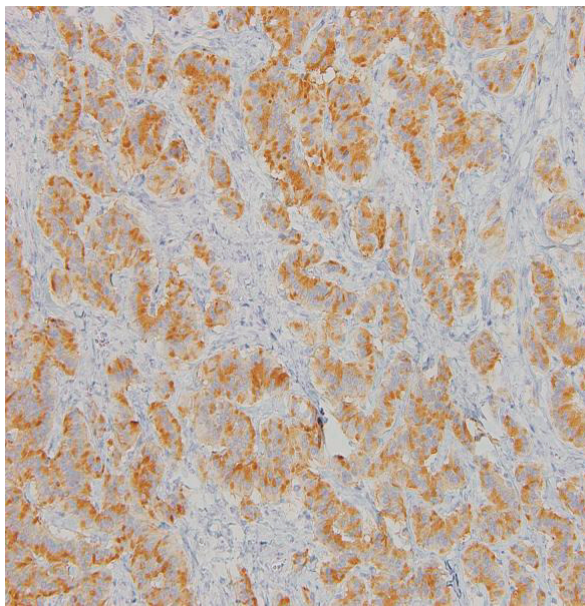


Fig. 4C Cord and insular sequence stained with synaptophysin ($\times 200$)

Discussion

Carcinoids are tumors that are similar to highly differentiated neuroendocrine tumors, Grade 1. Clinically, carcinoids can be found in young and elderly women, and are mainly unilateral¹⁾. In addition, they may be seen as nodules or masses in mature teratoma, ovarian struma, and more rarely in mucinous cystadenoma¹⁾. In peptide YY-producing tumors, carcinoid may be accompanied by advanced constipation²⁾.

Carcinoid tumors are classified in the WHO

classification (2020) as “monodermal teratomas and somatic-type tumours arising from dermoid cyst.” The International Classification of Diseases for Oncology includes tumors of borderline malignancy or malignancy, with borderline malignancies/low-grade tumors in the classification of ovarian tumors based on clinical treatment³⁾.

Ovarian strumal carcinoid was first described by Scully in 1970⁴⁾. It is an extremely rare tumor, with a frequency of occurrence reported to be less than 0.1% of all ovarian malignant tumors⁵⁾. Moreover, 0.1% of all ovarian malignant tumors are ovarian carcinoids⁶⁾, with strumal carcinoids making up 21.9% of ovarian carcinoids⁷⁾. Strumal carcinoid is a tumor peculiar to the ovary, and includes both the struma and carcinoid components as mixed histological features. In the carcinoid component, the cord sequence is often shown. Intermediate migratory cells of thyroid follicular epithelium and carcinoid tumors are also rough.

In the clinical presentation of carcinoids, symptoms such as facial flushing, abdominal bloating, diarrhea, and heart disease may be observed. Tumors produce and secrete serotonin, histamine, substance P, tachykinin, bradykinin, kallikrein, and prostaglandins, among others, and may result in carcinoid syndrome⁸⁾. However, strumal carcinoid is often discovered through lower abdominal examination, and hardly exhibits typical symptoms or laboratory findings. Regarding endocrine function, according to Robboy and Scully, an increase of steroid hormone was observed in approximately 8% of cases⁹⁾. Ashton (1995) observed hyperinsulinemia,

hypoglycemia, and pigmentation in cases of strumal carcinoid¹⁰⁾. The case reported herein had no symptoms ; however, the patient's tumor markers (CEA and CA125) were elevated.

Pathological examination is the most effective method for precise diagnosis, and the carcinoid component is generally positive for chromogranin A, galectin-3, NSE, and synaptophysin¹¹⁾. Surgical resection is the main option for treatment. If fertility conservation is desirable, unilateral salpingo-oophorectomy is performed ; for patients beyond reproductive age, total hysterectomy and bilateral salpingo-oophorectomy should be performed⁶⁾. Strumal carcinoid may also be accompanied by malignant components when it occurs in connection with a dermoid cyst. Papillary or follicular cancer may be observed in the strumal component. In that case, chemotherapy or radiotherapy should be performed in addition to surgical treatment. Thus, lymphadenectomy may need to be considered for staging and radical treatment, as with other ovarian cancers.

In the present case, subjective symptoms were absent, and the tumor was discovered incidentally during a medical examination. As surgical treatment, total hysterectomy, bilateral salpingo-oophorectomy, partial omentectomy, and pelvic lymph node dissection were performed. The diagnosis of strumal carcinoid was confirmed by permanent-section histopathology, which differed from the intraoperative frozen-section histopathological examination.

Here, we report an extremely rare case of ovarian strumal carcinoid. The patient was successfully treated with surgery, and no recurrent symptoms have been observed since.

References

1. WHO Classification of Tumours Editorial Board. WHO Classification of Tumours · 5th Edition Female Genital Tumours, 132-135, 2020.
2. MO Toyama T, Katayama Y, Watanabe H, *et al.* Functioning ovarian carcinoids induce severe con-

stipation. *Cancer*, **70** : 513-518, 1992.

3. WHO Classification of Tumours Editorial Board. WHO Classification of Tumours · 5th Edition Female Genital Tumours, 134-135, 2020.
4. Scully RE. Recent progress in ovarian cancer. *Hum Pathol*, **1**(1) : 73-98, 1970.
5. Wu L, Wang Z, Dai S, *et al.* Primary strumal carcinoid tumor of the ovary : a case report and literature review. *Int. J Clin Exp Pathol*, **9** : 2409-2413, 2016.
6. Lenicek T, Tomas D, Soljagic-Vranes H, *et al.* Strumal carcinoid of the ovary : report of two cases. *Acta Clin Croat*, **51** : 649-635, 2012. PMID : 23540174
7. Davis KP, Hartmann LK, Keeny GL, Shapiro H : Primary ovarian carcinoid tumors. *Gynecol Oncol*, **61** : 259-265, 1996.
8. Sharma R, Biswas B, Puri Wahal S, Sharma N, Kaushal N. Primary ovarian carcinoid in mature cystic teratoma : A rare entity. *Clinical Cancer Investigation Journal*, **3** : 80-82, 2014.
9. Robboy SJ, Scully RE. Strumal carcinoid of the ovary-an analysis of 50 cases of a distinctive tumor composed thyroid-tissue and carcinoid. *Cancer*, **46** : 2019-2034, 1980.
10. Ashton MA. Strumal carcinoid of the ovary associated with hyperinsulinemic hypoglycemia and cutaneous melanosis. *Histopathology*, **27** : 463-467, 1995.
11. Takatori E, Shoji T, Miura J, *et al.* Case of Peptide-YY-producing stromal carcinoid of the ovary : a case report and review. *J Obstet Gynecol Res*, **38** : 1266-1270, 2012.

Conflict of interest disclosure

The authors have no conflicts of interest directly relevant to the content of this article.

Patient consent

Informed consent for publication of this work was obtained from the patient on September 15, 2020.