



# Short-term outcomes of neoadjuvant chemotherapy with capecitabine plus oxaliplatin for patients with locally advanced rectal cancer followed by total or tumor-specific mesorectal excision with or without lateral pelvic lymph node dissection

メタデータ	<p>言語: English</p> <p>出版者: The Fukushima Society of Medical Science</p> <p>公開日: 2022-08-23</p> <p>キーワード (Ja):</p> <p>キーワード (En): Rectal cancer, neoadjuvant chemotherapy, CAPOX, oxaliplatin, capecitabine</p> <p>作成者: Sakamoto, Wataru, Kanke, Yasuyuki, Onozawa, Hisashi, Okayama, Hirokazu, Endo, Hisahito, Fujita, Shotaro, Saito, Motonobu, Saze, Zenichiro, Momma, Tomoyuki, Kono, Koji</p> <p>メールアドレス:</p> <p>所属:</p>
URL	<p><a href="https://fmu.repo.nii.ac.jp/records/2002048">https://fmu.repo.nii.ac.jp/records/2002048</a></p>



## Short-term outcomes of neoadjuvant chemotherapy with capecitabine plus oxaliplatin for patients with locally advanced rectal cancer followed by total or tumor-specific mesorectal excision with or without lateral pelvic lymph node dissection

Wataru Sakamoto, Yasuyuki Kanke, Hisashi Onozawa, Hirokazu Okayama, Hisahito Endo, Shotaro Fujita, Motonobu Saito, Zenichiro Saze, Tomoyuki Momma and Koji Kono

*Department of Gastrointestinal Tract Surgery, School of Medicine, Fukushima Medical University, Fukushima City, Fukushima, Japan*

(Received February 1, 2022, accepted May 18, 2022)

### Abstract

**Background :** The standard strategy in Japan for locally advanced rectal cancer is total mesorectal excision plus adjuvant chemotherapy. However, large tumors significantly restrict pelvic manipulation of the distal side of the tumor during surgery ; therefore, from an oncological point of view, it is better to shrink the tumor as much as possible preoperatively to optimize the circumferential resection margin. In recent years, advances in systemic chemotherapy have significantly improved the tumor reduction effect, enabling such drug therapy prior to surgery for locally advanced rectal cancer. We herein retrospectively evaluated the clinical, short-term outcomes of patients treated by neoadjuvant chemotherapy (NAC) using capecitabine and oxaliplatin (CAPOX), focusing on overall safety as well as clinical and pathological staging responses to NAC.

**Methods :** We applied the preoperative chemotherapy protocol to T3-4, any N, M0 or M1a (with resectable metastases) (UICC 8<sup>th</sup>) Ra/Rb rectal cancers. The chemotherapy regimen consisted of four cycles of CAPOX. After NAC, curative intent surgery with total mesorectal excision/tumor-specific mesorectal excision with/without metastasectomy was performed. Adverse effects (AEs) and compliance with NAC, surgical complications, clinical and pathological staging were evaluated. All patients undergoing the protocol between January 2017 and June 2021 at Fukushima Medical University were enrolled.

**Results :** Twenty cases were enrolled. No severe AEs were observed either preoperatively or perioperatively. Preoperative assessment of NAC showed no cases of progressive disease (PD). Radical resection was achieved in all cases. Histological therapeutic grading after NAC revealed one grade 3, four grade 2, three grade 1b, eleven grade 1a and one grade 0 among all cases.

**Conclusion :** This study suggests that NAC for locally advanced rectal cancer is likely to be acceptable because there were no severe AEs pre- or perioperatively, radical resection was achieved in all cases, and there were no cases of PD.

**Key words :** Rectal cancer, neoadjuvant chemotherapy, CAPOX, oxaliplatin, capecitabine

### Introduction

Rectal cancer (RC) is one of the main causes of

cancer-related mortality worldwide, accounting for approximately 860,000 deaths annually<sup>1)</sup>. In Japan, the standard treatment for locally advanced RC with-

Corresponding author : Wataru Sakamoto E-mail : ws1024@fmu.ac.jp

©2022 The Fukushima Society of Medical Science. This article is licensed under a Creative Commons [Attribution-NonCommercial-ShareAlike 4.0 International] license.  
<https://creativecommons.org/licenses/by-nc-sa/4.0/>

out distant metastasis has been total mesorectal excision (TME)<sup>2)</sup>, plus postoperative adjuvant chemotherapy without preoperative treatment. On the other hand, preoperative CRT followed by surgery for rectal cancer has been the standard treatment in the Western countries for a long time, a position supported by the Swedish Rectal Cancer Trial, which showed that preoperative short course radiotherapy (SCRT) was more effective than surgery alone<sup>3)</sup> and clinical trial data from Sauer *et al.* showing fewer adverse events and better local control (LC) in the preoperative chemoradiotherapy group compared to the postoperative group CRT group<sup>4)</sup>. However, there is still debate over improvement in overall survival (OS) with the addition of SCRT or CRT compared to surgery alone<sup>4-7)</sup>.

In recent years, advances in systemic chemotherapy for colorectal cancer have significantly improved local tumor reduction as well as overall survival. Preoperative reduction of tumor size may increase the rate of R0 resection and the likelihood of securing an adequate circumferential resection margin (CRM). In addition, compliance with NAC may be better than with conventional adjuvant chemotherapy<sup>8)</sup>. With this in mind, the concept of using chemotherapy as a preoperative treatment could be considered an acceptable strategy for poor risk RC treatment in Japan, where preoperative treatment has not been commonly used. However, in Western countries, preoperative (neoadjuvant) chemotherapy (NAC) without radiotherapy (RT)/CRT for poor-risk RC is considered unacceptable.

Combinations of capecitabine and oxaliplatin, known as the CAPOX regimen, have been established for the treatment of unresectable/metastatic RC and are used as adjuvant chemotherapy for colorectal cancer. According to a previous report, the CAPOX response rate for metastatic RC was approximately 47.0% and progression-free survival

was 8.0 months<sup>9)</sup>. CAPOX is one of the main first-line regimens for advanced/recurrent rectal cancer and is valued as a port-less regimen<sup>10)</sup>, thus it is suitable for NAC with a limited treatment period. The main adverse event (AE) is peripheral neuropathy, which may persist after treatment, leading to questions about the acceptability for NAC. Therefore, NAC with CAPOX for locally advanced RC in Japan may be a potentially therapeutic option to improve OS and the LC of locally advanced RC. However, there are two unresolved issues with NAC: 1) The possibility of the tumor becoming unresectable due to tumor growth during NAC, and 2) The possibility that surgery cannot be performed safely in time due to NAC-associated AEs. In order to address these issues, we retrospectively reviewed the consecutive NAC cases performed at our hospital, with the aim of examining the safety and short-term results of NAC for locally advanced RC.

## Methods

### *Patients/regimen/surgery*

This study was a retrospective, observational study. We applied the NAC protocol for T3-4, and any M0,1a (considered resectable metastasis) (UICC 8<sup>th</sup>), Ra/Rb rectal cancer. A schematic of the protocol is shown in Figure 1. The chemotherapy regimen comprised capecitabine (825 mg/m<sup>2</sup>, day 1-14, every 21 days) plus oxaliplatin (130 mg/m<sup>2</sup>, day 1, every 21 days), without using a central venous port system. At first, TNM staging was evaluated with colonoscopy (CS), enhanced computed tomography (CE-CT), and positron emission tomography-magnetic resonance imaging (PET-MRI). To avoid the tumor becoming inoperable due to its growth despite chemotherapy, a CE-CT was taken and evaluated af-

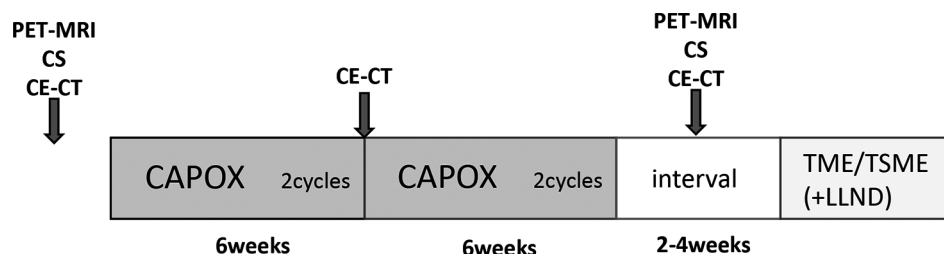


Fig. 1. A schematic of the study protocol

PET-MRI: positron emission tomography-magnetic resonance imaging, CS: colonoscopy, CE-CT: contrast enhanced computed tomography, CAPOX: chemotherapy regimen consists of oral capecitabine and infused oxaliplatin, TME: total mesorectal excision, TSME: tumor specific mesorectal excision, LLND: lateral lymph node dissection

ter 2 cycles of NAC. If the CE-CT showed progressive disease (PD), the protocol required immediate curative surgery. After 4 cycles of NAC, TNM stage was evaluated again to confirm the clinical efficacy of NAC in the same manner, and curative intent surgery with total mesorectal excision (TME)/tumor-specific mesorectal excision (TSME), and metastasectomy, if required, was performed. Using the resected specimens, the histological grades of NAC cases were evaluated.

All patients undergoing the protocol between January 2017 and June 2021 at Fukushima Medical University Hospital were enrolled the study. This study was approved (#30148) by the Ethics Committee of Fukushima Medical University, which is guided by local policy, national law, and the World Medical Association Declaration of Helsinki.

### Outcome Measurement

NAC safety was evaluated by the following factors: AE, completion rate of NAC, dose down of NAC, and post-operative complications such as anastomotic leakage (AL), surgical site infection (SSI), and neurogenic bladder. The efficacy of NAC was evaluated: 1) clinically by CS, CE-CT and PET-MRI by the degree of T-factor (UICC 8<sup>th</sup>) downstaging, TNM (UICC 8<sup>th</sup>) downstaging, and 2) pathologically by evaluating regression of the primary lesion in accordance with the Japanese Classification of Colorectal Carcinoma<sup>11)</sup> grading of pathological therapeutic effect (grade 0: no necrosis, grade 1a: necrotic area is less than 30% of the tumor, grade 1b: 30–70%, grade 2: 70% and more, grade 3: pathological complete response (pCR)) and R0 resection rate.

### Statistical Analysis

A Kaplan-Meier curve was created and the estimated average relapse free survival time calculated by using SPSS Statistics version 24 (IBM, Armonk, U.S.A.).

## Results

### Clinical and Pathological Features

Twenty patients were consecutively enrolled the study. The baseline characteristics, clinical and pathological staging details of the study cohort are shown in Table 1. The average age of the patients was 61.5 years, with 15 males and 5 females enrolled the study. The main tumor locations were RS: 2, Ra: 9, and Rb: 9, respectively. The clinical stag-

Table 1. Patient demographics

Age	61.5±13.7	
Sex	Male	15
	Female	5
Location	RS	2
	Ra	9
	Rb	9
Surgical procedure	L-Hartmann	1
	L-LAR	11
	L-ISR	1
	L-APR	4
	L-IPAA	1
	R-LAR	1
	R-APR	1
Diverting ileostomy	w/	7
	w/o	13
mGPS	A	14
	B	6
	C	0
cT	3	10
	4a	9
	4b	1
cN	0	2
	1a	3
	1b	4
	2a	5
	2b	2
	3	4
cStage	IIa	2
	IIb	0
	IIIa	0
	IIIb	7
	IIIc	5
	IVa	6
NAC regimen	CAPOX	20
Adjuvant regimen	Capecitabine	3
	UFT/LV	1
	CAPOX	12
	FOLFIRI+Pmab	1
	FOLFIRI+Rmab	1
	No adjuvant	3
Observation period(median)	468 days	

※the patient had complicated familial adenomatous polyposis.

RS: recto-sigmoid colon, Ra: rectum above the peritoneal reflection, Rb: rectum below the peritoneal reflection, L-: laparoscopic, R-: robotic, LAR: low anterior resection, ISR: intersphincteric resection, IPAA: ileal pouch anal anastomosis, APR: abdominoperineal resection, mGPS: modified Glasgow prognostic score, NAC: neoadjuvant chemotherapy, LV: leucovorin, CAPOX: capecitabine plus oxaliplatin, FOLFIRI: 1-leucovorin, irinotecan and 5-FU, Pmab: panitumumab, Rmab: ramucirumab

TNM classification was based on UICC 8th edition.

ing was II A in 2 cases, III B in 7 cases, III C in 5 cases and IV A in 6 cases.

#### *Continuity, compliance, and adverse events from NAC*

Compliance and continuity with NAC are shown in Table 2. Eleven cases (55%) completed NAC without a dose reduction, while 9 cases (45%) needed their dose reduced. The reasons for dose reduction were myelosuppression in 6 cases, liver dysfunction in 2 cases and nausea/anorexia in one case. Two cases were unable to complete 4 cycles of NAC due to AEs. There were no cases of NAC non-completion due to progressive disease at midterm evaluation before starting the 3<sup>rd</sup> cycle of NAC. Post-operative complications occurred in 7 patients. One patient developed anastomotic leakage and recovered with conservative therapy without any surgery. The other post-operative complications were one patient with pyoderma gangrenosum, 2 deep surgical site infections (SSIs), 2 neurogenic bladders, and one ileus. There were no complications more than 3b as measured by the Clavien-Dindo classification.

#### *Clinical and pathological evaluation of NAC*

A summary of the clinical and pathological evaluation outcomes is shown in Table 3. For the clinical evaluation, 2 cCR, 4 PR, 4 non-CR/non-PD and

10 SD were observed. There were no patients with clinical PD among the 20 cases. Average reduction rate of cases with a measurable lesion was 27.9%.

In histological therapeutic grading of NAC, one grade 3, four grade 2, three grade 1b, eleven grade 1a and one grade 0 were observed.

#### *Oncological outcomes*

The median observation period after surgery in this study was 468 days. Recurrence was found in 2 patients: one with local recurrence and lung metastasis, and the other with lung metastasis only. There were no deaths during the observation period and the average relapse free survival (RFS) was 1152 days (Figure 2).

## Discussion

RC surgery is technically difficult due to the limited pelvic space, especially in male patients with a narrow pelvis, making operating extremely difficult on the distal side of a large tumor. Therefore, it is preferable to operate after the tumor size has been reduced as much as possible. However, although the addition of radiotherapy is effective for local control, it is currently recognized that neoadjuvant ra-

Table 2. The safety of neoadjuvant chemotherapy

<b>Completed without dose reduction</b>		<b>11</b>
<b>Dose reduction due to AEs</b>		<b>9</b>
	Neutropenia	2
	Thrombocytopenia	3
	Pancytopenia	1
	Liver dysfunction	2
	Nausea/anorexia	1
	(※Peripheral nerve dysfunction)	4
※Grade 1 only, not the reasons of dose reduction		
<b>Discontinuation of chemotherapy</b>	<b>Due to AE</b>	<b>2</b>
	<b>Due to PD</b>	<b>0</b>
	<b>Others</b>	<b>0</b>
<b>Post operative complication</b>		<b>7</b>
Clavien-Dindo classification		
Grade II	Anastomotic leakage	1
	Pyoderma gangrenosum	1
	Deep SSI	2
Grade IIIa	Neurogenic bladder	2
	Ileus	1

AE : adverse event, PD : progressive disease (based on RECIST ver.1.1),  
SSI : surgical site infection

Table 3. Clinical &amp; pathological evaluation of neoadjuvant chemotherapy

Clinical evaluation of chemotherapy efficacy		
	Case	Proportion (%)
CR	2	10
PR	4	20
non-PD/non-CR	4	20
SD	10	50
PD	0	0
Clinical down staging		
	Case	
T factor	Yes	4
	No	16
N factor	Yes	8
	No	12
cStage	Yes	7
	No	13
Average reduction rate (cases with a measurable lesion)		
27.90%		
Histological grading of NAC		
	Case	Proportion (%)
Grade 0	1	5
Grade 1a	11	55
Grade 1b	3	15
Grade 2	4	20
Grade 3	1	5

CR : complete response, PR : partial response, SD : stable disease, PD : progressive disease (based on RECIST ver.1.1),  
TNM classification is based on UICC 8<sup>th</sup> edition.

diotherapy increases the risk of treatment-related toxicities including urological, gastrointestinal, dermatological, and neurological complications in patients with lower RC<sup>12)</sup>. Moreover, local control equivalent to that of Western countries has been achieved with surgery plus adjuvant chemotherapy without preoperative CRT in Japan, suggesting that the addition of preoperative RT/CRT may be an overtreatment. Therefore, NAC is a potential option for patients with locally advanced RC to promote preoperative tumor shrinkage.

Recently, the results of the JCOG0212 study showed that although lateral lymph node dissection reduced the local recurrence rate, it did not prolong OS (12), suggesting that the key to improved prognosis is through the control of distant micro-metastases at the time of surgery. Even in Western countries, it is now considered that the control of

distant metastases by systemic therapy in addition to local control by CRT is the key to prolonging OS ; total neoadjuvant therapy (TNT), which is characterized by the addition of systemic chemotherapy before or after CRT, has been the focus of active investigation<sup>13,14)</sup>.

Since CAPOX is the one of the main regimens for adjuvant and unresectable/recurrent RC in the NCCN<sup>15)</sup>, ESMO<sup>16)</sup> and Japanese guidelines, the selection of a CAPOX regimen for NAC is reasonable<sup>17)</sup>. There are a few prospective studies reporting promising results of NAC using oxaliplatin<sup>18,19)</sup>. Okuyama *et al.* reported an 85.2% 3-year RFS rate and a 96.3% 4-year OS of cT3/4 and N+RC patients treated with NAC using CAPOX<sup>16)</sup>.

While NAC is expected to achieve systemic disease control, the possibility of non-resection due to disease progression during NAC and the increased possibility of perioperative complications related to NAC should be evaluated appropriately. Since our results show that there was no PD and all patients achieved R0 resection without severe perioperative complications, we consider that NAC with a CAPOX regime is acceptable and promising, in addition to the previous reports which have reported high radical resection rates (84–100%) and similar or less adverse event rates as compared to CRT<sup>19–23)</sup>.

To evaluate the efficacy of NAC focusing on RFS and OS, randomized control studies (RCTs) are needed to compare NAC plus TME/TSME and TME/TSME plus adjuvant chemotherapy with CAPOX. Unfortunately, as far as we know, there are no ongoing trials of this kind in Japan. In the U.S. and Canada, the ongoing PROSPECT trial is a multi-site two-group seamless phase II/III randomized trial, comparing standard neoadjuvant chemoradiation versus neoadjuvant chemotherapy for patients with locally advanced RC. The result of this study may provide answers to some of these questions.

This study has some limitations as it is a retrospective study with a very small sample size. The sample size is too small to confirm the efficacy of NAC with CAPOX or unequivocally support the safe use of NAC in this context.

From the initial 20 cases of NAC in our department, no severe perioperative complications due to NAC or non-resection due to PD have been observed to date. The long-term prognosis needs to be verified in future research.

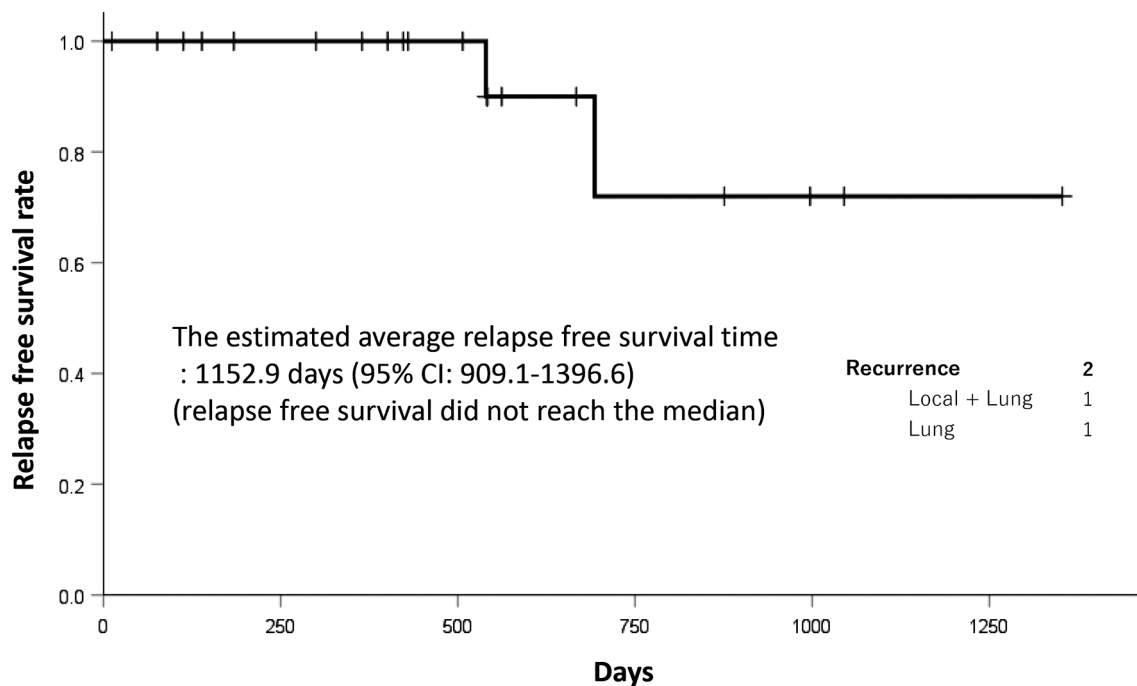


Fig. 2. Kaplan-Meier curve of relapse free survival

### Conflicts of interest

The authors declare that they have no conflicts of interest pertinent to this manuscript.

### References

1. Bray F, Ferlay J, Soerjomataram I, Siegel RL, Torre LA, Jemal A. Global cancer statistics 2018 : GLOBOCAN estimates of incidence and mortality worldwide for 36 cancers in 185 countries. *CA Cancer J Clin*, **68**(6) : 394-424, 2018.
2. Heald RJ. A new approach to rectal cancer. *Br J Hosp Med*, **22**(3) : 277-281, 1979.
3. Cedermark B, Dahlberg M, Glimelius B, Pahlman L, Rutqvist LE, Wilking N, *et al.* Improved survival with preoperative radiotherapy in resectable rectal cancer. *N Engl J Med*, **336**(14) : 980-987 1997.
4. Sauer R, Becker H, Hohenberger W, Rödel C, Wittekind C, Fietkau R, *et al.* Preoperative versus postoperative chemoradiotherapy for rectal cancer. *N Engl J Med*, **351**(17) : 1731-1740, 2004.
5. Peeters KC, Marijnen CA, Nagtegaal ID, Kranenburg EK, Putter H, Wiggers T, *et al.* The TME trial after a median follow-up of 6 years : increased local control but no survival benefit in irradiated patients with resectable rectal carcinoma. *Ann Surg*, **246**(5) : 693-701, 2007.
6. van Gijn W, Marijnen CA, Nagtegaal ID, Kranenburg EM, Putter H, Wiggers T, *et al.* Preoperative radiotherapy combined with total mesorectal excision for resectable rectal cancer : 12-year follow-up of the multicentre, randomised controlled TME trial. *Lancet Oncol*, **12**(6) : 575-582, 2011.
7. Kapiteijn E, Marijnen CA, Nagtegaal ID, Putter H, Steup WH, Wiggers T, *et al.* Preoperative radiotherapy combined with total mesorectal excision for resectable rectal cancer. *N Engl J Med*, **345**(9) : 638-646, 2001.
8. Fernandez-Martos C, Garcia-Albeniz X, Pericay C, Maurel J, Aparicio J, Montagut C, *et al.* Chemoradiation, surgery and adjuvant chemotherapy versus induction chemotherapy followed by chemoradiation and surgery : long-term results of the Spanish GCR-3 phase II randomized trial<sup>†</sup>. *Ann Oncol*, **26**(8) : 1722-1728, 2015.
9. Cassidy J, Clarke S, Díaz-Rubio E, Scheithauer W, Figure A, Wong R, *et al.* Randomized phase III study of capecitabine plus oxaliplatin compared with fluorouracil/folinic acid plus oxaliplatin as first-line therapy for metastatic colorectal cancer. *J Clin Oncol*, **26**(12) : 2006-2012, 2008.
10. Cassidy J, Clarke S, Díaz-Rubio E, Scheithauer W, Figure A, Wong R, *et al.* XELOX vs FOLFOX-4 as first-line therapy for metastatic colorectal cancer : NO16966 updated results. *Br J Cancer*, **105**(1) : 58-64, 2011.
11. Rectum. JSfCotCa. Japanese Classification of Colorectal Carcinoma, 2nd edition. Tokyo, Japan : Kanehara ; 2009.
12. Loos M, Quentmeier P, Schuster T, Nitsche U, Gertler R, Keerl A, *et al.* Effect of preoperative radio (chemo) therapy on long-term functional out-

- come in rectal cancer patients : a systematic review and meta-analysis. *Ann Surg Oncol*, **20**(6) : 1816-1828, 2013.
13. Cercek A, Goodman KA, Hajj C, Weisberger E, Segal NH, Reidy-Lagunes DL, *et al.* Neoadjuvant chemotherapy first, followed by chemoradiation and then surgery, in the management of locally advanced rectal cancer. *J Natl Compr Canc Netw*, **12**(4) : 513-519, 2014.
  14. Goodman KA. Total neoadjuvant therapy for rectal cancer. *Cancer Radiother*, **22**(5) : 459-465, 2018.
  15. Benson AB, Venook AP, Al-Hawary MM, Arain MA, Chen YJ, Ciombor KK, *et al.* NCCN Guidelines Insights : Rectal Cancer, Version 6.2020. *J Natl Compr Canc Netw*, **18**(7) : 806-815, 2020.
  16. Glynne-Jones R, Wyrwicz L, Tiret E, Brown G, Rödel C, Cervantes A, *et al.* Rectal cancer : ESMO Clinical Practice Guidelines for diagnosis, treatment and follow-up. *Ann Oncol*, **29** (Suppl 4) : iv22-iv40, 2018.
  17. Hata T, Takahashi H, Sakai D, Haraguchi N, Nishimura J, Kudo T, *et al.* Neoadjuvant CapeOx therapy followed by sphincter-preserving surgery for lower rectal cancer. *Surg Today*, **47**(11) : 1372-1377, 2017.
  18. Okuyama T, Sameshima S, Takeshita E, Yoshioka R, Yamagata Y, Ono Y, *et al.* Therapeutic effects of oxaliplatin-based neoadjuvant chemotherapy and chemoradiotherapy in patients with locally advanced rectal cancer : a single-center, retrospective cohort study. *World J Surg Oncol*, **16**(1) : 105, 2018.
  19. Miwa K, Oki E, Enomoto M, Ihara K, Ando K, Fujita F, *et al.* Randomized phase II study comparing the efficacy and safety of SOX versus mFOLFOX6 as neoadjuvant chemotherapy without radiotherapy for locally advanced rectal cancer (KSCC1301). *BMC Cancer*, **21**(1) : 23, 2021.
  20. Matsumoto T, Hasegawa S, Zaima M, Inoue N, Sakai Y. Outcomes of Neoadjuvant Chemotherapy without Radiation for Rectal Cancer. *Dig Surg*, **32**(4) : 275-283, 2015.
  21. Hasegawa J, Nishimura J, Mizushima T, Miyake Y, Kim HM, Takemoto H, *et al.* Neoadjuvant capecitabine and oxaliplatin (XELOX) combined with bevacizumab for high-risk localized rectal cancer. *Cancer Chemother Pharmacol*, **73**(5) : 1079-1087, 2014.
  22. Schrag D, Weiser MR, Goodman KA, Gonen M, Hollywood E, Cercek A, *et al.* Neoadjuvant chemotherapy without routine use of radiation therapy for patients with locally advanced rectal cancer : a pilot trial. *J Clin Oncol*, **32**(6) : 513-518, 2014.
  23. Uehara K, Hiramatsu K, Maeda A, Sakamoto E, Inoue M, Kobayashi S, *et al.* Neoadjuvant oxaliplatin and capecitabine and bevacizumab without radiotherapy for poor-risk rectal cancer : N-SOG 03 Phase II trial. *Jpn J Clin Oncol*, **43**(10) : 964-971, 2013.