



# Spinal cord stimulation for the treatment of pain and toe ulceration associated with systemic sclerosis: a case report

メタデータ	<p>言語: English</p> <p>出版者: The Fukushima Society of Medical Science</p> <p>公開日: 2022-04-15</p> <p>キーワード (Ja):</p> <p>キーワード (En): spinal cord stimulation, systemic sclerosis, Raynaud' s phenomenon, pain control, ulcer, Aged, 80 and over, Female, Humans, Microcirculation, Pain, Raynaud Disease, Scleroderma, Systemic, Spinal Cord Stimulation, Toes, Ulcer</p> <p>作成者: Ito, Hiroyuki, Tanei, Takafumi, Sugawara, Kyoko, Sando, Yu, Hori, Naohiro</p> <p>メールアドレス:</p> <p>所属:</p>
URL	<p><a href="https://fmu.repo.nii.ac.jp/records/2002040">https://fmu.repo.nii.ac.jp/records/2002040</a></p>

[Case report]



## Spinal cord stimulation for the treatment of pain and toe ulceration associated with systemic sclerosis : a case report

Hiroyuki Ito<sup>1)</sup>, Takafumi Tanei<sup>2)</sup>, Kyoko Sugawara<sup>3)</sup>, Yu Sando<sup>3)</sup> and Naohiro Hori<sup>1)</sup>

<sup>1)</sup>Department of Plastic and Reconstructive Surgery, Komaki City Hospital, Komaki, Japan, <sup>2)</sup>Department of Neurosurgery, Komaki City Hospital, Komaki, Japan, <sup>3)</sup>Department of Dermatology, Komaki City Hospital, Komaki, Japan

(Received December 8, 2021, accepted February 8, 2022)

### Abstract

Systemic sclerosis is a complex disease characterized by extensive fibrosis, microvascular alterations, and additional sequelae. Microvascular alterations can cause painful ulcers and necrosis ; however, conservative or surgical treatment is often challenging in terms of healing. The study aimed to describe a toe ulcer with systemic sclerosis and its' successful treatment with spinal cord stimulation. An 83-year-old woman, who was diagnosed with systemic sclerosis over the past decade, was distressed by a non-healing toe ulcer for an extended period of time. The patient underwent spinal cord stimulation treatment with the expectation of pain relief and an improvement in microcirculatory insufficiency. Her pain scales and microcirculation improved, and the toe ulcer healed. Furthermore, the frequency of Raynaud's symptoms was reduced, and the patient's pain decreased. There was no recurrence of the ulcer and she no longer needed a cane for walking.

**Key words :** spinal cord stimulation, systemic sclerosis, Raynaud's phenomenon, pain control, ulcer

### Introduction

Systemic sclerosis is a complex disease characterized by extensive fibrosis and microvascular alterations. In addition, the production of autoantibodies against a variety of cellular antigens is one of its' primary features. Prevalence of systemic sclerosis ranges from 50 to 300 cases per 1 million people, and the incidence ranges from 2.3 to 22.8 cases per 1 million people per year. Microvascular insufficiency can cause painful ulcers and necrosis ; however, conservative or surgical treatment is often unsuccessful in achieving healing<sup>1,2)</sup>.

Spinal cord stimulation (SCS) is thought to be useful for neuropathic pain and ischemic pain. It has been shown to be useful for the pain control of peripheral arterial disease as well as microcirculatory improvement. According to the SCS guidelines

prepared by the British Pain Society in 2009, SCS was classified as a beneficial intervention<sup>3)</sup>.

Few reports of SCS therapy for patients with systemic sclerosis have been published, and none of these followed pain transition and ulcer healing in detail. In this case, a patient with a history of systemic sclerosis had a skin ulcer after toe necrosis and an amputation caused by microcirculatory insufficiency. She was treated with SCS and as a result, her pain was well controlled and her wound healed.

### Case report

An 83-year-old woman, diagnosed a decade earlier with anti-centromere antibody-positive systemic sclerosis, was distressed by repeated dermatitis and Raynaud's phenomenon. The patient had an ulcer on the outside of her right fifth toe due to mi-

Corresponding author : Hiroyuki Ito, MD E-mail : itou.hiroyuki@med.nagoya-u.ac.jp

©2022 The Fukushima Society of Medical Science. This article is licensed under a Creative Commons [Attribution-NonCommercial-ShareAlike 4.0 International] license.  
<https://creativecommons.org/licenses/by-nc-sa/4.0/>

crocirculatory insufficiency. The ulcer would not heal and caused the patient chronic pain. To improve microcirculation, oral administration of salpogrelate and bosentan was initiated. The patient also received prednisolone 3 mg/day for sclerema. The right fifth toe was necrotic, and a transection of the proximal phalanx was performed. Subsequently, an ointment was prescribed with basic fibroblast growth factor, and maintenance debridement was performed. Two months after the transection of the fifth toe, both surgical and conservative treatment proved to be unsuccessful. Pain control with oral analgesics was insufficient, and her right lower extremity pain score was 8/10 (total range 0 to 10) using a visual analogue scale (VAS). She presented with evidence of pallor, hyperalgesia, dystrophic nails, and skin sclerosis in her lower extremity, with a 1 cm ulcer without tissue granulation in the proximal phalanx of her right fifth toe (Fig. 1). The pain in her foot interfered with treatment of the ulcer. Due to the lack of effective treatment, the patient underwent a SCS trial with an expectation of pain relief, microvascular circulation improvement, and healing of the toe ulcer.

The VAS, Short-form McGill Pain Questionnaire-2 (SF-MPQ-2) with a total range of 0 to 220, and the Pain Catastrophizing Scale (PCS) with a total range of 0 to 52 were used as preoperative and postoperative pain evaluation scales<sup>4,5)</sup>. Skin perfusion pressures (SPPs), evaluation of the status of microcirculatory function, were performed to evaluate blood flow. The SPP was less than 5 mmHg on her right dorsal side and 15 mmHg on the right plantar side. This indicated severe microcirculatory insufficiency. The SPP on her left dorsal side was 31 mmHg and on the left plantar side was 36 mmHg. Pain scales were VAS 8/10, SF-MPQ-2 48/220, and PCS 29/52 (Fig. 2).

The SCS trial was performed under local anesthesia. Since decreased microcirculation was observed in both lower limbs, we planned to introduce two electrodes into the epidural space where paresthesia could be induced in both lower limbs. Bilateral spinal cord stimulator leads (Vectoris Sure Scan MRI compact; Medtronic, Minneapolis, MN, USA) were placed in the posterior epidural space at the T10/11 level where the paresthesia of both lower limbs could be confirmed by intraoperative stimulation (Fig. 3). During the trial, the patient noticed a marked improvement in pain and an improvement in the color and temperature of both lower limbs. Therefore, an implantable pulse generator (IPG, Intellis; Medtronic) was placed 1 week after the

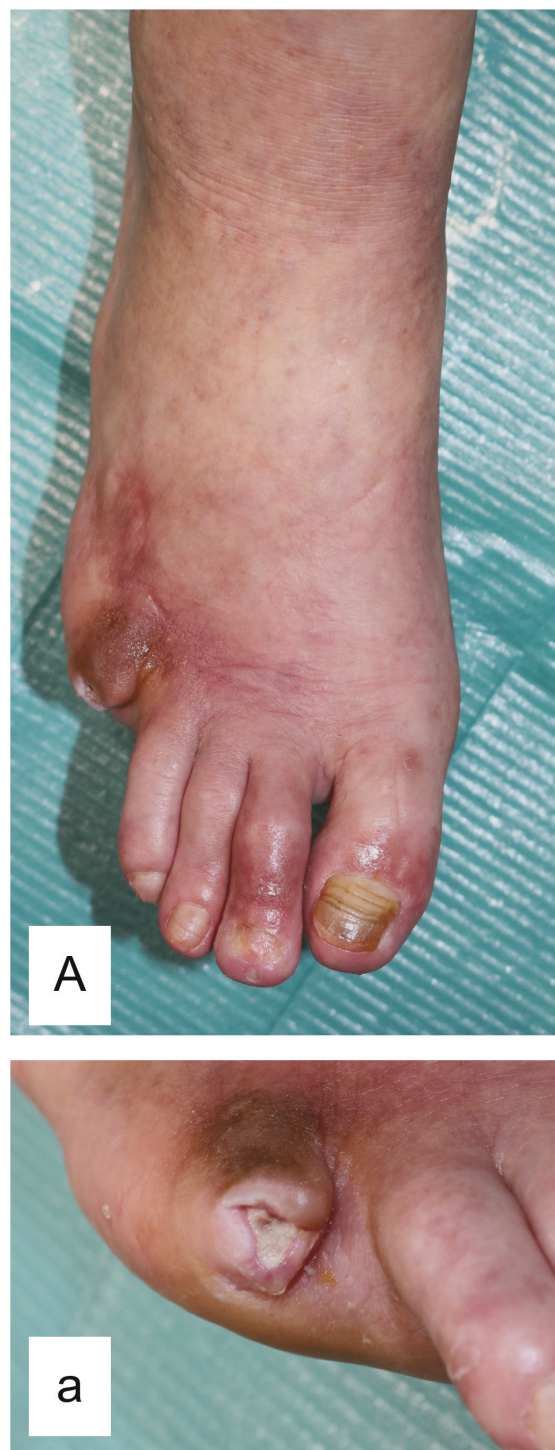

Fig. 1. The right foot ulcer prior to spinal cord stimulation.

A : Whole view of the right foot ; a : enlarged view of the ulcer. There was a 1 cm ulcer at the base of the right fifth phalanx. Necrotic tissue remained at the margin with no tissue granulation.

trial.

After IPG placement, the patient's pain was continuously relieved. The preoperative pain scale

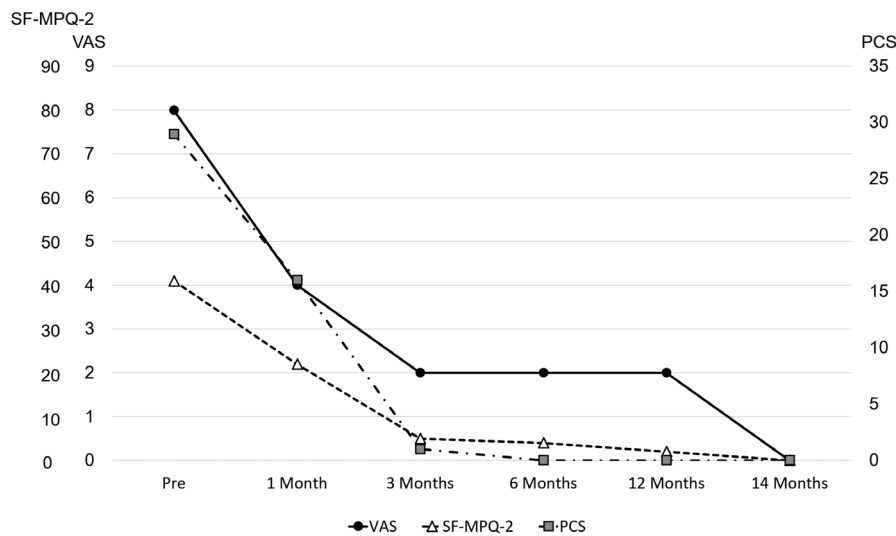


Fig. 2. Transposition of the pain scales.

The black circle represents the visual analogue scale (VAS), the white triangle represents the Short-Form McGill Pain Questionnaire-2 (SF-MPQ-2), and the gray square represents the pain catastrophizing scale (PCS). The pain nearly disappeared on all three scales at three months postoperatively, and no exacerbation was observed. At 14 months postoperative, all pain scales were zero.

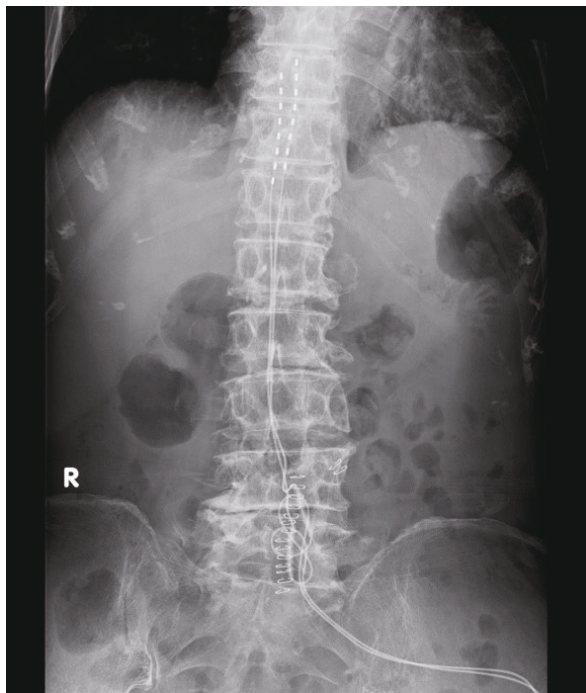


Fig. 3. Radiography of the spinal cord stimulator. Two electrodes were placed in the posterior epidural space at the T10/T11 level.

score halved 1 month after the operation, and the pain had nearly completely subsided 3 months after the operation. Fourteen months postoperatively, all three pain scale scores were 0 (Fig. 2). The patient's pain was greatly relieved, hence, she no longer required a cane for walking, and her gait distur-

bance improved. Her programming settings were a frequency of 90 Hz, pulse width of 450  $\mu$ s, and amplitude of approximately 3.0 milliamps with self-adjustment. Fourteen months postoperatively, the SPP on her right dorsal side improved to 33 mmHg, and her plantar side improved to 28 mmHg. The SPP on her left dorsal side improved to 51 mmHg, and her plantar side improved to 52 mmHg. Although there was no tissue granulation in the wound prior to the operation, the necrotic tissue reduced, and tissue granulation increased after the operation. The ulcer began to reduce in size and closed 12 months after the operation (Fig. 4). Raynaud's phenomenon did not occur during cold weather, and the ulcer healed 12 months after the operation. The patient's performance of daily activities greatly improved.

## Discussion

With systemic sclerosis, damage to the endothelial cells and basal layer of the blood vessels causes thickening of the intima, which impairs the small arteries and microcirculation. As the vascular damage progresses, the microvessels reduce in number leading to increased likelihood of delayed wound healing and tissue necrosis. Raynaud's phenomenon, such as that caused by cold stimuli, occurs in 50–90% of the patients. It can produce numbness and burning sensations that are distressing<sup>1,2)</sup>. Skin ulcers caused by systemic sclerosis are



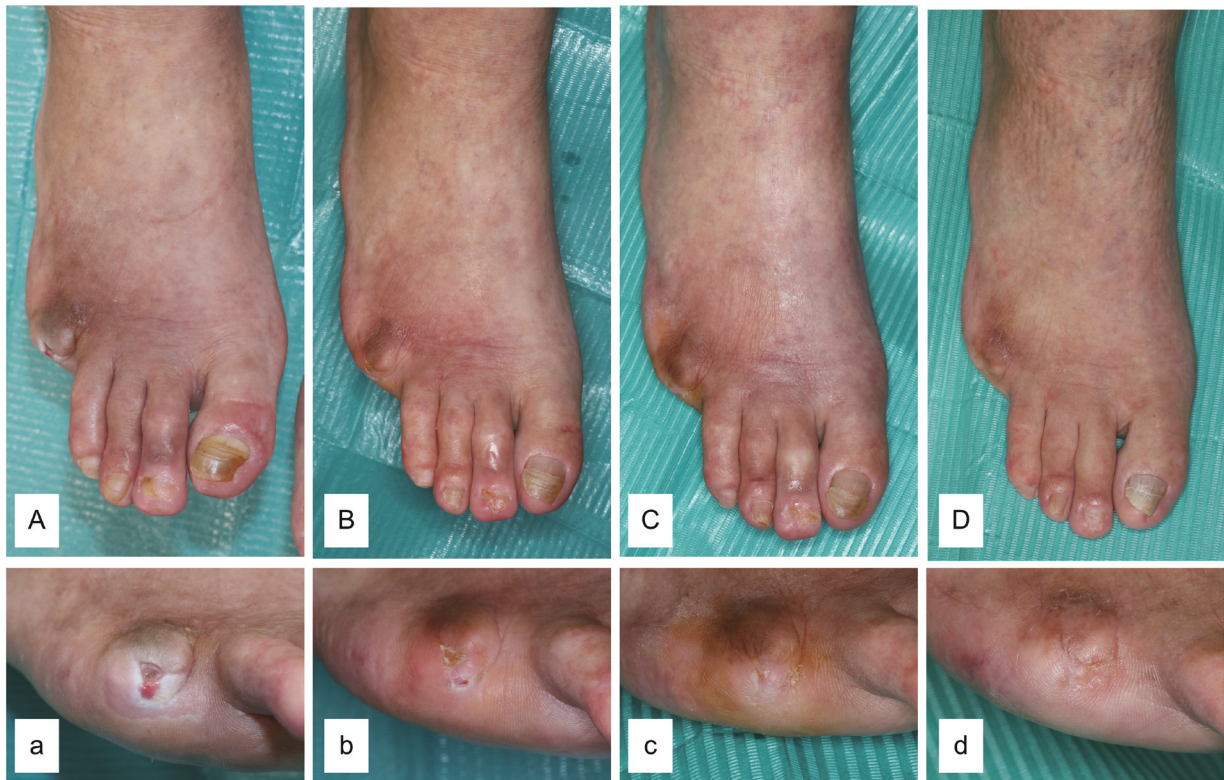

Fig. 4. Healing process of the right foot ulcer post-spinal cord stimulation.

A, a: 1 month, B, b: 3 months, C, c: 6 months, D, d: 12 months. The necrotic tissue gradually decreased, and tissue granulation gradually increased. There was no ulcer, and the color of the foot improved 12 months post-operation.

often intractable. During treatment, the patient experiences severe pain, which often interferes with their daily life.

There have been reports of improvement in microcirculation and ischemic pain after SCS in refractory cases where revascularization is difficult. The proposed mechanism of action involves sympathetic inhibition and retrograde excitation of the afferent fibers. Retrograde excitation of the afferent fibers causes the release of calcitonin gene-related peptide (CGRP), the most potent neuropeptide vasodilator. It acts on vascular endothelial cells to produce and release nitric oxide, which causes vascular smooth muscle dilation. In addition, CGRP directly binds to the CGRP-1 receptor in vascular smooth muscles and dilates blood vessels. These effects improve microcirculation<sup>6,7)</sup>. There have been reports of improvement in ischemic pain after SCS in refractory cases where revascularization is difficult<sup>8-11)</sup>.

To the best of our knowledge, there have been five reports of SCS for systemic sclerosis, all of which only assessed pain with the VAS and did not follow the transition of the pain in detail<sup>12-16)</sup>. Our

patient showed dramatic improvement in the pain and a trend toward wound healing with SCS treatment. Pain was assessed in detail using the VAS (a single-dimensional self-assessment scale that is sensitive and reproducible), the SF-MPQ-2 (which separates neuropathic and non-neuropathic pain while providing both sensory and emotional ratings), and the PCS (which assesses catastrophic thinking). All scores showed dramatic improvement immediately after the trial. The pain had nearly completely subsided 3 months postoperatively, and the analgesic effect has continued to the last follow-up (Fig. 2).

The ulcer gradually reduced in size and healed 12 months postoperatively. To date, there has been no recurrence. The reasons for this occurrence are as follows: First, it is thought that the SCS itself may have improved microcirculation, as in previous reports. Second, it is thought that the amount of daily exercise increases as the pain reduces, which leads to improvement in microcirculation<sup>17)</sup>.

This case showed an improvement in pain, ulcer healing, and reduction in the occurrence of Raynaud's phenomenon. The patient became less

aware of the pain during daily life activities. Patient satisfaction was extremely high, with no ulcer recurrence and no need for a cane while walking. SCS is suggested for patients with systemic sclerosis and skin ulcers due to its efficacy.

### Conflicts of interest disclosure

All authors certify that they have no affiliations with or involvement in any organization or entity with any financial interest (e.g., honoraria; educational grants; participation in speakers' bureaus; membership, employment, consultancies, stock ownership, or other equity interest; and expert testimony or patent-licensing arrangements) or non-financial interest (e.g., personal or professional relationships, affiliations, knowledge, or beliefs) in the subject matter or materials discussed in this manuscript.

### Informed consent

Informed consent was obtained from the patient including in this study.

### References

- Gabrielli A, Avvedimento EV, Krieg T. Systemic sclerosis. *N Engl J Med*, **360** : 1989-2003, 2009.
- Barsotti S, Orlandi M, Codullo V, *et al.* One year in review 2019 : systemic sclerosis. *Clin Exp Rheumatol*, **119** : 3-14, 2019.
- The British Pain Society (2009). Spinal cord stimulation for the management of pain : recommendations for best clinical the management of pain : recommendations for best clinical practice. Available at : [https://www.britishpainsociety.org/static/uploads/resources/files/book\\_scs\\_main\\_1.pdf](https://www.britishpainsociety.org/static/uploads/resources/files/book_scs_main_1.pdf), Accessed November 5, 2020.
- Dworkin RH, Turk DC, Revicki DA, *et al.* Development and initial validation of an expanded and revised version of the Short-form McGill Pain Questionnaire (SF-MPQ-2). *Pain*, **144** : 35-42, 2009.
- Cano A, Leonard MT, Franz A. The significant other version of the Pain Catastrophizing Scale (PCS-S) : preliminary validation. *Pain*, **119** : 26-37, 2005.
- Linderoth B, Foreman RD. Physiology of spinal cord stimulation : review and update. *Neuromodulation*, **2** : 150-164, 1999.
- Wu M, Linderoth B, Foreman RD. Putative mechanisms behind effects of spinal cord stimulation on vascular diseases : a review of experimental studies. *Auton Neurosci*, **138** : 9-23, 2008.
- Jivegard LE, Augustinsson LE, Holm J, Risberg B, Ortenwall P. Effects of spinal cord stimulation (SCS) in patients with inoperable severe lower limb ischaemia : a prospective randomised controlled study. *Eur J Vasc Endovasc Surg*, **9** : 421-425, 1995.
- Spincemaille GH, Klomp HM, Steyerberg EW, Habbema JD. Pain and quality of life in patients with critical limb ischaemia : results of a randomized controlled multicentre study on the effect of spinal cord stimulation. ESES study group. *Eur J Pain*, **4** : 173-184, 2000.
- Claeys LG, Horsch S. Transcutaneous oxygen pressure as predictive parameter for ulcer healing in endstage vascular patients treated with spinal cord stimulation. *Int Angiol*, **15** : 344-349, 1996.
- Kumar K, Toth C, Nath RK, Verma AK, Burgess JJ. Improvement of limb circulation in peripheral vascular disease using epidural spinal cord stimulation : a prospective study. *J Neurosurg*, **86** : 662-669, 1997.
- Fiume D. Spinal cord stimulation in peripheral vascular pain. *Appl Neurophysiol*, **46** : 290-294, 1983.
- Francaviglia N, Silvestro C, Maiello M, Bragazzi R, Burnucci C. Spinal cord stimulation for the treatment of progressive systemic sclerosis and Raynaud's syndrome. *Br J Neurosurg*, **8** : 567-571, 1994.
- Neuhauser B, Perkmann R, Klingler PJ, Giacomuzzi S, Kofler A, Fraedrich G. Clinical and objective data on spinal cord stimulation for the treatment of severe Raynaud's phenomenon. *Am Surg*, **67** : 1096-1097, 2001.
- Sibell DM, Colantonio AJ, Stacey BR. Successful use of spinal cord stimulation in the treatment of severe Raynaud's disease of the hands. *Anesthesiology*, **102** : 225-227, 2005.
- Provenzano DA, Nicholson L, Jarzabek G, Lutton E, Catalane DB, Mackin E. Spinal cord stimulation utilization to treat the microcirculatory vascular insufficiency and ulcers associated with scleroderma : a case report and review of the literature. *Pain Med*, **12** : 1331-1335, 2011.
- Chang CC, Chen MY, Shen JH, Lin YB, Hsu WW, Lin BS. A quantitative real-time assessment of Buerger exercise on dorsal foot peripheral skin circulation in patients with diabetes foot. *Medicine (Baltimore)*, **95** : doi : 10.1097/MD.0000000000005334, 2016.