



## Unexpected placenta accreta spectrum after the use of assisted reproductive technology in women with adenomyomectomy

メタデータ	<p>言語: English</p> <p>出版者: The Fukushima Society of Medical Science</p> <p>公開日: 2021-04-19</p> <p>キーワード (Ja):</p> <p>キーワード (En): adenomyosis, placenta accreta spectrum, preterm birth</p> <p>作成者: Jin, Toki, Kyoza, Hyo, Fujimori, Mimori, Nomura, Shinji, Hakoza, Yusuke, Suzuki, Daisuke, Nomura, Yasuhisa</p> <p>メールアドレス:</p> <p>所属:</p>
URL	<a href="https://fmu.repo.nii.ac.jp/records/2002019">https://fmu.repo.nii.ac.jp/records/2002019</a>

[Case report]



## Unexpected placenta accreta spectrum after the use of assisted reproductive technology in women with adenomyomectomy

Toki Jin, Hyo Kyozyuka, Mimori Fujimori, Shinji Nomura, Yusuke Hakozaki,  
Daisuke Suzuki and Yasuhisa Nomura

*Department of Obstetrics and Gynecology, Ohta nisinouchi Hospital, Koriyama city, Fukushima, Japan*

(Received January 29, 2021, accepted February 17, 2021)

### Abstract

Placenta accreta spectrum (PAS) is a rare complication that can lead to life-threatening postpartum hemorrhage. PAS can sometimes occur unexpectedly, without placenta previa; such cases can lead to higher maternal mortality and morbidity than expected cases. Here, the authors report a case of unexpected PAS caused by assisted reproductive technology (ART) in a woman with adenomyosis. The patient was a 37-year-old Japanese primipara woman who presented to our hospital at 11 weeks gestation, later returning to her parents' house to give birth. The woman had adenomyosis and underwent adenomyomectomy, which was followed by an ART pregnancy. The patient was admitted to our hospital because of a life-threatening preterm birth, with a short cervix and no evidence of placenta previa. Despite strict perinatal management, preterm rupture of the membrane (PROM) occurred. During laparotomy, the small intestine, rectum, and both right and left ovaries were clumped together and severely adhered to the surface of the uterus. After delivery, manual partial removal of the placenta was performed, resulting in heavy bleeding from the implantation site, which was diagnosed as an unexpected PAS. Following several uterine compression efforts, we successfully preserved the uterus.

**Key words :** adenomyosis, placenta accreta spectrum, preterm birth

### Introduction

Adenomyosis is defined as the ectopic proliferation of endometrial glands and stroma within the myometrium of the uterus, which causes the uterus to become edematous and enlarged<sup>1,2)</sup>. Adenomyosis affects up to 10-20% of women of reproductive age<sup>3)</sup> and often results in severe dysmenorrhea and/or hypermenorrhea. The disease occurs more often in women between the ages of 30 and 40 years, and it is widely accepted that adenomyosis is related to reproductive disorders. Several studies have reported that adenomyosis affects fertility, resulting in women requiring assisted reproductive technology (ART)<sup>3)</sup>.

Placenta accreta spectrum (PAS) is a significant

obstetric complication that can cause life-threatening bleeding. Conventionally, PAS is strongly associated with placenta previa<sup>4)</sup>. However, PAS may occur unexpectedly, in the absence of placenta previa; therefore, it cannot be diagnosed until delivery, necessitating intensive emergency care<sup>5)</sup>. Here, we present the case of a woman with unexpected PAS who conceived after adenomyomectomy following ART. In this case, we performed an emergency cesarean section due to preterm rupture of the membrane (PROM), and the patient was clinically diagnosed with unexpected PAS at the time of delivery, and manual placenta removal was required.

Corresponding author : Hyo Kyozyuka, MD, PhD. E-mail : kyozyuka@fmu.ac.jp

©2021 The Fukushima Society of Medical Science. This article is licensed under a Creative Commons [Attribution-NonCommercial-ShareAlike 4.0 International] license.  
<https://creativecommons.org/licenses/by-nc-sa/4.0/>

### Case presentation

A 37-year-old Japanese primipara woman presented to our hospital at 11 weeks gestation, returning to her parents' house to give birth. The woman had adenomyosis resulting in sterility and hoped to become pregnant. She had previously undergone adenomyomectomy and right chocolate cystectomy to improve her fertility at her previous medical institution. At that time, her surgeons had opened the uterine cavity from the anterior surface of the uterus and had excised the lesion, including the serosa existing on the posterior wall of the uterus, using an electric knife. Subsequently, pregnancy was established using ART (intracytoplasmic sperm injection and frozen embryo transfers).

At 29 weeks, although she had no symptoms, she was admitted to our hospital due to the risk of preterm birth owing to a shortened cervical length. Magnetic resonance imaging (MRI) at 30 weeks showed no evidence of placenta previa, and the placenta was mainly located on the left fallopian tube angle and partially on the posterior wall (Figure 1). Because of the location of placentation, the uterine wall was extruded toward the left fallopian tube (Figure 2). MRI also showed loss of continuity of the uterine wall, suggesting the presence of unexpected PAS (Figure 2).

Emergency cesarean section was performed at 34 weeks because of PROM. During laparotomy, we found that the Douglas fossa was completely closed via a strict adhesion between the uterine surface, both right and left ovaries, sigmoid intestine,

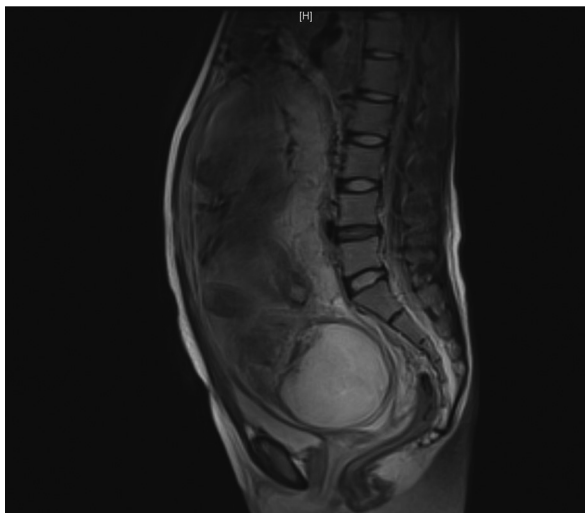


Figure 1. Sagittal T2-weighted MRI at 30 weeks showed no evidence of placenta previa, and the placenta was mainly located on the posterior wall (T2).

and small intestine (Figure 3). This strict adhesion would complicate the performance of a cesarean hysterectomy in case of emergency.

A baby weighing 2,321 g (Apgar score 7 at 1 min, 7 at 5 min) was delivered through a lower uterine transverse incision. As there was no sign of placental separation, manual removal of the placenta was conducted, resulting in a blood loss of 2,000 mL, mainly at the site of placentation. Eventually, two units of red blood cells were transfused, and the

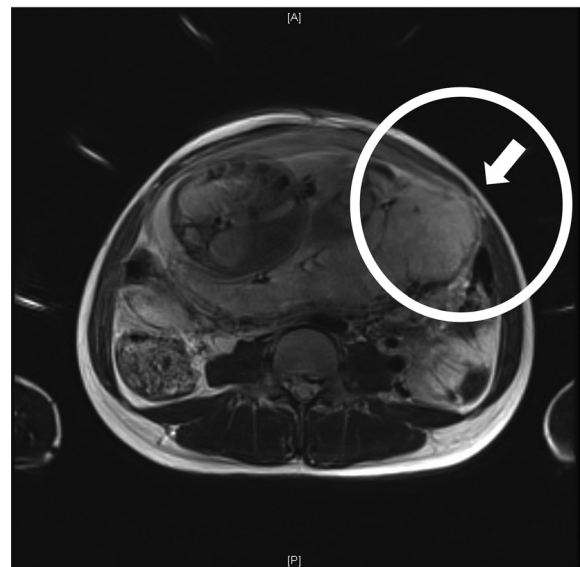


Figure 2. Coronal T2-weighted MRI at 30 weeks showed that the placenta was mainly located on the left fallopian tube angle. Because of the location of placentation with Figure 1, the uterine wall was extruded toward the left fallopian tube (circle). The MRI also showed a loss of continuity of the uterine wall (arrow), suggesting the presence of unexpected PAS.

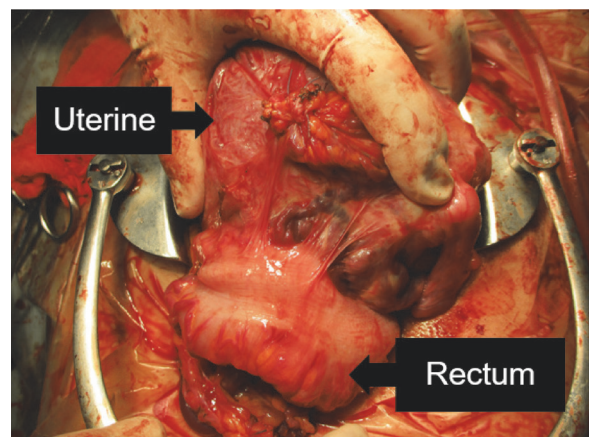


Figure 3. Intraoperative image. The Douglas fossa was completely closed because of strict adhesion between the uterine surface, bile ovary, sigmoid intestine, and small intestine.

uterus was successfully preserved without any further intervention. The patient was discharged without any complications at 5 days postpartum. Histopathological examination showed stage 3 chorioamnionitis and no evidence of funisitis.

## Discussion

Adenomyosis is associated with reproductive problems. Uterine surgery is one of the strategies applied in women with adenomyosis who hope to become pregnant. However, surgery carries the risk of obstetric outcomes. Sugiyama *et al.* reviewed 10 cases of obstetric outcomes in women who underwent adenomyomectomy before pregnancy<sup>6)</sup> and reported three patients who showed preterm delivery; all three of them had a very thin uterus to the extent that the fetus could be observed through the uterine wall, suggesting abnormal placental adhesion. Uterine rupture during pregnancy is another potential risk factor for women who have undergone adenomyomectomy. A recent review by Morimatsu *et al.* showed that the rate of uterine rupture after adenomyomectomy during pregnancy is 6.0%<sup>7)</sup>. ART is another established strategy to overcome sterility. In addition to these reports, the present case showed unexpected PAS, which was clinically diagnosed at delivery. Using the largest Japanese birth cohort study, Kyojuka *et al.* previously reported that ART is an independent risk factor for unexpected PAS<sup>8)</sup>. The reason ART increases the risk of PAS is not entirely clear. Esh *et al.* proposed two possible pathogeneses: 1) mechanical factors, including primary deficiency in the decidua due to local trauma at the uterine wall, and 2) biological factors, including abnormal maternal response to trophoblast invasion<sup>9)</sup>. Our case showed unexpected PAS due to adenomyosis treated via pre-conceptual uterine surgery followed by ART. The MRI findings in these cases suggest that the placenta was attached around the fallopian tube where the decidua is more likely to be deficient. Although cases with morbid adherent placentation (MAP) following laparoscopic adenomyomectomy have been reported<sup>10)</sup>, the causal relationship between adenomyomectomy itself and MAP is unknown. So far, we attributed the unexpected PAS to ART, in which the frozen embryo easily transfers to the fallopian tube where the decidua is more likely to be thin.

Because adenomyosis in pregnancy is rare, its obstetric outcomes, including maternal morbidity, are unknown. With advances in ART, the number of pregnancies with adenomyosis is increasing. Re-

cently, using a Japanese birth cohort study, Yamaguchi *et al.* reported that adenomyosis increases the risk of preterm birth <37 weeks (aOR [adjusted odds ratio]: 2.5, 95%CI [confidence interval] 1.8–3.4), and <34 weeks (aOR: 1.9, 95%CI: 1.0–3.6)<sup>3)</sup>, as was shown in our case. In these cases, two clinical implications were identified for pregnant women undergoing adenomyomectomy: first, pregnant women who conceived after adenomyomectomy had increased risk of unexpected PAS, which could require unexpected medical intervention, including manual removal of the adherent placenta, which could cause life-threatening postpartum hemorrhage<sup>11)</sup> and/or increased morbidity<sup>12)</sup> because they usually conceived via ART. Second, these unexpected medical interventions could occur suddenly because adenomyosis itself carries a risk of preterm birth.

Therefore, specialists in endocrinology and infertility should provide medical care in addition to achieving short-term outcomes, such as a positive pregnancy test, and provide information about adverse outcomes. In conclusion, obstetric care providers need to pay attention to cases where patients with adenomyosis have conceived by ART after adenomyomectomy, and these women need multidisciplinary management strategies soon after achieving pregnancy.

## Conflict of interest disclosure

The authors have no potential conflicts of interest to declare.

## Patient consent

Informed consent was obtained from the patients for publication of this work.

## Contributors

All authors were involved in the clinical care of the patient and contributed to the conception, drafting, review, and revision of the manuscript. All authors saw and approved the final version of the paper and take full responsibility for the work.

## Funding

This work did not receive any specific grant from funding agencies.

## Provenance and peer review

This case report was peer reviewed.

## Abbreviations

Adjusted odds ratio : aOR

Assisted reproductive technology : ART

Confidence interval : CI

Magnetic resonance imaging : MRI

Placenta accreta spectrum : PAS

Preterm rupture of membrane : PROM

## References

1. Harada T, Khine YM, Kaponis A, Nikellis T, Decavalas G, Taniguchi F. The impact of adenomyosis on women's fertility. *Obstet Gynecol Surv*, **71** : 557-568, 2016.
2. Leyendecker G, Wildt L, Mall G. The pathophysiology of endometriosis and adenomyosis : tissue injury and repair. *Arch Gynecol Obstet*, **280** : 529-538, 2009.
3. Yamaguchi A, Kyojuka H, Fujimori K, *et al.* Risk of preterm birth, low birthweight and small-for-gestational-age infants in pregnancies with adenomyosis : A cohort study of the Japan Environment and Children's Study. *Acta Obstet Gynecol Scand*, **98** : 359-364, 2019.
4. Miller DA, Chollet JA, Goodwin TM. Clinical risk factors for placenta previa-placenta accrete. *Am J Obstet Gynecol*, **177** : 210-214, 1997.
5. Suzuki N, Kyojuka H, Fukuda T, *et al.* Late-diagnosed cesarean scar pregnancy resulting in unex-pected placenta accreta spectrum necessitating hysterectomy. *Fukushima J Med Sci*, **66** : 156-159, 2020.
6. Sugiyama M, Takahashi H, Baba Y, *et al.* Perinatal outcome of pregnancy after adenomyomectomy : summary of 10 cases with a brief literature review. *J Matern Fetal Neonatal Med*, **33** : 4145-4149, 2020.
7. Morimatsu Y, Matsubara S, Okuchi A, *et al.* Shikyūsenkinshō kakushutsujutsu go no ninshin-Shikyū haretsu no literature review to sankā kanri nit-suited [Pregnancy after adenomyomectomy-literature review of uterine rupture and obstetrical management]. *Sankā to fujinka [Japanese Journal of Obstetrics and Gynaecology]*, **74** : 1047-1053, 2007. Japanese
8. Kyojuka H, Yamaguchi A, Suzuki D, *et al.* Risk factors for placenta accreta spectrum : findings from the Japan environment and Children's study. *BMC Pregnancy Childbirth*, **19** : 447, 2019.
9. Esh-Broder E, Ariel I, Abas-Bashir N, Bdolah Y, Celnikier DH. Placenta accreta is associated with IVF pregnancies : a retrospective chart review. *BJOG*, **118** : 1084-1089, 2011.
10. Matsuzaki S, Yoshino K, Tomimatsu T, *et al.* Placenta accreta following laparoscopic adenomyomectomy : a case report. *Clin Exp Obstet Gynecol*, **43** : 763-765, 2016.
11. Eller AG, Porter TF, Soisson P, Silver RM. Optimal management strategies for placenta accreta. *BJOG*, **116** : 648-654, 2009.
12. Yap YY, Perrin LC, Pain SR, Wong SF, Chan FY. Manual removal of suspected placenta accreta at cesarean hysterectomy. *Int J Gynaecol Obstet*, **100** : 186-187, 2008.