



## Isolated congenital megacystis with spontaneous resolution: a case report

メタデータ	<p>言語: English</p> <p>出版者: The Fukushima Society of Medical Science</p> <p>公開日: 2017-08-28</p> <p>キーワード (Ja):</p> <p>キーワード (En): congenital, isolated megacystis, prenatal ultrasound, spontaneous healing, unobstructed</p> <p>作成者: Nakamura, Toshihiko</p> <p>メールアドレス:</p> <p>所属:</p>
URL	<a href="https://fmu.repo.nii.ac.jp/records/2001939">https://fmu.repo.nii.ac.jp/records/2001939</a>

[Case Report]

## Isolated congenital megacystis with spontaneous resolution : a case report

Toshihiko Nakamura

*Division of Neonatology, Tokyo Metropolitan Hachioji Children's Hospital, Tokyo, Japan*

(Received November 16, 2016, accepted June 28, 2017)

### Abstract

The patient was a male infant with an antenatal diagnosis of huge intraabdominal mass. Prenatal ultrasound at 35 weeks gestation revealed a markedly enlarged cystic mass in the lower abdomen. After birth at 38 weeks, the infant was allowed to void spontaneously and passed meconium. Ultrasonography showed an enlarged bladder with wall thickness of 2.9 mm and no hydronephrosis. Voiding cystourethrograms showed no evidence of vesicoureteral reflex and posterior urethral valve. The post-void residuals were 15 mL at 11 days of life, 5 mL at 1 month and 0 mL at 5 months. Over 10 years' follow-up, the patient remains completely well without any urinary or gastrointestinal symptoms. In sporadic isolated congenital megacystis, which is not so rare in fetuses but is quite rare in neonates, gastrointestinal symptoms may be masked in the neonatal period ; however, the present patient has never presented any symptoms.

**Key words :** congenital, isolated megacystis, prenatal ultrasound, spontaneous healing, unobstructed

### Introduction

Congenital megacystis is an infrequently occurring anomaly investigated during prenatal ultrasound screening, with a prevalence of about 0.06 to 0.25%<sup>1)</sup>. The outcome of this condition is different according to the gestational age at diagnosis<sup>2)</sup>. The best outcome occurs when congenital megacystis is detected in the 3<sup>rd</sup> trimester. Congenital megacystis often is complicated by gastrointestinal disorders such as megacystis microcolon intestinal hypoperistalsis syndrome (MMIHS). Because the gastrointestinal symptoms may be masked in the neonatal period in such cases, attention should be paid to the gastrointestinal tract over long-term follow-up.

Although cases of fetal megacystis are not extremely rare, cases of so-called isolated congenital megacystis (congenital megacystis without complications) in neonates are quite rare. I report a case of congenital megacystis diagnosed during the 3<sup>rd</sup> trimester that is without any etiology of urologic pathology such as lower urinary tract obstruction or ureterovesical reflex. To my knowledge, this case has the longest follow-up time of all previous re-

ports of isolated congenital megacystis.

### Case report

The patient was a male infant with an antenatal diagnosis of huge intraabdominal mass who was born at 38 weeks and 4 days via uncomplicated spontaneous vaginal delivery and weighed 3,284 grams with Apgar scores of 9 and 9 at one and five minutes, respectively.

Prenatal ultrasound during the 1<sup>st</sup> and 2<sup>nd</sup> trimesters showed normal fetal findings, but at 35 weeks gestation, it revealed a markedly enlarged cystic mass in the lower abdomen with normal amniotic fluid volume. At 36 weeks 3 days gestation, fetal ultrasound had shown no remarkable change in the volume of the mass with failure to empty over a period of at least 53 min and with the keyhole sign (Figure 1)<sup>3)</sup>. The fetal diagnosis was congenital megacystis without hydroureteronephrosis.

Physical examination of the infant on admission to our NICU at Former Tokyo Metropolitan Hachioji Children's Hospital revealed only a distended abdomen (Figure 2). He was initially allowed to void

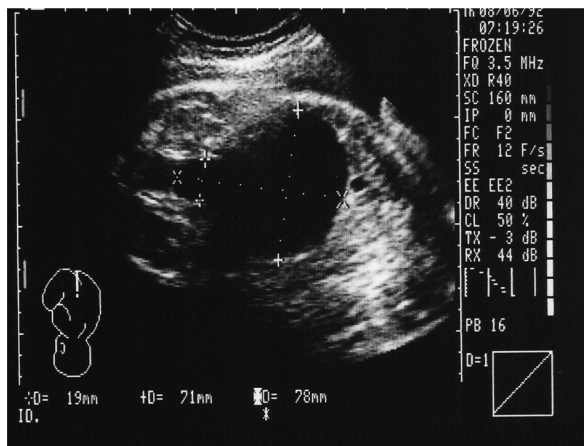


Fig. 1. Prenatal ultrasound at 36 weeks gestation. A complete structural ultrasound evaluation was performed by a trained ultrasonographer that revealed an enlarged bladder (71 mm in sagittal length) with failure to empty over at least 53 min, which is greater than the 45 min generally accepted as the upper limit of normal<sup>3,10</sup>. The scan shows the keyhole sign, representing dilatation of the posterior urethra. The sagittal length is 78 mm, which is greater than gestational age (in weeks) + 12 (upper limit of the 95% confidence interval).

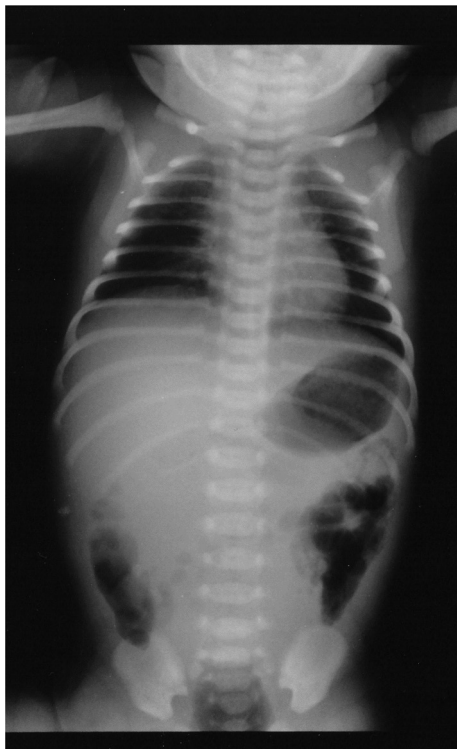

Fig. 2. Plain radiograph of the chest and abdomen on admission at 2 hours after birth. The radiograph revealed a homogeneous mass in the mid-abdomen pushing the bowel gasses to the bilateral sides.

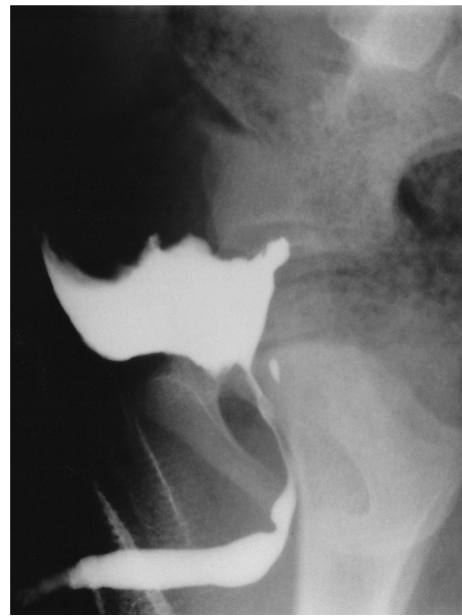


Fig. 3. Voiding cystourethrogram at 6 months of age. The infant's bladder was remarkably enlarged. No vesicoureteral reflux or posterior urethral valve was revealed, but the posterior urethra was not adequately dilated at the maximum rate of voiding.

spontaneously and passed meconium soon after birth. Ultrasonography of his abdomen showed an enlarged bladder with wall thickness of 2.9 mm<sup>3)</sup> and no hydronephrosis.

Voiding cystourethrograms (VCGs) were performed at 11 days of life and at 1.5, 6, 15, and 30 months of life. None of the VCGs showed any evidence of vesicoureteral reflex and posterior urethral valve, but the posterior urethra was not adequately dilated (Figure 3). The post-void residuals were about 15 mL, 5 mL, 0 mL, 0 mL, and 0 mL, respectively, at the above times. Because of the follow-up of the inadequate dilatation of the posterior urethra, the VCGs after the time of zero post-void residual were investigated. An intravenous pyelogram at the same time as the first VCG revealed a right duplicate renal pelvis without hydroureteronephrosis. Magnetic resonance imaging at 19 days of life showed megacystis with a thick bladder wall and no abnormalities in the genital, rectal, and spinal areas.

We have continued to follow this patient for nearly 10 years with serial physical examinations, ultrasound examinations, serum creatine levels, and urinalysis. He remains completely well without any urinary or gastrointestinal symptoms.

### Discussion

According to a recent systematic review, fetal megacystis is most commonly defined as a longitudinal bladder dimension of  $\geq 7$  mm in the 1<sup>st</sup> trimester, but in the 2<sup>nd</sup> and 3<sup>rd</sup> trimesters, it is often defined as no evidence of bladder emptying during a period of at least 45 min or a sagittal dimension (in mm) greater than the gestational age (in weeks) + 12<sup>3)</sup>. Additional structural abnormalities such as a thickened bladder wall, objectively defined as a wall thickness of  $>3$  mm, or the keyhole sign are present. However, this systematic review notes only some consensus on the sonographic definition of fetal megacystis. The precise diagnosis is often uncertain until after birth<sup>3)</sup>. The highlight of this case is the presence of a huge lower abdominal cystic mass discovered by fetal ultrasound in the 3<sup>rd</sup> trimester. The cyst was that of megacystis as precisely revealed by ultrasound at birth.

The patient experienced no recurrent urinary tract infections, and post-void residuals decreased over time. He had completely improved by 6 months of life with no gastrointestinal complications such as MMIHS or chronic idiopathic intestinal pseudo-obstruction syndrome (CIIPS). There are many reports of megacystis with complications such as MMIHS, CIIPS, prune belly syndrome, posterior urethral valve, anorectal malformations, and transverse sinus thrombosis. Also, karyotype anomalies are found in 15% of infants with fetal megacystis, including mainly trisomy 18, trisomy 13, and trisomy 21<sup>3)</sup>. However, due to the patient's clinical symptoms and clinical course, the karyotype was not investigated.

To my knowledge, there are very few reports of congenital megacystis without complications in the neonatal period<sup>4-10)</sup>. Including the present case, previous reports of congenital megacystis without complications are summarized in Table 1. The follow-up period in the 7 previous cases ranged from 3 months at the shortest to 6 years at the longest. The present case has the longest follow-up time (more than 10 years) of all reported cases. Furthermore, this case was the only one treated without surgery, clean intermittent catheterization, or prophylactic antibiotics. In addition, because there were no gastrointestinal symptoms during the clinical course, a barium enema and rectal mucosal biopsy were not done. This aspect of the patient's treatment strategy is consistent with that reported by Alizadeh<sup>10)</sup>.

Some postulated mechanisms are reported in a

very few cases : visceral myopathy, spontaneous resolution of congenital urethral stricture, and a variant of MMIHS. Megacystis may represent a collection of several different etiologies. This patient's clinical course indicates that the etiology is most likely due to spontaneous resolution of his congenital urethral stricture.

With the recent spread of prenatal ultrasound in obstetric care systems, the detection rate of abnormal masses in the fetal abdominal cavity seems to be increasing. Nevertheless, reports of isolated congenital megacystis have not increased. It is unclear whether this disease is truly rare or whether the rate of congenital megacystis diagnosis is increasing, but in the course of observation of the digestive complications, patients have been diagnosed as having a disease such as MMIHS.

When an intraperitoneal mass is revealed by perinatal ultrasound, it is important to confirm the presence or absence of prenatal hydroureteronephrosis and a digestive system malformation such as prune belly syndrome. Usually, CIIPS occurs relatively early in childhood and adolescence, but it can sometimes also develop in adults. Akaboshi *et al.* reported that it is necessary to consider CIIPS in the differential diagnosis in cases of congenital megacystis without hydroureteronephrosis and postnatal natural urination<sup>12)</sup>. After birth, the appearance of gastrointestinal symptoms such as abdominal distension or constipation should be investigated through long-term follow-up. This case highlights a very rare and favorable clinical course of this condition without the necessity of medication and with eventual resolution of the congenitally enlarged bladder.

### Conflict of interest

The author has no conflicts of interest or financial relationships relevant to this article to disclose.

### References

1. Favre R, Kobler M, Gasser B, Muller F, Nisand I. Early fetal megacystis between 11 and 15 weeks of gestation. *Ultrasound Obstet Gynecol*, **14** : 402-406, 1999.
2. Bornes M, Spaggiari E, Schmitz T, *et al.* Outcome and etiologies of fetal megacystis according to the gestational age at diagnosis. *Prenat Diagn*, **33** : 1162-1166, 2013.
3. Taghavi K, Sharpe C, Stringer MD. Fetal megacystis : A systematic review. *J Pediatr Urol*, **13** : 7-15, 2017.

Table 1. Characteristics of published cases and this case of isolated congenital megacystis

Case	Reference (year)	GA at 1 <sup>st</sup> detection of megacystis	Fetal daigosis	GA at delivery	Birth weight (gr)	Sex	Delivery mode	Indication of delivery	Examination after birth	Management of megacystis	Follow up (years)	Prognosis
1	Inamdar S. <i>et al.</i> (1984)	NA	NA	NA	2,600	M	CS	breech presentation	IVP, VCUG US, CSC	cutaneous vesicostomy, cystoplasty,	6	Residual urine (30 mL)
2	Hurwitz A. <i>et al.</i> (1984)	34	megacystis, moderate	37	3,800	M	TVD	spontaneous onset after amniotomy	IVP, VCUG, US	spontaneous healed	0.25	NP
3	Peng HC (1998)	28	large cystic lesion	36	3,435	F	CS	NA	CT Laparotomy	cystoplasty	0.67	NP
4	Matsumoto F. <i>et al.</i> (1999)	29	megacystis hydronephrosis	33	2,510	F	CS	progressive hydronephrosis	VCUG, US, UD UGI, BE, RB	CIC	1	Mild CIPPS
5	Shimizu M. <i>et al.</i> (2011)	NA	intraabdominal mass	38	NA	F	CS	NA	US, CT, BE, VCUG, MRI, CSC, UD, RB	CIC laxatives	4	Mild CIPPS
6	Johnson EK. <i>et al.</i> (2013)	18	megacystis hydronephrosis	40	4,500	M	TVD	spontaneous onset	US, VCUG UD,	prophylactic antibiotics	3	NP
7	Alizadeh F (2014)	32	megacystis oligohydramnios	full-term	NA	M	NA	NA	VCUG, US	CIC	0.5	NP
8	this case	35	intraabdominal cystic mass	38	3,284	M	TVD	spontaneous onset	US, VCUG MRI, IVP	spontaneous healed	10	NP

GA=gestational age ; TVD=transvaginal delivery ; CS=cesarean section ; NA=not available ; VCUG=voiding cystourethrogram ; CSC=cystoscopy ; MRI=magnetic resonance imaging ; US=ultrasound ; IVP=intra venous pyelogram ; UGI=upper gastrointestinal imaging ; BE=barium enema ; RB=rectal biopsy ; CIC=clean intermittent catheterization ; UD=urodynamic study ; CIPPS=chronic idiopathic intestinal pseudo-obstruction syndrome ; NP=nothing particular

4. Inamdar S, Mallouh C, Ganguly R. Vesical gigantism or congenital megacystis. *Urology*, **119** : 601-603, 1984.
5. Hurwwit A, Yagel S, Rabinovitz R, Mogle P. Hydramnios caused by pure megacystis. *J Clin Ultrasound*, **12** : 110-111, 1984.
6. Peng HC. Congenital megacystis : a case report. *Zhonghua Yi Xue Za Zhi (Taipei)*, **61** : 235-238, 1998.
7. Matsumoto F, Miyamoto I, Yabumoto H. Fetal megacystis with idiopathic intestinal pseudo-obstruction syndrome : a case report. *Jpn J Urol*, **90** : 771-774, 1999.
8. Shimizu M, Nishio S, Ueno K, *et al.* Isolated congenital megacystis without intestinal obstruction : a mild variant of chronic intestinal pseudoobstruction syndrome ? *J Pediatr Surg*, **46** : E29-32, 2011.
9. Johnson EK, Nelson CP. Spontaneous resolution of isolated congenital megacystis : the incredible shrinking bladder. *J Pediatr Urol*, **9** : e46-50, 2013.
10. Alizadeh F. Isolated congenital megacystis with spontaneous resolution : an exceedingly rare entity. *Urol J*, **11** : 1514-1516, 2014.
11. Montemarano H, Bulas DI, Rushton H, Selby D. Bladder distention and pyelectasis in the male fetus : cause, comparisons, and contrasts. *J Ultrasound Med*, **17** : 743-749, 1998.
12. Akaboshi S, Tanaka T, Ohtani K, Aondo G, Kishi K, Katou K. Two cases of prenatal diagnosed megacystis : relation to chronic idiopathic intestinal pseudo-obstruction syndrome. *Jpn J Pediatr*, **43** : 631-634, 1990. (in Japanese)