



# Remnant left lobe torsion causing hepatic venous outflow obstruction after hepatic right lobectomy for giant hepatocellular carcinoma: report of a case

メタデータ	<p>言語: English</p> <p>出版者: The Fukushima Society of Medical Science</p> <p>公開日: 2015-07-06</p> <p>キーワード (Ja):</p> <p>キーワード (En): hepatic venous outflow obstruction (HVOO), right hepatectomy, giant liver tumor, torsion of the remnant liver</p> <p>作成者: Sato, Naoya, Kenjo, Akira, Tsuchiya, Takao, Anazawa, Takayuki, Haga, Junichiro, Sato, Tetsu, Muto, Makoto, Kimura, Takashi, Gotoh, Mitsukazu</p> <p>メールアドレス:</p> <p>所属:</p>
URL	<p><a href="https://fmu.repo.nii.ac.jp/records/2001875">https://fmu.repo.nii.ac.jp/records/2001875</a></p>

[Case Report]

## REMNANT LEFT LOBE TORSION CAUSING HEPATIC VENOUS OUTFLOW OBSTRUCTION AFTER HEPATIC RIGHT LOBECTOMY FOR GIANT HEPATOCELLULAR CARCINOMA : REPORT OF A CASE

NAOYA SATO, AKIRA KENJO, TAKAO TSUCHIYA, TAKAYUKI ANAZAWA,  
JUNICHIRO HAGA, TETSU SATO, MAKOTO MUTO, TAKASHI KIMURA  
and MITSUKAZU GOTOH

*Department of Regenerative Surgery, Fukushima Medical University*

(Received January 24, 2014, accepted May 28, 2014)

**Abstract :** We report the case of a 67-year-old man with remnant left liver torsion causing acute hepatic venous outflow obstruction after right hepatectomy for giant hepatocellular carcinoma, which was successfully treated with surgery. After the primary surgery, he developed significant liver dysfunction and renal failure. Doppler ultrasonography disclosed gradual reduction of hepatic perfusion. Abdominal computed tomography revealed that the swollen remnant liver was dislocated in the right subphrenic space. After surgical repositioning of the left lobe into its anatomical position, the hepatic congestion immediately disappeared, and the hemodynamic parameters improved. The falciform and round ligaments were fixed to the anterior abdominal wall to keep the remnant liver in the anatomical position. His postoperative course was uneventful. Doppler ultrasonography was useful to assess hepatic perfusion for screening of acute hepatic venous outflow obstruction and abdominal computed tomography is definitive for diagnosis. Fixation of remnant liver may be effective for preventing hepatic venous outflow obstruction after right hepatectomy, particularly for giant tumor.

**Key words :** hepatic venous outflow obstruction (HVOO), right hepatectomy, giant liver tumor, torsion of the remnant liver

### INTRODUCTION

Hepatic venous outflow obstruction (HVOO) is recognized as a potentially lethal complication after living donor liver transplantation (LDLT)<sup>1,2)</sup>. It has not been well-known that this condition can occur after hepatic resection. The incidence after liver resection is lower than LDLT because the remnant liver usually has anatomical supports to prevent its dislocation whereas graft liver in LDLT has a loss of them completely. To our knowledge, only seven cases of HVOO after hepatectomy have been reported in the literature<sup>3-8)</sup>. After right hepatic lobectomy, the remnant left lobe tends to spontaneously rotate around the inferior vena cava (IVC), which can causes a risk of HVOO because of kinking of the he-

patic vein<sup>9)</sup>. We describe a successfully treated case of acute HVOO due to kinking of the middle and left hepatic vein trunks after right hepatectomy for giant hepatocellular carcinoma.

### CASE REPORT

A 67-year-old man was admitted to our hospital presenting with edema of the bilateral lower legs in May 2012. He had a history of hypertension and thyroid cancer. A large mass was evident from physical examination in the right upper quadrant of the abdomen. Abdominal ultrasonography (US) showed a huge hepatic mass in the right hepatic lobe. Hepatitis B and C screening test results were negative. Initial blood examination revealed ane-

---

Corresponding author : Mitsukazu Gotoh E-mail : mgotoh@fmu.ac.jp  
<https://www.jstage.jst.go.jp/browse/fms> <http://www.fmu.ac.jp/home/lib/F-igaku/>

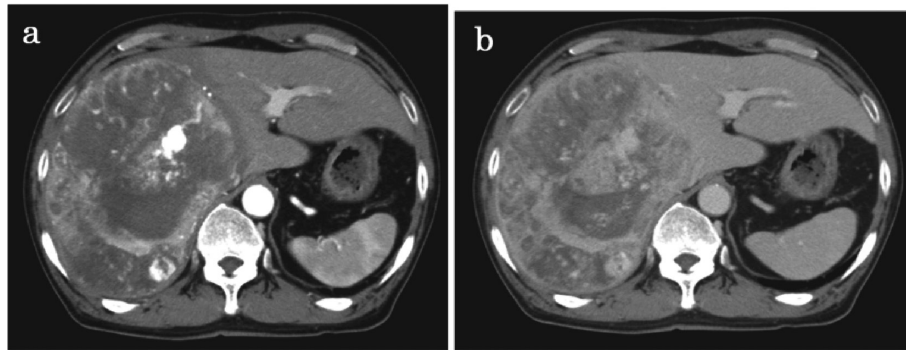


Fig. 1. Enhanced computed tomography showing an 18×15-cm tumor in the right lobe of the liver that is well-enhanced in the arterial phase (a) and fast wash-out in the equilibrium phase (b).

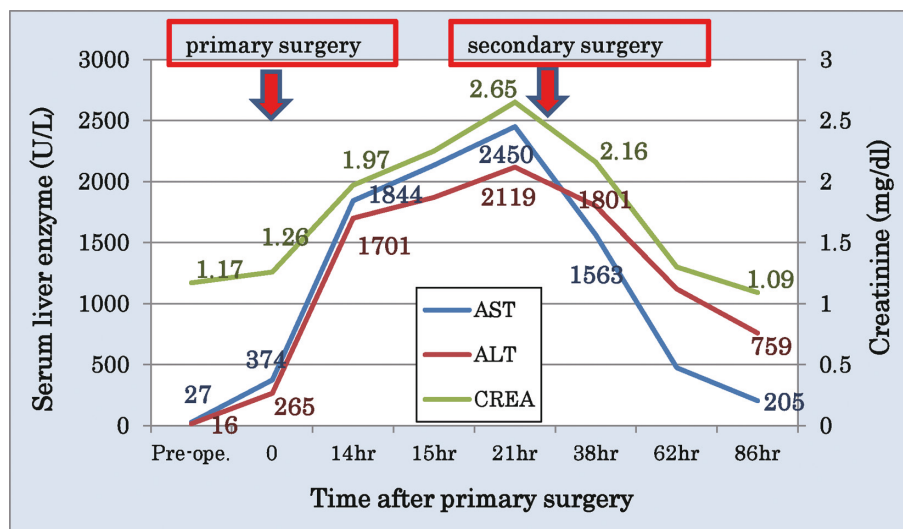


Fig. 2. Perioperative blood examination data of the patient. The elevated serum liver enzyme and creatinine levels detected 15 h after surgery are shown. After fixation of the remnant liver in the anatomical position, progressive deterioration of the liver and renal function dramatically improved.

mia (Hb, 9.9 g/dl) and elevation of a serum protein induced by vitamin K absence or antagonist-II level (1,098 mAU/ml). Contrast-enhanced computed tomography (CT) revealed a well-enhanced 18×15-cm liver tumor in the arterial phase, which was washed out in the equilibrium phase (Fig. 1). A solitary lung nodule was detected in the right lower lobe. The IVC narrowed, and the middle hepatic vein (MHV) was displaced to the left by this giant tumor. The cause of the bilateral lower legs' edema was external compression of the IVC. He underwent operation for a giant hepatocellular carcinoma with right lung metastasis. After mobilization of the right lobe and falciform ligament, he underwent right hepatectomy with partial resection of the right lower lobe of the lung under thoraco-laparotomy. The Cavitron ultrasonic surgical aspirator (CUSA) with a combination of hanging maneuver and intermittent interruption of the hepatic inflow (Pringle

maneuver) were used to transect the hepatic parenchyma. The main trunk of MHV and the left triangular ligament were preserved. The estimated blood loss was 1,850 ml. Before closing the abdominal wound, we ensured that there were no problems with hepatic perfusion of the remnant liver in the spontaneous position (hepatic artery, portal vein, and hepatic vein) under Doppler US.

He was in a persistent hypotensive and oliguric state within a few hours after surgery and needed vasopressor therapy. After 15 h of surgery (the next morning), blood biochemical findings revealed significant elevation of liver enzymes (AST, ALT) and creatinine, which worsened gradually over time (Fig. 2). Doppler US imaging showed that the hepatic venous flow rate was significantly slower than that at the end of surgery and the Doppler waveforms had changed from triphasic to monophasic. After 21 h of surgery, the portal venous flow velocity

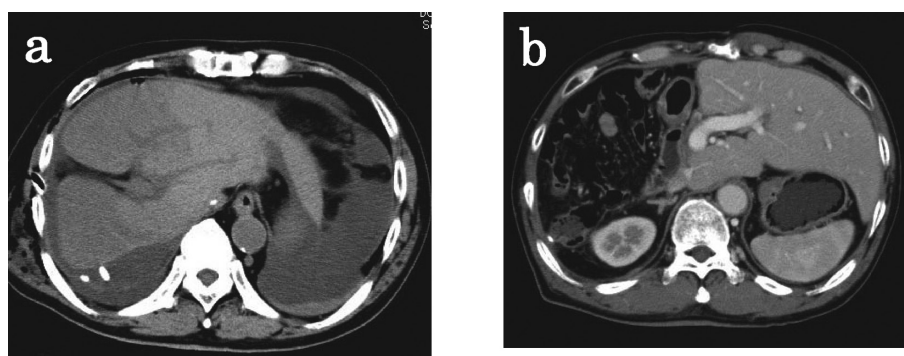


Fig. 3. Abdominal computed tomography (CT) before and after fixation of the remnant liver in the anatomical position. The remnant liver has dislocated into the right subphrenic space and is largely swollen. The left side of the remnant liver is shown as a low-density area by plain CT, which possibly represents a congested area of the liver (a). After fixation, the congested area disappeared (b).

in the remnant liver severely decreased in comparison with that observed 6 h earlier. Abdominal CT revealed an accumulation of ascites in the abdominal cavity and the remnant left liver had become dislocated into the right subphrenic space and was remarkably swollen (Fig. 3). IVC and MHV were extremely kinked, and the infrahepatic IVC was grossly dilated. He was diagnosed with acute HVOO due to torsion of the remnant liver and had an emergency surgery 22 h after primary operation.

A markedly congested and swollen remnant left liver was located in the right subphrenic space during laparotomy. After replacement of the left lobe into its anatomical position, congestion of the remnant liver immediately disappeared, and intraoperative US revealed improvement in hemodynamic parameters of the remnant liver. Hepatic venous flow increased (35.5 cm/sec in spontaneous position and 48.1 cm/sec in anatomical position), and its waveforms changed to a triphasic pattern. In an attempt to keep the remnant liver in the anatomical position, the falciform ligament and round ligament of the liver were fixed to the anterior abdominal wall. The liver tumor was diagnosed as a moderately differentiated hepatocellular carcinoma, and the lung tumors were diagnosed as metastatic tumors of thyroid cancer. The patient's clinical course after the secondary surgery was uneventful and contrast-enhanced CT revealed that the remnant left liver had remained in the anatomical position in a good state of blood perfusion (Fig. 3). He was discharged from the hospital on the 25<sup>th</sup> day. He has been well without tumor recurrence for 30 months after surgery.

## DISCUSSION

HVOO is recognized as one of the lethal complications after liver transplantation because it dete-

riorates liver function and results in graft loss<sup>1,2</sup>. HVOO is caused by stenosis or occlusion of the hepatic vein, leading to hepatic congestion and liver failure<sup>5</sup>. The incidence of HVOO after LDLT has been reported to be 5–13%<sup>10</sup>, whereas the incidence after hepatectomy has been reported to be 0.1%<sup>11</sup>. In LDLT, HVOO usually occurs at the hepatic vein anastomotic site. The following are the causes of HVOO after LDLT: intimal hyperplasia and fibrosis at the anastomotic sites and compression and twisting of anastomosis caused by graft regeneration or rotation<sup>12</sup>. Only seven cases of HVOO after hepatectomy have been reported in the literature<sup>3–8</sup>) (Table 1); the primary surgical procedures were right hepatectomy (four cases), right hepatic trisegmentectomy (two cases), or posterior segmentectomy (one case). Between January 2006 and December 2012, 58 patients underwent right major hepatectomy in our department for hepatocellular carcinoma, cholangiocarcinoma, or LDLTs. This case was our first experience with acute HVOO after liver resection. A factor considered mostly as risk in this case is a size of tumor, mentioned above as 18 cm. According to previously reported cases, the resected tumor sizes were 18 cm to 21 cm (mean, 19.5 cm). Because a large emptied right subphrenic space is created after right hepatectomy for giant tumor, the remnant liver is likely to rotate around IVC and induce kinking of IVC and hepatic vein<sup>8,9</sup>. Two reported patients with HVOO after hepatectomy died because of hepatorenal failure induced by hemodynamic shock or superior mesenteric vein infarction, which was attributed to delayed diagnosis and interventions. Surgical treatment for these patients was performed at least seven days after their operations<sup>3,4</sup>. Treatment for HVOO after right major hepatectomy should be performed before irreversible hepatic and renal failure occur. Early

Table 1. Reported cases of HVOO after liver resection

Author	Age/Sex	Primary disease (tumor size)	Primary liver resection	Symptom	Modality of Dx. of HVOO	Tx after Surgery	Treatment procedure	Outcome
Franklin W <sup>(3)</sup>	8 years/F	Wilms' tumor	RH	jaundice, ascites, hepatomegaly	IVC venography	10 W	Repositioning and fixation of remnant	dead
J. Pitre <sup>(4)</sup>	75 years /M	HCC (21 cm)	RH	fever, jaundice, massive ascites	2nd surgery	7 D	repositioning and fixation of remnant	dead
J. Pitre <sup>(4)</sup>	55 years /M	CRLM	RH with wedge resection of the left lobe	massive ascites, hemodynamic unstable	2nd surgery	urgent	repositioning and fixation of remnant	alive
J. Paineau <sup>(5)</sup>	60 years /M	Cyst (20 cm)	PS	hemodynamically unstable	2nd surgery	3 h	repositioning and fixation of remnant	alive
R.T.P. Poon <sup>(6)</sup>	37 years /M	HCC (18 cm)	RHT	liver congestion	intraoperative Dx.	intra operative	repositioning and fixation of remnant	alive
M. Benesch <sup>(7)</sup>	15 years /M	HCC (21 cm)	RHT with resection of segment I	massive ascites (10 L/day)	IVC venography (intraoperative)	13 D	EMS placement to left hepatic vein	alive
Jeffrey K.W. <sup>(8)</sup>	46 years /F	CRLM	RH	jaundice, slight ascites	IVC venography	15 D	EMS placement across the stenosis	alive

Dx. : diagnosis ; Tx. : Treatment ; RH : right hepatectomy  
RHT : right trisegmentectomy ; PS : posterior segmentectomy

diagnosis and treatment are crucial for patient survival.

In the present case, HVOO was diagnosed for the following reasons : 1) postoperative circulatory insufficiency with oliguria, 2) elevation of serum liver enzymes and serum creatinine after surgery, 3) hepatic vein waveform change on Doppler US, 4) dislocation of the swollen remnant liver on CT, and 5) immediate improvement of hemodynamic parameters and appearance of liver after repositioning. If shock state and acute hepatorenal failure present in the early postoperative period after right major hepatectomy, then the possibility of HVOO should be considered. Sequential postoperative hematological examination and assessment of hepatic perfusion by Doppler US are important for early diagnosis of acute HVOO. If hepatic vein Doppler waveforms change from triphasic to monophasic or deformed triphasic pattern with liver enzyme elevation, HVOO should be suspected. Doppler US is easy and minimally invasive for postoperative patients, and serial assessment of liver perfusion can be performed if required. In our patient, reduction of the hepatic venous flow rate was followed by decrease of the portal venous flow rate, suggesting that impairment of portal venous flow may be caused by liver congestion. When there is a high suspicion of HVOO in a patient, abdominal contrast-enhanced CT should be performed to assess dislocation of the remnant liver

and status of hepatic perfusion to make a definitive diagnosis.

Two treatment procedures for HVOO after liver resection have been reported : surgical repositioning of the remnant liver and placement of an expandable metallic stent (EMS). As indicated before, delayed intervention may lead to poor prognosis. There have been three cases of acute HVOO with massive ascites, significant hepatorenal failure, and/or cardiovascular failure that were successfully treated with emergent surgery within 24 h of liver resection<sup>(4,6)</sup>. An early surgical approach for HVOO must be considered when a patient has progressive hemodynamic instability and/or hepatorenal failure. Alternatively, there have been two cases of HVOO with slowly progressive clinical courses treated successfully by placement of EMS<sup>(7,8)</sup>. However, the long-term patency of EMS for HVOO is unknown ; therefore, indications for EMS must be carefully determined.

To prevent remnant left liver dislocation after right hepatectomy, simply fixing the falciform ligament to the anterior abdominal wall has been recommended in several articles<sup>(4,6,9)</sup> and an adverse event for this procedure has not been reported. Ogata *et al.* suggested that preservation of the main trunk of the MHV or the left triangular ligament would not significantly contribute to preventing reduction of hepatic venous flow of the remnant left liver after



right hepatectomy<sup>9)</sup>. The impairment of venous outflow could be underestimated after right liver resection. It should be noted that dislocation of the remnant left lobe can occur even if the left triangular ligament is preserved. This case is important to change our awareness of risk for HVOO after hepatectomy. At our department, we have changed to perform fixation of remnant left liver to the abdominal wall routinely in right hepatectomy.

### CONCLUSION

We report here a case with a patient who suffered from HVOO after right hepatectomy for giant HCC. Early diagnosis and treatment of this complication is important. It should be noted that rotation of the remnant left liver can potentially occur after right major hepatectomy even if the left triangular ligament is preserved. Fixation of the remnant liver in the anatomical position is an effective method for preventing acute HVOO after right hepatectomy.

### CONFLICT OF INTEREST STATEMENT :

Naoya Sato and other co-authors have no conflict of interest.

### REFERENCES

1. Sakamoto S, Egawa H, Kanazawa H, Shibata T, Miyagawa-Hayashino A, Haga H, *et al.* Hepatic venous outflow obstruction in pediatric living donor liver transplantation using left-sided lobe grafts : Kyoto University experience. *Liver Transpl*, **16** : 1207-1214, 2010.
2. Liu XL, Li FQ, Li X, Li B, Yan LN, Wei YG. Treatment of hepatic venous outflow stenosis after living donor liver transplantation by insertion of an expandable metallic stent. *Hepatobiliary Pancreat Dis Int*, **8**(4) : 424-427, 2009.
3. Sequeira FW, Weber TR, Smith WL, Careskey JM, Cairo MS. Budd-Chiari syndrome caused by hepatic torsion. *AJR Am J Roentgenol*, **137** : 393-394, 1981.
4. Pitre J, Panis Y, Belghiti J. Left hepatic vein kinking after right hepatectomy : A rare cause of acute Budd-Chiari syndrome. *Br J Surg*, **79** : 798-799, 1992.
5. Paineau J, Bourgoin S, Letessier E, Hamy A, Visset J. Syndrome de Budd-Chiari aigu post-hépatectomie. *J Chir*, **130** : 453-456, 1993.
6. Poon RT, Chan J, Fan ST. Left hepatic vein kinking after right trisegmentectomy : A potential cause of postoperative liver failure. *Hepatogastroenterology*, **45** : 508-509, 1998.
7. Benesch M, Urban C, Deutschmann H, Hausegger KA, Höllwarth M. Management of Budd-Chiari syndrome by hepatic vein stenting after extended right hepatectomy. *J Pediatr Surg*, **37** : 1640-1642, 2002.
8. Wang JK, Truty MJ, Donohue JH. Remnant torsion causing Budd-Chiari syndrome after right hepatectomy. *J Gastrointest Surg*, **14** : 910-912, 2010.
9. Ogata S, Kianmanesh R, Belghiti J. Doppler assessment after right hepatectomy confirms the need to fix the remnant left liver in the anatomical position. *Br J Surg*, **92** : 592-595, 2005.
10. Umehara M, Narumi S, Sugai M, Toyoki Y, Ishido K, Kudo D, *et al.* Hepatic venous outflow obstruction in living donor liver transplantation : balloon angioplasty or stent placement ? *Transplant Proc*, **44** : 769-771, 2012.
11. Shimahara Y, Yamaoka Y. Vascular Complications in hepatobiliary surgery Pitfalls of surgery for advanced tumors. *Jpn Vasc Surg*, **11** : 687-692, 2002.
12. Egawa H, Tanaka K, Uemoto S, Someda H, Moriyasu F, Sano K, *et al.* Relief of hepatic vein stenosis by balloon angioplasty after living-related donor liver transplantation. *Clin Transplant*, **7** : 306-311, 1993.