



Concomitant metastatic lung tumor and hamartoma

メタデータ	<p>言語: English</p> <p>出版者: The Fukushima Society of Medical Science</p> <p>公開日: 2015-07-06</p> <p>キーワード (Ja):</p> <p>キーワード (En): pulmonary hamartoma, metastatic lung tumor</p> <p>作成者: Kanno, Ryuzo, Yonechi, Atsushi, Higuchi, Mitsunori, Suzuki, Hiroyuki, Ohishi, Akio</p> <p>メールアドレス:</p> <p>所属:</p>
URL	<p>https://fmu.repo.nii.ac.jp/records/2001869</p>

[Original Article]

CONCOMITANT METASTATIC LUNG TUMOR AND HAMARTOMA

RYUZO KANNO¹⁾, ATSUSHI YONECHI²⁾, MITSUNORI HIGUCHI¹⁾,
HIROYUKI SUZUKI²⁾ and AKIO OHISHI¹⁾

¹⁾Department of Thoracic Surgery, Fukushima Red Cross Hospital, ²⁾Department of Regenerative Surgery, Fukushima Medical University School of Medicine, Fukushima, Japan

(Received November 5, 2013, accepted June 13, 2014)

Abstract : A 65-year-old woman who had undergone surgery for rectal cancer was referred to our hospital with an abnormal shadow on chest X-ray. Chest computed tomography (CT) revealed a 3-cm-diameter mass with ill-defined margins in the left lower lobe and a well-defined, 1-cm-diameter, round nodule in the right upper lobe. Transbronchial lung biopsy (TBLB) of the left lung tumor revealed metastatic adenocarcinoma originating from the rectal cancer. The patient underwent synchronous partial resection of the right upper lobe and left lower lobectomy under video-assisted thoracoscopic surgery (VATS). The pathological diagnosis of the right lung tumor was chondromatous hamartoma, and the left lung tumor was metastasis originating from the rectal cancer. The patient's postoperative course was uneventful, and she was well and free of disease 4 years after pulmonary metastasectomy.

Key words : pulmonary hamartoma, metastatic lung tumor

INTRODUCTION

The lung is one of the most frequent target organs affected by metastases in patients with malignancies, and pulmonary metastases are often found as multiple lesions. When multiple pulmonary nodules are found during postoperative follow-up of patients with malignancies, every nodule tends to be regarded as a metastasis. A rare case of metastatic lung tumor from rectal cancer with a contralateral pulmonary hamartoma is presented, and the relevant literature is discussed.

CASE REPORT

A 65-year-old woman who had undergone surgery for rectal cancer 18 months earlier (pT3N0M, stage IIA, moderately-differentiated tubular adenocarcinoma, no adjuvant chemotherapy) was referred to our hospital with an abnormal shadow on chest X-ray in the left middle lung field (Fig. 1A). Chest CT revealed a 3-cm-diameter mass with ill-defined margins in the left anterior basal segment (S8) (Fig.

1B) and a well-defined, 1-cm-diameter, round nodule in the right anterior segment (S3) (Fig. 1C). The patient underwent fiberoptic bronchoscopy. TBLB of the left S8 tumor revealed metastatic adenocarcinoma originating from the rectal cancer, but it was not possible to approach the right S3 tumor because it was too small. Physical examination and hematologic data showed no abnormalities. The serum carcinoembryonic antigen (CEA) level was not elevated (3.4 ng/mL, cut-off < 5.0 ng/mL). The left lung tumor demonstrated intense [¹⁸F]fluorodeoxy-D-glucose (FDG) uptake on positron emission tomography (PET), but the small right lung nodule, the lymph nodes, and distant organs demonstrated no abnormal uptake (Fig. 2). Although the right lung tumor had no intense FDG uptake on PET, the right lung tumor was thought to be a metastasis. It was decided that simultaneous complete resection of the tumors was possible by wedge resection of the right upper lobe and left lower lobectomy under video-assisted thoracoscopic surgery (VATS). First, the patient underwent partial resection of the right upper lobe under VATS in the left decubitus posi-

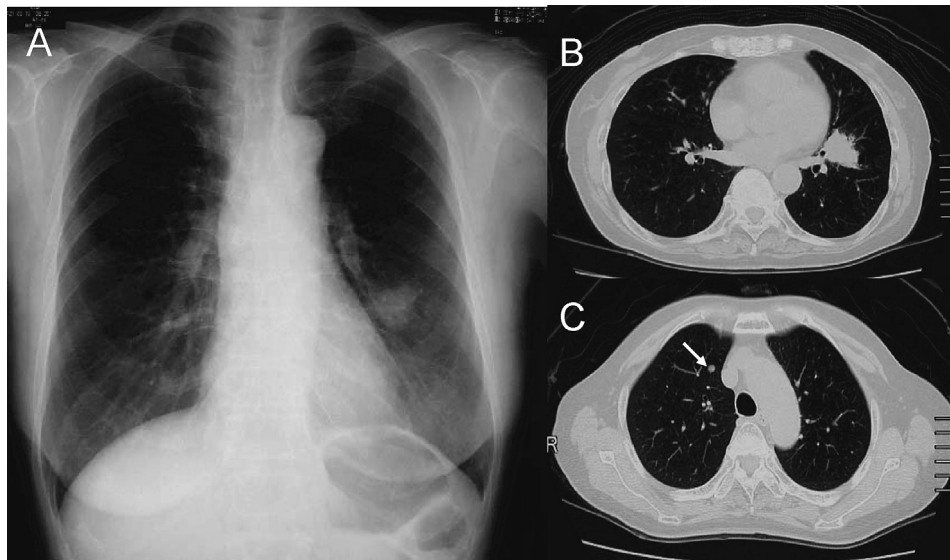


Fig. 1. **A** Chest radiograph on admission shows a tumor shadow in the left lower lung field, but the right lung tumor is unclear. **B, C** Chest computed tomography (CT) shows a well-defined, small nodule in the right S3 (*arrow*) and a 3-cm-diameter tumor with ill-defined margins in the left S8.

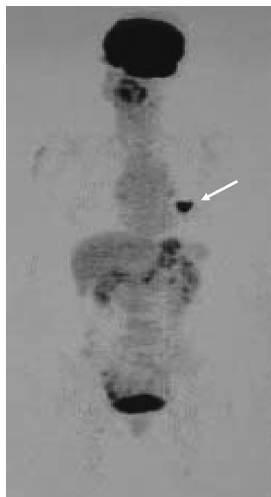

Fig. 2. Positron emission tomography image shows intense uptake of [^{18}F]fluorodeoxy-D-glucose in the left lung tumor, but no uptake in the right lung tumor (*arrow*).

tion. The intraoperative pathological diagnosis by frozen section was hamartoma. The patient then underwent left lower lobectomy with ND2a mediastinal lymph node dissection under VATS in the right decubitus position. The reason that she underwent left lower lobectomy and lymph node dissection rather than partial resection was the size (diameter > 3 cm) of the tumor. The operating time was 220 minutes, and the total blood loss was 50 g. The pathological diagnosis of the right lung tumor was chondromatous hamartoma (Fig. 3, A, B), and the left lung tumor was a moderately-differentiated tu-

bular adenocarcinoma, compatible with metastasis from the rectal cancer (Fig. 3, C, D). No regional or mediastinal lymph node metastases were detected. The patient's postoperative course was uneventful, and she was treated with 8 courses of oxaliplatin, leucovorin, and 5-fluorouracil (FOLFOX-4) as adjuvant chemotherapy for rectal cancer. The patient has been followed-up by serum CEA levels and chest X-ray every 2-3 months, thoraco-abdominal CT scans every 12 months. She was well, free of disease, 4 years after pulmonary metastasectomy.

DISCUSSION

Resection of pulmonary metastases has been generally accepted by physicians, and it has been shown to have survival benefit for the primary malignancies¹⁾. Classically, Thomford *et al.*²⁾ reported that surgery is indicated for metastatic lung tumor when there is imaging evidence that the pulmonary metastasis is limited to one lung. Recently, the indication for metastasectomy has been extended to multiple or bilateral pulmonary metastases¹⁾. When multiple pulmonary nodules are found in patients with malignancies, we tend to regard every nodule as a metastasis. However, there are a few reports of the co-existence of primary lung cancer³⁾, atypical adenomatous hyperplasia⁴⁾, or benign lesions⁵⁻⁹⁾ and metastatic lung tumor. Such conditions affect the operative procedure of pulmonary resection. Wedge resection is usually selected for metastatic lung tumors or benign lesions, but segmentectomy

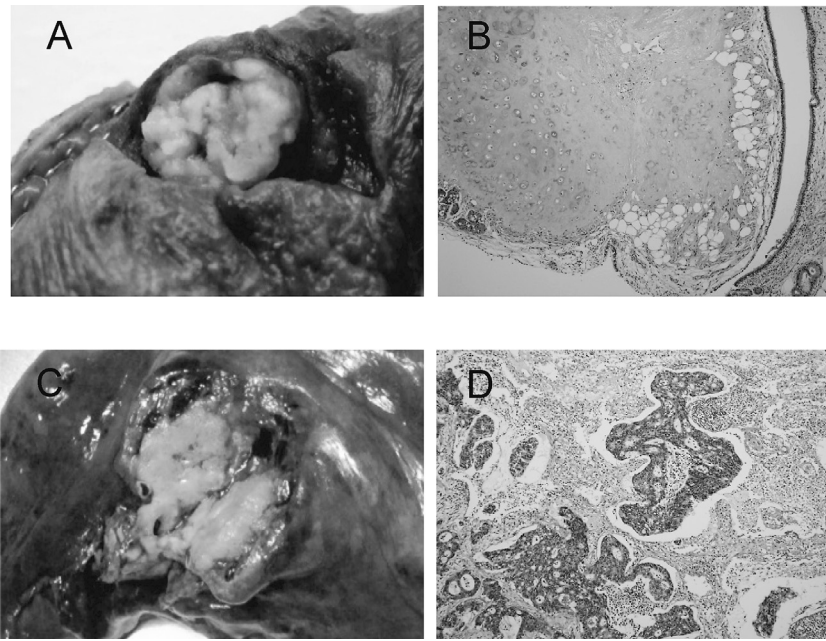


Fig. 3. **A, B** Macroscopic findings of the resected specimen of the right lung tumor show a whitish, lobulated, round tumor, and chondromatous hamartoma microscopically. **C, D** Macroscopic findings of the resected left lower lobe show a 3-cm-diameter metastatic mass with irregular margins, showing proliferation of atypical columnar epithelium and moderately-differentiated tubular adenocarcinoma, compatible with metastasis from the rectal cancer microscopically.

or lobectomy with systemic lymph node dissection is necessary for cases of concomitant primary lung cancer or metastatic lung tumor greater than 3 cm in diameter¹⁰. In the present case, a left lower lobectomy with mediastinal lymph node dissection was performed because the left metastatic tumor had a diameter greater than 3 cm.

To the best of our knowledge, the co-existence of metastatic lung tumor and hamartoma has only been reported in 9⁶⁻⁹) cases, including the present one. The clinical characteristics of 4 of these 9 cases were available for review (Table 1). In these cases, the primary organs were prostate gland, rectum, and kidney. The pulmonary lesions of all cases were found by postoperative follow-up or preoperative examinations for primary malignancies.

They were all diagnosed as having metastatic lung tumor preoperatively, and they subsequently underwent resections of the lung under VATS. Cases 1, 3, and 4 underwent synchronous resection of a hamartoma and metastatic lung tumor. In Case 2, there were multiple pulmonary hamartomas (right lower lobe) with a contralateral solitary pulmonary metastasis (left upper lobe). At first, the authors of case 2 thought that the multiple right lung lesions were also metastases, and the patient was treated with chemotherapy after resection of the solitary metastasis of the left upper lobe. However, the lesions of the right lower lobe increased in number and size. A metachronous partial resection of the contralateral multiple lesions was then performed, and the pathological diagnosis was multiple pulmonary hamarto-

Table 1. Cases of concomitant pulmonary hamartoma and metastatic lung tumor

No	Authors	Age (y) / Sex	Primary organ	Location (meta / hamartoma)	Operation under VATS (meta / hamartoma)	Follow-up (months)
1	King [6]	57 / M	Prostate	LLL solitary*	Partial	Alive (13)
2	Nishida [7]	57 / F	Rectum	LUL solitary / RLL multiple	Partial / Partial	Alive (40)
3	Tanaka [8]	63 / M	Kidney	RLL multiple / RLL solitary	Partial / Partial	NA
4	Present case	65 / F	Rectum	LLL solitary / RUL solitary	Lobectomy / Partial	Alive (48)

M, male ; F, Female ; LLL, left lower lobe ; LUL, left upper lobe ; RLL, right lower lobe ; RUL, right upper lobe ; Partial, partial resection, NA, not available ; *Microscopically clusters of metastatic cells were found in a small hamartoma of LLL.

ma.

As described above, when multiple pulmonary lesions are found in patients with malignancies, the differential diagnosis of the individual pulmonary lesions is important. Bronchoscopic biopsy is useful for pathological diagnosis of pulmonary lesions but difficult for multiple small lesions. PET is a mandatory examination for detecting distant metastases and useful for evaluation of pulmonary lesions¹¹⁾ in patients with malignancies. In the present case, the right pulmonary nodule should have been followed-up given the negative PET findings.

In patients who have multiple resectable pulmonary lesions with malignancies, a definitive preoperative diagnosis of each pulmonary lesion should be attempted, and the appropriate operative procedure for pulmonary resection must be chosen. Complete resection of multiple pulmonary lesions based on the exact preoperative diagnoses of individual lesions provides a chance for long-term survival in patients with malignancies.

CONCLUSION

The possibility of the co-existence of lesions other than metastatic lung tumors, such as pulmonary hamartoma, should be considered when multiple pulmonary lesions are found in patients with malignancies.

CONFLICT OF INTEREST

The authors have declared that no conflict of interest exists.

REFERENCES

1. Hornbech K, Ravn J, Steinbrüchel DA. Current status of pulmonary metastasectomy. *Eur J Cardiothorac Surg*, **39** : 955-962, 2011.
2. Thomford NR, Woolner LB, Clagett OT, Minn R. The surgical treatment of metastatic tumors in the lungs. *J Thorac Cardiovasc Surg*, **49** : 357-363, 1965.
3. Kawano R, Hata E, Ikeda S, Yokota T, Tagawa K, Sato F. Clinicopathological study of patients with coexistence of pulmonary hamartoma and primary lung cancer. *Jpn J Chest Surg*, **21** : 526-530, 2007.
4. Kodama K, Higashiyama M, Takami K, Higaki N, Okada K, Araki N. Synchronous pulmonary atypical adenomatous hyperplasia and metastatic osteosarcoma in a young female. *Jpn J Thorac Cardiovasc Surg*, **52** : 357-359, 2004.
5. Czeyda-Pommersheim F, Sulyok Z, Esik O, Bodrogi I, Péter I, Köves I. Different histological findings in two specimens from pulmonary metastasectomy in the same patient. *Orv Hetil*, **145** : 139-145, 2004.
6. King TC, Myers J. Isolated metastasis to a pulmonary hamartoma. *Am J Surg Pathol*, **19** : 472-475, 1995.
7. Nishida T, Akizuki K, Minami K, Nishiyama N. Multiple pulmonary hamartomas masquerading as metastatic lung tumors : A case report. *JJLC*, **47** : 37-40, 2007.
8. Tanaka Y, Oura S, Yoshimasu T, Ota F, Hirai Y, Okamura Y. A case of metastatic lung cancer from renal cell carcinoma complicated with hamartoma in the same segment. *Jpn J Chest Surg*, **27** : 79-83, 2012.
9. Gjevra JA, Myers JL, Prakash UBS. Pulmonary Hamartomas. *Mayo Clin Proc*, **71** : 14-20, 1996.
10. Shirouzu K, Isomoto H, Hayashi A, Nagamatsu Y, Kakegawa T. Surgical treatment for patients with pulmonary metastases after resection of primary colorectal carcinoma. *Cancer*, **76** : 393-398, 1995.
11. Bamba Y, Itabashi M, Kameoka S. Value of PET/CT imaging for diagnosing pulmonary metastasis of colorectal cancer. *Hepatogastroenterology*, **112** : 1972-1974, 2011.