



Tactile sensor is useful for estimating liver hardness and liver fibrosis compared with ultrasonography and computed tomography

メタデータ	<p>言語: English</p> <p>出版者: The Fukushima Society of Medical Science</p> <p>公開日: 2015-07-06</p> <p>キーワード (Ja):</p> <p>キーワード (En): Liver fibrosis, tactile sensor, ultrasonography, computed tomography</p> <p>作成者: Suzuki, Satoshi, Watanabe, Yohei, Yazawa, Takashi, Ishigame, Teruhide, Sassa, Motoki, Monma, Tomoyuki, Takawa, Tadashi, Kumamoto, Kensuke, Nakamura, Izumi, Ohoki, Shinji, Hatakeyama, Yuichi, Sakuma, Hiroshi, Ono, Toshiyuki, Omata, Sadao, Takenoshita, Seiichi</p> <p>メールアドレス:</p> <p>所属:</p>
URL	<p>https://fmu.repo.nii.ac.jp/records/2001867</p>

[Original Article]

TACTILE SENSOR IS USEFUL FOR ESTIMATING LIVER HARDNESS AND LIVER FIBROSIS COMPARED WITH ULTRASONOGRAPHY AND COMPUTED TOMOGRAPHY

SATOSHI SUZUKI¹⁾, YOHEI WATANABE¹⁾, TAKASHI YAZAWA¹⁾, TERUhide ISHIGAME¹⁾,
MOTOKI SASSA¹⁾, TOMOYUKI MONMA¹⁾, TADASHI TAKAWA¹⁾, KENSUKE KUMAMOTO¹⁾,
IZUMI NAKAMURA¹⁾, SHINJI OHOKI¹⁾, YUICHI HATAKEYAMA²⁾, HIROSHI SAKUMA³⁾,
TOSHIYUKI ONO³⁾, SADA OOMATA⁴⁾ and SEIICHI TAKENOSHITA¹⁾

¹⁾Department of Organ Regulatory Surgery, Fukushima Medical University, Fukushima, Japan, ²⁾Japan Community Health care Organization Nihonmatsu Hospital, Nihonmatsu, Japan, ³⁾Masu Memorial Hospital, Nihonmatsu, Japan, ⁴⁾Department of Electrical and Electronic Engineering, College of Engineering, Nihon University, Koriyama, Japan

(Received March 14, 2013, accepted June 11, 2014)

Abstract : Background/Aims : We examined whether conventional ultrasonography (US) and computed tomography (CT) were useful to evaluate liver hardness and hepatic fibrosis by comparing the results with those obtained by a tactile sensor using rats with liver fibrosis.

Methodology : We used 44 Wistar rats in which liver fibrosis was induced by intraperitoneal administration of thioacetamide. The CT and US values of each liver were measured before laparotomy. After laparotomy, a tactile sensor was used to measure liver hardness. We prepared Azan stained sections of each excised liver specimen and calculated the degree of liver fibrosis (HFI : hepatic fibrosis index) by computed color image analysis.

Results : The stiffness values and HFI showed a positive correlation ($r=0.690$, $p<0.001$), as did the tactile values and HFI ($r=0.709$, $p<0.001$).

In addition, the stiffness and tactile values correlated positively with each other ($r=0.814$, $p<0.001$). There was no correlation between the CT values and HFI, as well as no correlation between the US values and HFI.

Conclusion : We confirmed that it was difficult to evaluate liver hardness and HFI by CT or US examination, and considered that, at present, a tactile sensor is useful method for evaluating HFI.

Key words : Liver fibrosis, tactile sensor, ultrasonography, computed tomography.

INTRODUCTION

Recently developed and refined treatments for hepatocellular carcinoma (HCC) have improved survival rates in HCC patients¹⁻⁵⁾. While surgical resection still is the first therapeutic option to consider in patients with HCC⁶⁾, surgery should be restricted to small tumors in patients with well-preserved liver function. Because HCC is related to hepatitis C virus infection in about 70% of patients in Japan, most HCC patients have some degree of liver dysfunction

caused by chronic hepatitis or cirrhosis⁶⁾. A number of methods have been developed for assessing liver function, particularly hepatic functional reserve⁷⁻⁹⁾. In our hospital, these estimates have been helpful in choosing the type of operation, although we still occasionally encounter postoperative hepatic decompensation. Preoperative prediction of hepatic regenerative activity might determine the ability of a cirrhotic liver to tolerate hepatectomy more accurately¹⁰⁾, however, a method has yet to be established.

Corresponding author : Satoshi Suzuki E-mail : satop@fmu.ac.jp
<https://www.jstage.jst.go.jp/browse/fms> <http://www.fmu.ac.jp/home/lib/F-igaku/>

Hatakeyama *et al.* reported that quantitation of hepatic fibrosis by automated image analysis could enable the prediction of postoperative hepatic regenerative activity after cirrhotic liver resection¹¹⁾. However, this method is limited by the need to obtain a large liver biopsy specimen. Ono *et al.* reported that a tactile sensor could reliably measure a factor that limits regenerative ability¹²⁾, although this method can only be used intraoperatively.

In the present study, we compared conventional methods, ultrasonography (US) and computed tomography (CT), with a tactile sensor for the ability to accurately measure hepatic fibrosis in a rat model of liver fibrosis.

METHODOLOGY

Animals. Forty-four 5-week-old Wistar rats were housed at 26°C in individual cages with a 12h light-dark cycle at Aizu Central Animal Hospital. All animals were given water and rat chow (M.F.[®], Oriental Yeast, Tokyo, Japan) ad libitum until the day before surgery.

Induction of liver fibrosis. Liver fibrosis (chronic hepatitis or cirrhosis) was induced by intraperitoneal administration of thioacetamide (TAA, 200 mg/kg, 3 times weekly) for 8 or 10 weeks in 31 rats. Thirteen healthy control rats were given saline instead of TAA according to the same schedule. We designated the 13 control rats as group A, 14 rats given TAA for 8 weeks as group B, and 17 rats given TAA for 10 weeks as group C.

CT. Before laparotomy, each liver was scanned at intervals of 1 mm with the Subrina CT system (SHIMADZU, Kyoto, Japan). We measured CT values at 5 points in each liver, and calculated a mean¹³⁾.

US. Before laparotomy, each liver was examined with the SSD-5500 US system (ALOKA, Tokyo, Japan). Ultrasonic diagnostic equipment creates an image by processing acoustic signals returning from tissues using a filter among others. It is thought that unprocessed acoustic signals have a possibility to represent tissue properties¹⁴⁾. Therefore, we obtained raw resonance frequencies and defined as a US value.

Surgery. Laparotomy was performed under Somnopentyl (40 mg/kg) anesthesia, and liver hardness and fibrosis was evaluated in the following manners.

Quantification of liver hardness. Tissue stiffness values are calculated from the stress-strain behavior based on the degree of depression and the

Stiffness value...Conventional parameter of hardness.

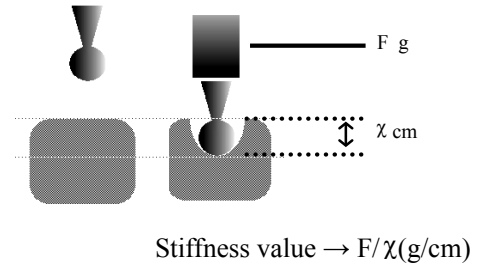


Fig. 1. Stiffness value.

Tissue stiffness value is the conventional parameter of hardness. It is calculated from the stress-strain behavior based on the degree of depression and the counter weight.

counter weight (Fig. 1). The tactile sensor (Department of Electrical and Electronic Engineering, College of Engineering, Nihon University, Koriyama, Japan), which was developed to estimate liver hardness, consists of a displacement transducer to produce a stress-strain curve of soft tissue, and a piezoelectric tactile sensor to acoustically characterize the object. Tactile values were obtained in the following manner. In general, when a vibrating rod touches an object, its resonance frequency shifts due to the physical properties of the material. The tactile sensor system is based on the contact compliance^{15,16)}. The sensor probe consists of a piezoelectric element and a vibration pickup element. When an alternating voltage is applied across its electrode,

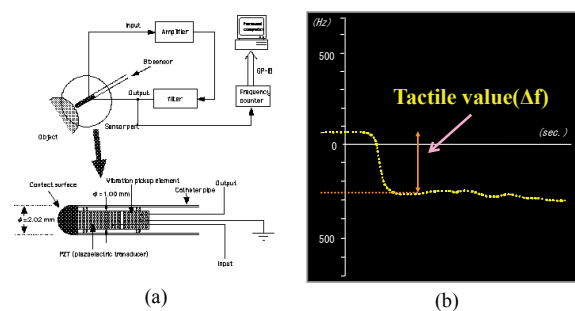


Fig. 2. The tactile sensor system.

(a) The system based on the contact compliance method. The sensor probe consists of a piezoelectric element and a vibration sensor. A 3-mm diameter nylon hemisphere is attached to the free end of the piezoelectric element.

(b) Object hardness is measured by the tactile sensor (the tactile values), and is expressed as the change in frequency, $\Delta f = f_x - f_0$, which is the difference between the resonance frequency of the points to which the sensor is applied (f_x), and the non-contact resonance frequency of the tactile sensor (f_0).

the feedback circuit system is oscillated at the resonance frequency of the piezoelectric element (Fig. 2). When the probe is pressed against an object, the resonance frequency varies with the acoustic impedance of the object. Object hardness is measured by the tactile sensor, and the output or change in frequency is represented as a tactile value. ($\Delta f = f_x - f_0$). Specifically, a tactile value refers to the difference between the resonance frequency at the point to which the sensor is applied (f_x) and the non-contact resonance frequency of the tactile sensor (f_0). At laparotomy, we measured liver hardness at 3 points on each liver using the parameters of stiffness and regarded the averaged value of the 3 points as a tactile value.

Histopathologic study. Representative blocks from each excised liver specimen were prepared. After routine paraffin-wax processing, sections were stained with hematoxylin and eosin for light microscopic assessment of liver damage. A hepatic fibrosis index (HFI) then was calculated as follows to quantify the degree of liver fibrosis. Azan-stained sections were prepared, in which fibrotic tissue was stained blue. Percent fibrosis (relative extent of the blue area) was determined by computed color image analysis (Image-Pro Plus version 4.5, Media Cybernetics., Silver Spring, MD, USA). For each rat, the area of fibrotic tissue was measured in 5 randomly selected fields, and the average was expressed as a percentage representing the HFI⁽¹⁾ (Fig. 3).

Statistical analysis. Results were expressed as the mean followed by range. Differences in means between the two groups were assessed by the Student's *t* test, and correlations between variables were analyzed using Pearson's correlation coefficient. *P* values less than 0.05 were considered significant.

This study was approved by the Ethics Review Committee for Animal Experimentation of Fukushi-

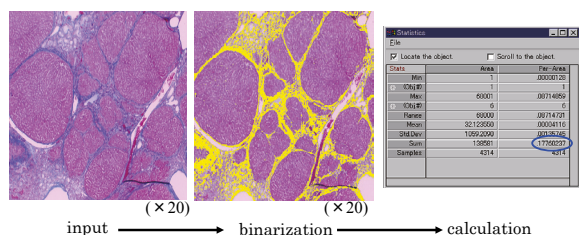


Fig. 3. Hepatic fibrosis index.

Azan stained images were transferred to a PC and processed by binarization. Hepatic fibrosis index was then calculated by computed color image analysis.

ma Medical University.

RESULTS

Histopathologic findings. The rats in group A had normal liver histology on light microscopy and an HFI of 0.39% (0.14% to 0.74%). On the other hand, the rats treated with TAA exhibited varying degrees of hepatic fibrosis, showing more extensive hepatic fibrosis than any other healthy rats. The group B rats showed the histologic appearance of chronic hepatitis and an HFI of 7.74% (1.86% to 16.10%). The group C rats showed features of macronodular cirrhosis and an HFI of 11.80% (3.80% to 19.98%) (Fig. 4). The mean HFI was significantly different between the groups ($p < 0.005$ between the groups A and B, $p < 0.005$ between the groups A and C, and $p = 0.012$ between the groups B and C) (Fig. 5).

Liver hardness. Group A had a mean stiffness value of 0.35 g/cm (0.26 to 0.51), group B had a mean value of 0.42 g/cm (0.29 to 0.59), and group C

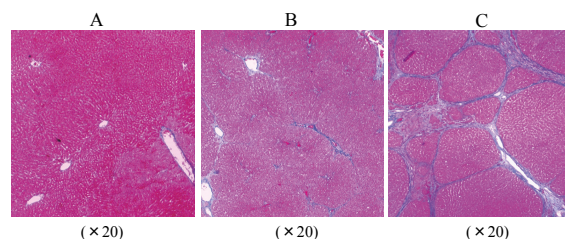


Fig. 4. Azan staining of each group.

(A) Group A had normal liver histology. (B) Group B showed the histologic appearance of chronic hepatitis. (C) Group C showed the features of macronodular cirrhosis.

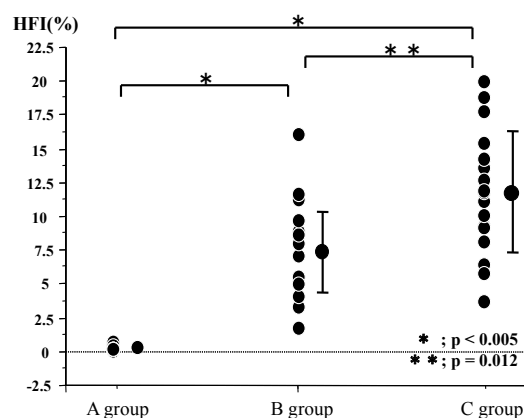


Fig. 5. HFI of each group.

There was a significant difference in HFI between each group ($p < 0.005$ between groups A and B, and between groups A and C. $p = 0.012$ between groups B and C).

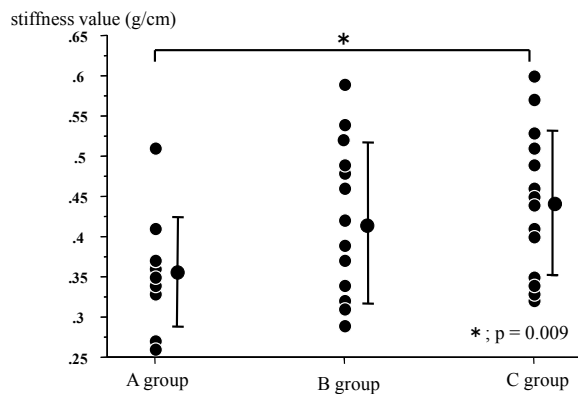


Fig. 6. Stiffness value of each group.

There was a significant difference in stiffness value between groups A and C ($p=0.009$).

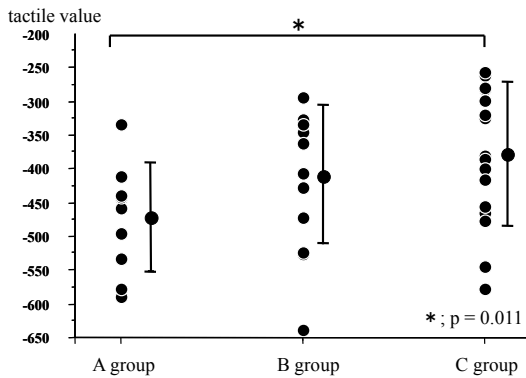


Fig. 7. Tactile value of each group.

The tactile value showed a significant difference between groups A group and C ($p=0.011$).

had a mean value of 0.44 g/cm (0.32 to 0.60). The mean stiffness value was significantly different between the groups A and C ($p=0.009$) (Fig. 6). Regarding tactile values, group A had a mean value of -473.5 (-589.2 to -332.4), group B had a mean value of -404.6 (-638.9 to -294.4), while group C had a mean value of -375.4 (-578.0 to -255.9). The mean tactile values differed significantly between the groups A and C ($p=0.011$) (Fig. 7).

CT value. Group A had a mean CT value of 76.53 HU (70.34 to 81.26), while group B had a mean value of 74.76 HU (66.38 to 83.40) and group C had a mean value of 72.51 HU (66.40 to 81.52). The mean CT value differed significantly between the groups A and C ($p=0.015$).

US value. Group A had a mean US value of 16.41 (6.92 to 23.71), while group B had a mean value of 14.99 (8.35 to 25.09) and group C had a mean value of 16.62 (5.49 to 27.88). The mean US value did not differ significantly between the groups.

Liver hardness and HFI. Stiffness values and the HFI showed a positive correlation ($r=0.690$,

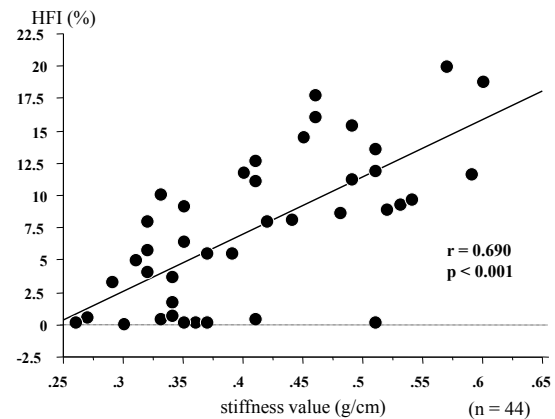


Fig. 8. Correlation between stiffness values and HFI.

The stiffness values and the HFI showed a positive correlation ($r=0.690$, $p<0.001$).

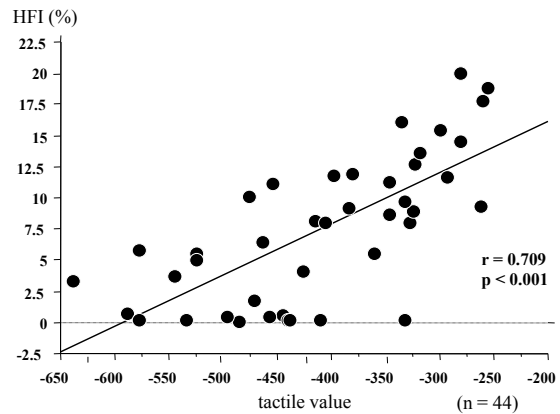


Fig. 9. Correlation between tactile values and HFI.

The tactile values and the HFI showed a positive correlation ($r=0.709$, $p<0.001$).

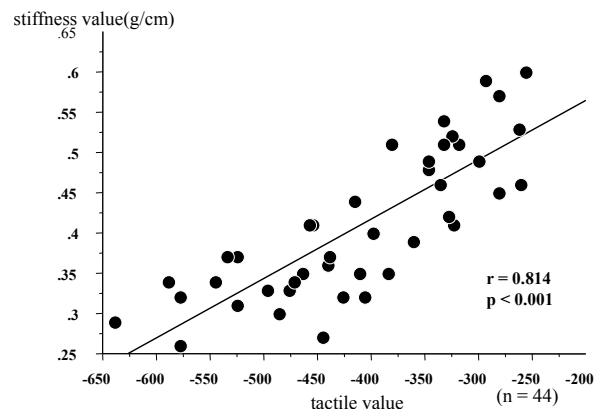


Fig. 10 Correlation between stiffness values and tactile values.

The stiffness values and the tactile values showed a positive correlation ($r=0.814$, $p<0.001$).

$p<0.001$) (Fig. 8), as did the tactile values and HFI ($r=0.709$, $p<0.001$) (Fig. 9).

In addition, stiffness and tactile values correlated positively with each other ($r=0.814$, $p<0.001$)

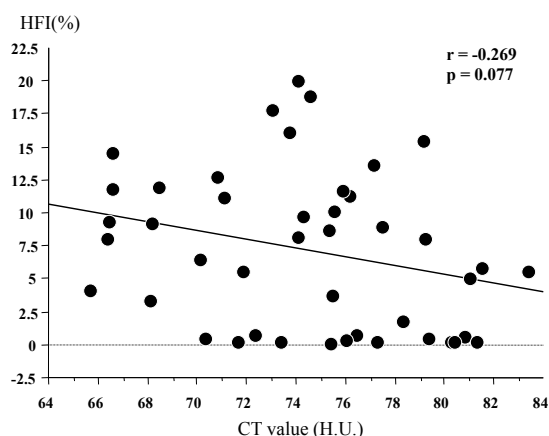


Fig. 11. Correlation between CT values and HFI.
There was no correlation between the CT values and the HFI.

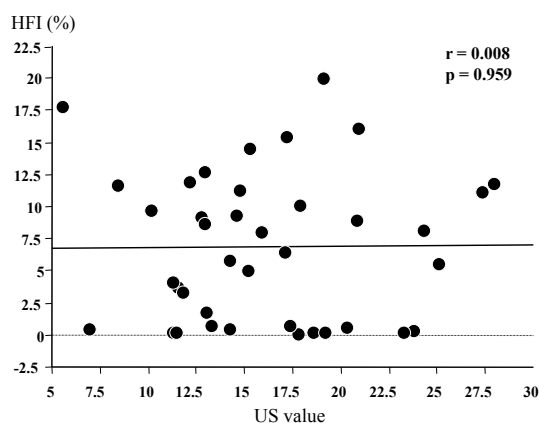


Fig. 12. Correlation between US values and HFI.
There was no correlation between the US values and the HFI.

(Fig. 10).

CT value and liver hardness. No correlation was evident between the CT values and either stiffness values or tactile values.

CT value and HFI. No correlation was found between the CT values and HFI (Fig. 11).

US value and liver hardness. No correlation was demonstrated between the US values and either the stiffness values or tactile values.

US value and HFI. No correlation was noted between the US values and HFI (Fig. 12).

DISCUSSION

Liver resection is most effective in various therapies for patients with HCC. However, surgical treatment of cirrhotic patients is associated with considerable risk⁶. Although a number of methods for assessing liver function, especially hepatic func-

tional reserve, have been developed⁷⁻⁹ we occasionally encounter liver failure after liver resection even if preoperative estimation is performed using these methods. Therefore, we consider that the assessments of other parameters such as hepatic regeneration are needed in addition to hepatic functional reserve when planning surgery.

It has been reported that transforming growth factor- β (TGF- β), which promotes liver fibrosis and suppresses the growth of hepatocytes, is related to the development of liver cirrhosis¹⁷. Hatakeyama *et al.* focused on the degree of liver fibrosis in which TGF- β played a key role to estimate the capacity of the cirrhotic liver to tolerate hepatectomy, and performed an experiment using rats with liver cirrhosis. They found that the HFI, which was calculated by the Azan-staining method and computed color image analysis, predicted liver regenerative activity¹¹. However, the limitation of this method is the need to obtain a large block of liver by biopsy. Hatakeyama *et al.* investigated the quantification of liver hardness of cirrhotic rats using a new tactile sensor. The results indicated that it was possible to measure liver hardness (tactile values) rapidly and accurately with the sensor, and the tactile values showed a highly significant correlation with HFI and liver regenerative activity^{12,18}. Furthermore, Hatakeyama *et al.* reported that tactile values had a highly significant correlation with HFI in clinical cases¹⁹. However, it is impossible to measure liver hardness before operation.

CT and US are used for the examination of the liver in general. CT images reflect the differences of radiolucency between tissues²⁰ and US images reflect the differences of acoustic impedance between tissues¹⁴. Radiolucency and acoustic impedance are considered to be related to tissue properties. Therefore, we investigated the usefulness of CT and US for evaluating liver hardness. In this study, the stiffness values and HFI showed a positive correlation, as did the tactile values and HFI. This therefore reconfirmed that the tactile sensor was useful for the measurement of HFI which had highly significant correlation with hepatic regeneration activity.

In this study, we used US values as a parameter of acoustic impedance. Ultrasonic diagnostic equipment creates an image by processing acoustic signals returning from tissues using a filter among others. It is thought that unprocessed acoustic signals have a possibility to represent tissue properties. In this study, therefore, we obtained raw resonance frequencies as a quantitative value of US. However,

there was no correlation between the US values and HFI. This study did not demonstrate that US was useful for evaluating hepatic fibrosis. There is no report that evaluated hardness by US value to date. We consider that it is difficult to evaluate the liver hardness by only US value. So, we will try the development of new theory system.

We used CT values as a parameter of radiolucency. The CT values were obtained by digitizing the radiolucency of tissues and were considered to be dependent on the properties of tissues. In the pilot study, CT values and stiffness values showed a positive correlation in various tissues. However, in this study, there was no significant correlation. The program used by the CT device may have affected the CT values. In other words, emphasis on the outline for making images clearer might have influenced the results of this study. We might have gained different results had we had raw CT values. Regardless, we consider that, at present, it is impossible to evaluate liver hardness and HFI with CT and US values alone.

CONCLUSION

We reconfirmed the usefulness of a tactile sensor for the measurement of HFI. In addition, we confirmed that it was difficult to evaluate liver hardness and HFI by using CT or US examination. We consider that a tactile sensor is useful method to date to effectively evaluate HFI.

REFERENCES

1. Matsui O, Kadoya M, Yoshikawa J, *et al.* Small hepatocellular carcinoma : Treatment with subsegmental transcatheter arterial embolization. *Radiology*, **188** : 79-83, 1993.
2. Livraghi T, Bolondi L, Lazzaroni S, *et al.* Percutaneous ethanol injection in the treatment of hepatocellular carcinoma in cirrhosis : A study on 207 patients. *Cancer*, **69** : 925-929, 1992.
3. Ando E, Yamashita F, Tanaka M, *et al.* A novel chemotherapy for advanced hepatocellular carcinoma with tumor thrombosis of the main trunk of the portal vein. *Cancer*, **79** : 1890-1896, 1997.
4. Seki T, Wakabayashi M, Nakagawa T, *et al.* Ultrasonically guided percutaneous microwave coagulation therapy for small hepatocellular carcinoma. *Cancer*, **74** : 817-825, 1994.
5. Rossi S, Fornari F, Buscarini L. Percutaneous ultrasound-guided radiofrequency treatment of small hepatocellular carcinoma. *J Intervent Radiol*, **8** : 97-103, 1993.
6. Arai S, Okamoto E, Imamura M. Registries in Japan : current status of hepatocellular carcinoma in Japan. Liver Cancer Study Group of Japan. *Seminars in Surgical Oncology*, **12** : 204-211, 1996.
7. Mizumoto R, Noguchi T. Selection of treatment for hepatocellular carcinoma with preoperative estimation of hepatic functional reserve. *Shokakibyō Seminar (Gastroenterological Disease Seminar)*, **26** : 6-18, 1987. (in Japanese)
8. Yamanaka N, Okamoto E, Kuwata K, Tanaka N. A multiple regression equation for prediction of post-hepatectomy liver failure. *Ann Surg*, **200** : 658-663, 1984.
9. Mori K, Ozawa K, Yamamoto Y. Response of hepatic mitochondrial redox state to oral glucose load-redox tolerance test as a new predictor of surgical risk in hepatectomy. *Ann Surg*, **211** : 438-446, 1990.
10. MacIntosh EL, Gauthier T, Pettigrew NM, *et al.* Hepatic fibrosis as a predictor of hepatic regenerative activity after partial hepatectomy in rat. *Hepatology*, **17**(2) : 307-309, 1993.
11. Hatakeyama Y, Ono T, Abe R. The grade of hepatic fibrosis as a predictor of regeneration activity after partial hepatectomy to liver cirrhosis in the rat. *Nihon Shokakigeka Gakkai Zasshi (Jpn J Gastroenterol Surg)*, **29** : 691-698, 1996. (in Japanese)
12. Ono T, Hatakeyama Y, Hara K, *et al.* A trial evaluation of hepatic fibrosis using new tactile sensor. *Nihon Shokakigeka Gakkai Zasshi (Jpn J Gastroenterol Surg)*, **30** : 1720-1724, 1997. (in Japanese)
13. Mahadevappa Mahesh. MDCT physics : The Basics-technology, Image Quality and Radiation Dose, 62, 2009.
14. The Japan Society of Ultrasonics in Medicine. Current Textbook of Ultrasonics in Medicine, **1** : 2-7, 2000.
15. Omata S. Measurement of the hardness of a soft material with a piezoelectric vibrometer and their analysis. *Jpn J Med Electron Biol Eng*, **28** : 1-8, 1990.
16. Omata S. New tactile sensor like the human hand and its applications. *Sensors and Actuators A*, **35** : 9-15, 1992.
17. Bissell DM, Roulot D, George J. Transforming growth factor beta and the liver. *Hepatology*, **34** : 859-867, 2001.
18. Hatakeyama Y, Ono T, Sato N, *et al.* Usefulness of the tactile sensor for estimating the degree of liver fibrosis and the DNA synthesis activity of remnant liver cells after partial hepatectomy. *Fukushima J Med Sci*, **48** : 93-101, 2002.
19. Hatakeyama Y, Sakuma H, Kakinuma Y, *et al.* The evaluation of hepatic fibrosis by Doppler ultrasonography and the tactile sensor. *Nihon Shokaki-*

- geka Gakkai Zasshi (Jpn J Gastroenterol Surg), **33** : 156-162, 2000. (in Japanese)
20. Mahadevappa Mahesh. MDCT physics : The Basics-technology, Image Quality and Radiation Dose, 5-16, 2009.