



Successful endovascular treatment of chronic total occlusion of superficial femoral artery using retrograde approach from deep femoral artery

メタデータ	<p>言語: English</p> <p>出版者: The Fukushima Society of Medical Science</p> <p>公開日: 2014-09-19</p> <p>キーワード (Ja):</p> <p>キーワード (En): chronic total occlusion (CTO), endovascular treatment (EVT), retrograde approach, superficial femoral artery (SFA)</p> <p>作成者: Nakamura, Yuichi, Komatsu, Nobuo, Masuda, Atsuro, Kunii, Hiroyuki, Takeda, Hiroto, Takeishi, Yasuchika</p> <p>メールアドレス:</p> <p>所属:</p>
URL	https://fmu.repo.nii.ac.jp/records/2001855

[Original Article]

SUCCESSFUL ENDOVASCULAR TREATMENT OF CHRONIC TOTAL OCCLUSION OF SUPERFICIAL FEMORAL ARTERY USING RETROGRADE APPROACH FROM DEEP FEMORAL ARTERY

YUICHI NAKAMURA^{1,2)}, NOBUO KOMATSU²⁾, ATSURO MASUDA^{1,2)},
HIROYUKI KUNII¹⁾, HIROTO TAKEDA²⁾ and YASUCHIKA TAKEISHI¹⁾

¹⁾Department of Cardiology and Hematology, Fukushima Medical University, ²⁾Department of Cardiology, Ohta Nishinouchi Hospital

(Received October 11, 2013, accepted March 18, 2014)

Abstract : An 82 years-old man with intermittent claudication was admitted to our hospital. Computed tomography angiography showed his right superficial femoral artery (SFA) was chronic total occlusion (CTO), and we performed endovascular treatment (EVT). We advanced a guide-wire by contralateral transfemoral approach, but guide-wires could not penetrate the occluded SFA lesion antegradely. Thus, we tried to approach the CTO lesion retrogradely. A guide-wire passed through the collateral channel from deep femoral artery (DFA) to distal SFA. With a reverse-controlled antegrade and retrograde subintimal tracking (CART) technique, we were able to pass the CTO lesion. Finally two SMART stents were implanted. We experienced a case in which retrograde approach via collateral channel from DFA was effective to CTO of SFA.

Key words : chronic total occlusion (CTO), endovascular treatment (EVT), retrograde approach, superficial femoral artery (SFA)

INTRODUCTION

The initial success rate of endovascular treatment (EVT) for chronic total occlusion (CTO) of superficial femoral artery (SFA) was reported 81-94%¹⁾. On the other hand, success rate for iliac artery was higher than that of SFA. In EVT for CTO of iliac artery, we can choose more methods to approach the lesion than CTO of SFA. Retrograde transpopliteal approach in EVT for CTO of SFA needs a distal retrograde puncture in a prone or supine position, which sometimes accompanied by injuries of vein or nerves. We report a case of successful EVT for CTO of SFA using retrograde approach via collateral channel from deep femoral artery (DFA).

CASE REPORT

An 82 years old man with a history of hyperten-

sion and dyslipidemia was admitted to our hospital complaining intermittent claudication of bilateral lower limbs within 200 meter, a Rutherford classification of grade I-2. He was given cilostazole and rosuvastatin. His right ankle brachial index (ABI) was 0.76 and left ABI was 0.55. Computed tomography (CT) angiography demonstrated that his right SFA and left femoropopliteal artery were CTO, and collateral channels developed from right DFA to SFA distal (Fig. 1). We could not perform physical therapy under close monitoring, and his symptom was not improved by medications. We discussed with cardiovascular surgeons regarding indication of revascularization therapy. Comparing femoro-popliteal (F-P) bypass using the vascular graft, it has been reported that the initial success rate and secondary patency rate of EVT are close to F-P bypass¹⁾. Furthermore, the overall complication is higher in the F-P bypass than in EVT in claudication patients with Trans-Atlantic Inter-Society Consensus

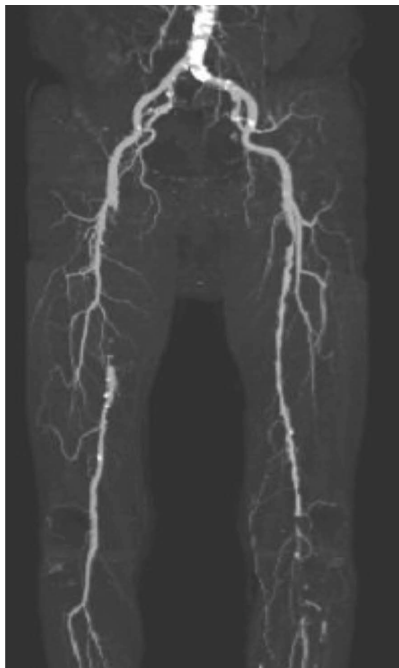

Fig. 1. Computed tomography (CT) angiography of bi-lateral lower limb arteries.

CT angiography showed that right superficial femoral artery (SFA) and left femoropopliteal artery were chronic total occlusion (CTO), and collateral channels developed from right deep femoral artery (DFA) to SFA distal.

(TASC)-II C and D¹⁾. Therefore, first we decided to perform EVT of left femoropopliteal artery. Angiography showed total occlusion of the proximal right SFA and left femoropopliteal artery in similar to CT findings. After crossing guide wire, we performed plain balloon angioplasty (POBA) with JACKAL RX 2.0×80 mm (KANEKA Medix, Osaka, Japan) in the distal-portion of left SFA to popliteal artery. We enlarged size of the balloon with 3.0 mm and 5.0 mm. Because stent placed at popliteal artery was easy to fracture and enough luminal diameter was provided without flow limitation, we finished procedure. The final angiographic result showed well expanded left femoropopliteal artery.

Two weeks later, we performed EVT to CTO of right SFA. A 6Fr Sheath Less PV ST 90 cm (Asahi Intec, Nagoya, Japan) was inserted from the left femoral artery into right SFA. Angiography showed total occlusion in the proximal portion of right SFA and collateral channels developed from DFA to distal portion of CTO of SFA (Fig. 2). A 0.014 in Agosal Xs (300 cm, tip road 0.8 g) guide wire (Asahi Intec, Nagoya, Japan) with Sniper2 μ 7 (150 cm) micro catheter (TERUMO, Tokyo, Japan) could not penetrate the CTO site antegradely. We used 0.014 in Xtreme PV (tip road 1.0 g) guide wire (Asahi Intec,

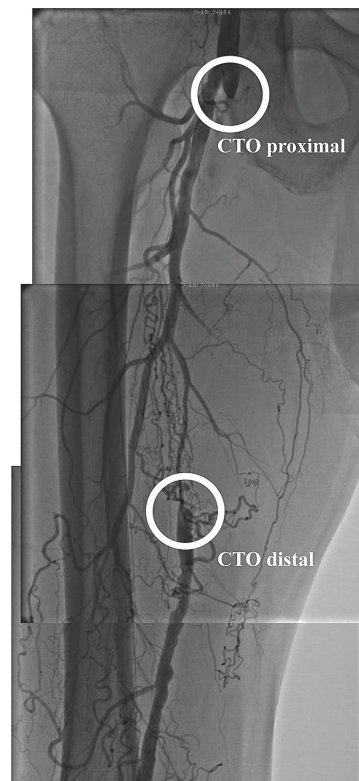


Fig. 2. Angiography of right superficial femoral artery (SFA).

Angiography showed total occlusion in the proximal portion of right SFA and collateral channels developed from deep femoral artery (DFA) to distal portion of chronic total occlusion (CTO) of SFA.

Nagoya, Japan) and 0.018 in Astato (tip road 30 g) guide wire (Asahi Intec, Nagoya, Japan), but the guide-wires did not reach distal true lumen. Since the antegrade injection demonstrated some collateral channels from DFA to the distal of CTO (Fig. 3A), we attempted to the trans-collateral approach via DFA channel to the distal CTO site retrogradely. Cruise (tip road 1.0 g) guide wire (Asahi Intec, Nagoya, Japan) with Sniper2 μ 7 micro catheter passed through the collateral channel and manipulated into the distal of CTO. We approached antegradely with Astato guide wire into the proximal cap of the occlusion. We performed antegrade balloon dilation with Jackal RX 2.0×20 mm (KANEKA Medix, Osaka, Japan) in the proximal cap of the occlusion. With a reverse controlled antegrade and retrograde subintimal tracking (CART) technique, the retrograde Cruise guide wire advanced into the mid CTO site. We started antegrade wiring again. Then, the antegrade Astato guide wire came into the mid CTO site, we performed balloon dilation with Jackal RX 2.0×20 mm antegradely, the retrograde Cruise wire was then advanced through the subinti-

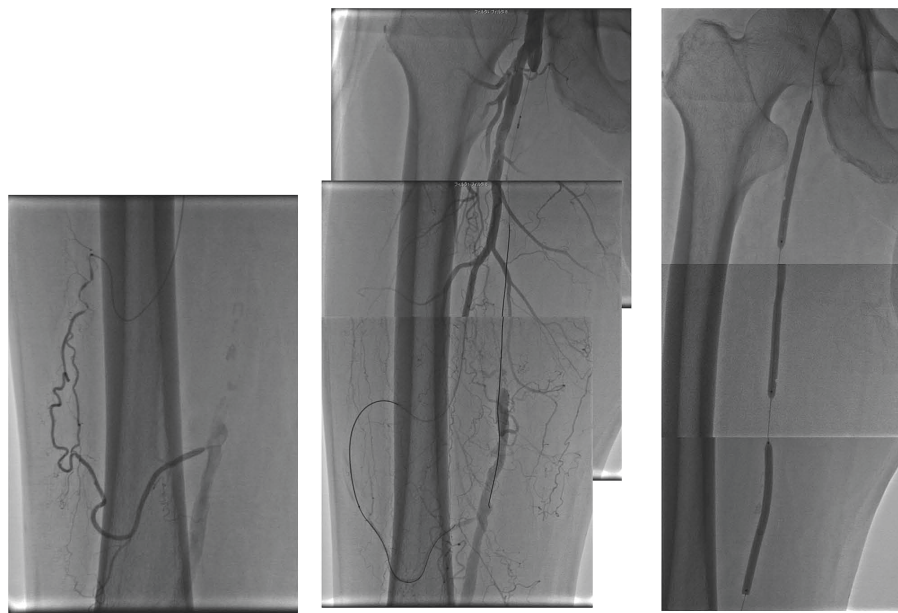


Fig. 3A

Fig. 3B

Fig. 3C

Fig. 3. endovascular treatment (EVT) to chronic total occlusion (CTO) of rightsuperficial femoral artery (SFA).

A : Antegrade injection shows a collateral channel from deep femoral artery (DFA) to the distal of CTO.

B : Antegrade guide wire passed through the CTO.

C : We performed balloon dilation with Jackal RX 5.0×20 mm (KANEKA Medix, Osaka, Japan).




Fig. 4. Final angiography.

Two SMART stents were implanted. Final angiography showed well expanded stents.

mal dissection into the proximal site. After that, we caught the retrograde Cruise wire by snare and pulled into the guiding catheter. Sniper2 μ 7 micro catheter over the Cruise wire was advanced into guiding catheter via CTO lesion. Then we changed Cruise wire to Agosal XS, successfully passed through the CTO site (Fig. 3B). We pulled Sniper2 μ 7 micro catheter to distal lumen of CTO. We performed balloon dilation with Jackal RX 5.0×20 mm (KANEKA Medix, Osaka, Japan) in the proximal SFA to distal SFA (Fig. 3C). Then two SMART stents 7.0×100 mm (Cordis Johnson and Johnson, Warren, USA) were implanted from proximal to mid portion SFA. We performed post balloon dilation with same Jackal RX 5.0×20 mm. The final angiography showed well expanded stents (Fig. 4). All target lesions were successfully dilated in 2 hours and 11 minutes. His right and left ABI improved to 1.08 and 1.03, respectively.

DISCUSSION

The patients with TASC D lesion of SFA such as this patient are recommended to be treated by surgical femoral popliteal bypass²⁾. However, since it has been recently reported that device and technical developments provide high recanalization rates³⁾. Comparing with F-P bypass, in a recent report¹⁾, the

1 year and 5 years primary patency rates were 82.1% and 69.4% in the bypass surgery and 67.8% and 45.2% in the EVT in claudication patients with TASC C and D, respectively. However, the 1 year and 5 years secondary patency rates were 93.2% and 79.5% in the F-P bypass surgery and 90.1% and 85.1% in the EVT, respectively. Although the bypass surgery group had a higher primary patency rate than the EVT, secondary patency rates did not differ significantly between the EVT and bypass surgery. Such patients treated with EVT have been increasing. But the initial success rate of EVT for CTO of SFA was reported to be lower than that of iliac artery. The fewer kinds of approaches for EVT of SFA are related to the lower success rate of SFA than iliac artery. A new approach possibly improves success rate of EVT to CTO of SFA. Retrograde approach to CTO of SFA is commonly transpopliteal approach obtaining via the ipsilateral popliteal artery. This technique was reported first 25 years ago⁴⁾, but might have some limitations such as a risk of injuries of vein or nerves and prolonged puncture time on a prone position^{4,5)}. In addition, patients are forced to a prone position during EVT, and patient's burden is heavy. In our technique, puncture site is contralateral or ipsilateral common femoral artery, no need of a retrograde distal puncture, and patient's position is spine. Therefore, it is easier to puncture artery and has less risk than transpopliteal approach. However, since collateral channels generally have small lumen and are highly tortuous like corkscrew and it has a risk of perforation or other artery injuries to manipulate guide wire, it is necessary to more carefully manipulate guide wires. Sometimes, we need several wires to cross the channel, and the wire controllability is not enough through tight bend.

Echo-guided puncture devices have been recently developed, and they can reduce injuries of vein or nerves and the puncture time on a prone position. On the other hand, a retrograde approach using DFA may injure collateral channels and have a weak back-up force for penetrating CTO lesions. If the puncture of popliteal arteries becomes to be easy using echo-guided device, a retrograde popliteal approach might be safer than a retrograde DFA approach we proposed. In this case, if collateral artery was injured, there was a risk of ischemic limb. Thus, we were considering F-P bypass, if we failed this procedure.

In the past 3 years, we performed total 87

procedures of EVT to CTO of SFA, and attempted retrograde approach via collateral channels in 5 cases. Including this case, we succeeded 3 out of 5 cases of EVT of CTO to SFA using retrograde approach via collateral channel from DFA. In prior to EVT, we performed CT angiography and confirmed that collateral channels to SFA from DFA were well developed, and we selected this approach. Since CT or magnetic resonance imaging (MRI) are effective to understand the artery anatomy in prior to angiography (6), the appropriate use of these imaging modalities raises the success rate of EVT.

CONCLUSIONS

We successfully treated CTO of SFA with retrograde approach via collateral channels from DFA. This novel method is possibly one of the efficient techniques in EVT to CTO of SFA.

REFERENCES

1. Aihara H, Soga Y, Mii S, *et al.* Comparison of Long-Term Outcome After Endovascular Therapy Versus Bypass Surgery in Claudication Patients With Trans-Atlantic Inter-Society Consensus-II C and D Femoropopliteal Disease. *Circ J*, **78** : 457-464, 2014.
2. Norgren L, Hiatt WR, Dormandy JA, *et al.* Inter-Society Consensus for the Management of Peripheral Arterial Disease (TASC II). *Eur J Vasc Endovasc Surg*, **33** : S1-75, 2007.
3. Suzuki K, Iida O, Soga Y, *et al.* Long-term results of the S.M.A.R.T. Control (TM) stent for superficial femoral artery lesions, J-SMART registry. *Circ J*, **75** : 939-944, 2011.
4. Tonnesen KH, Sager P, Karle A, *et al.* Percutaneous transluminal angioplasty of the superficial femoral artery by retrograde catheterization via the popliteal artery. *Cardiovasc Intervent Radiol*, **11** : 127-131, 1988.
5. Sakai H, Oyama N, Imagawa S, *et al.* Impact of a bidirectional approach via radial and popliteal arteries for the treatment of chronic total occlusion of lower limb artery. *Int J Angiol*, **16** : 27-30, 2007.
6. Link J, Steffens JC, Brossmann J, *et al.* Iliofemoral arterial occlusive disease : Contrastenhanced MR angiography for preinterventional evaluation and follow-up after stent placement. *Radiology*, **212** : 371-377, 1999.