



A case of gastrointestinal stromal tumor with pneumomediastinum

メタデータ	<p>言語: English</p> <p>出版者: The Fukushima Society of Medical Science</p> <p>公開日: 2014-03-20</p> <p>キーワード (Ja):</p> <p>キーワード (En): pneumomediastinum, gastrointestinal stromal tumor, submucosal tumor, perforation, gastric tumor</p> <p>作成者: Sugimoto, Mitsuru, Hikichi, Takuto, Shioya, Yasuo, Hayashi, Manabu, Saito, Keietsu, Sagawa, Keiichi, Nozawa, Yoshihiro, Obara, Katsutoshi, Ohira, Hiromasa</p> <p>メールアドレス:</p> <p>所属:</p>
URL	<p>https://fmu.repo.nii.ac.jp/records/2001844</p>

[Case Report]

A CASE OF GASTROINTESTINAL STROMAL TUMOR WITH PNEUMOMEDIASTINUM

MITSURU SUGIMOTO¹⁾²⁾, TAKUTO HIKICHI³⁾, YASUO SHIOYA¹⁾, MANABU HAYASHI¹⁾²⁾,
KEIETSU SAITO¹⁾, KEIICHI SAGAWA¹⁾, YOSHIHIRO NOZAWA⁴⁾,
KATSUTOSHI OBARA³⁾ and HIROMASA OHIRA²⁾

¹⁾Department of Internal Medicine, Hanawa Kosei Hospital, Higashishirakawa, ²⁾Department of Gastroenterology and Rheumatology, Fukushima Medical University, Fukushima, ³⁾Department of Endoscopy, Fukushima Medical University Hospital, Fukushima, ⁴⁾Department of Diagnostic Pathology, Shirakawa Kosei General Hospital, Shirakawa, Japan

(Received March 13, 2013, accepted August 1, 2013)

Abstract : A 52-year-old man noticed physical weariness and anorexia in November 2008. Severe anemia was found. Pneumomediastinum was detected using x-ray and CT scanning. Esophagogastroduodenoscopy revealed a submucosal tumor with a deep ulcer in the anterior wall of the upper stomach, causing anemia. Partial gastrectomy was performed because microperforation was suspected. The resected specimen showed spindle-shaped tumor cells that were c-kit positive and CD34 positive on immunohistological staining, suggesting a diagnosis of gastrointestinal stromal tumor (GIST). Although emphysema in the abdominal cavity was not observed, air leakage from gastric GIST with necrosis in the upper stomach was inferred as the cause of pneumomediastinum.

Key words : pneumomediastinum, gastrointestinal stromal tumor, submucosal tumor, perforation, gastric tumor

INTRODUCTION

Pneumomediastinum is a state in which gas enters the mediastinum. Some cases require emergency treatment depending on the air route, although identification of the air route is difficult in other cases. Along with a review of the literature, this report describes a case of gastrointestinal stromal tumor (GIST) with a deep ulcer accompanied by pneumomediastinum.

CASE REPORT

A 52-year-old man had complained of physical weariness and anorexia since November 2008. Because the symptoms did not improve, he consulted Hanawa Kosei Hospital in December of that year. He had no history of respiratory disease such

as asthma or traffic injury. Blood examination revealed anemia with 4.9 g/dl hemoglobin concentration. Snowball crepitus was palpated in the neck and tarry feces were observed from a rectal examination. Chest x-ray revealed translucence in the neck. A CT scan revealed pneumomediastinum as well as a huge tumor in the upper part of the stomach. However, no emphysema was visible in the abdominal cavity. Emergent esophagogastroduodenoscopy (EGD) was performed, revealing a large submucosal tumor (SMT) in the anterior wall of the upper stomach, which presented a deep ulcer in the center. The patient was hospitalized for detailed examination. Treatment was administered on that day. Laboratory findings on admission are presented in Table 1. Translucence in the neck was observed using X-ray on admission, as described above. Pneumoderma (Fig. 1a), pneumomediasti-

Table 1. Blood test findings on admission

WBC	12,100 / μ l	ALP	122 IU/l	BS	177 mg/dl
RBC	159×10^4 / μ l	γ -GTP	8 IU/l	HbA1c	4.7%
Hb	4.8 g/dl	TG	166 mg/dl		
Plt	16.4×10^4 / μ l	T-Cho	122 mg/dl	CRP	0.07 mg/dl
		HDL-C	32 mg/dl		
PT	128%	LDL-C	62 mg/dl	CEA	0.6 ng/ml
APTT	20 sec	BUN	39.5 mg/dl	CA19-9	2.0 U/ml
		Cr	1.03 mg/dl		
TP	5.8 g/dl	UA	8.3 mg/dl	IgG	364 mg/dl
ALB	3.5 g/dl	Na	137 mmol/l	IgA	266 mg/dl
T-Bil	1.5 mg/dl	K	4.5 mmol/l	IgM	73 mg/dl
AST	16 IU/l	Cl	107 mmol/l		
ALT	12 IU/l	AMY	119 IU/l	β -D-glucan	0.8 pg/ml
LDH	171 IU/l	CK	55 IU/l		

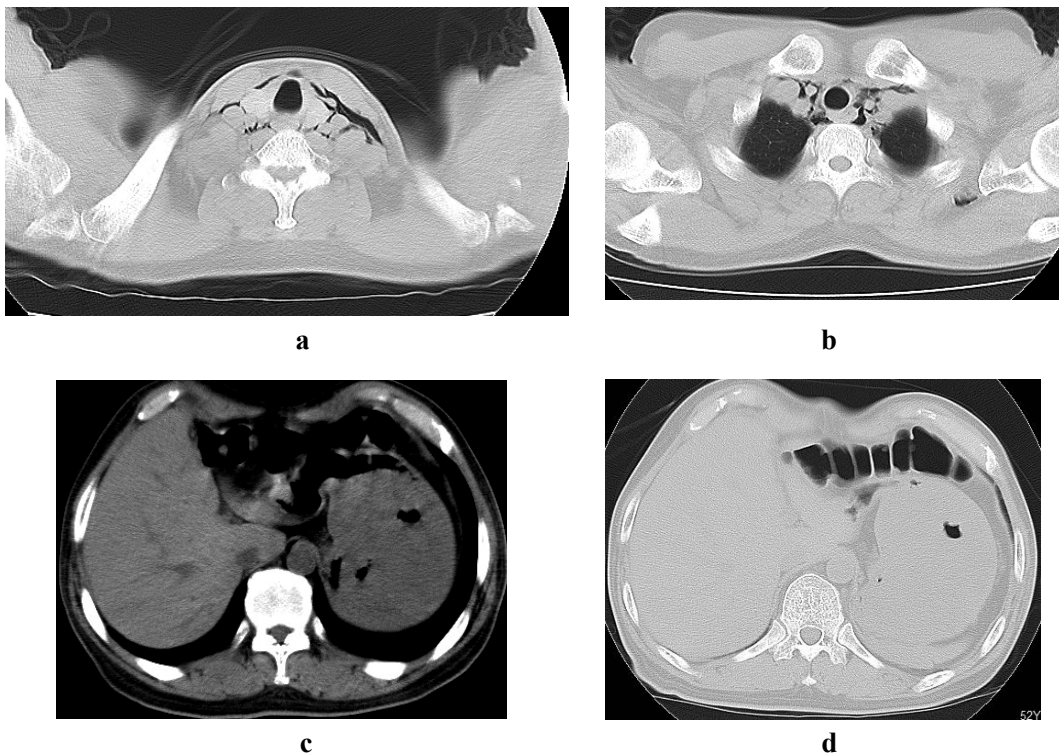


Fig. 1. Chest and abdominal CT scans. a) Pneumoderma was observed in the neck. b) Pneumomediastinum was detected in the chest, but no marked pneumothorax was observed. c) The tumor was found in the upper part of the gastric stomach (arrow indicates tumor). d) No emphysema was detected in the abdominal cavity.

num (Figs. 1b), and a tumor with a cavity in the upper part of the stomach (Fig. 1c) were detected, but no emphysema was observed in the abdominal cavity (Fig. 1d) by CT scanning. EGD revealed an SMT of approximately 10 cm with a deep ulcer in the anterior wall of the upper stomach (Fig. 2).

Considering the finding of tarry feces, we suspected that anemia resulted from bleeding from the SMT. The possibility of pneumomediastinum

caused by perforation of the tumor could not be excluded because the SMT was close to the mediastinum. Two units of packed red blood cells were transfused at 1, 2, 3, 9, and 10 days of hospitalization to treat the anemia. Fever and an increase of white blood count ($12,100/\mu$ l) on blood examination suggested the possibility of mediastinitis and tumor fever because of SMT and peritonitis caused by SMT perforation. An antibiotic, piperacillin, was

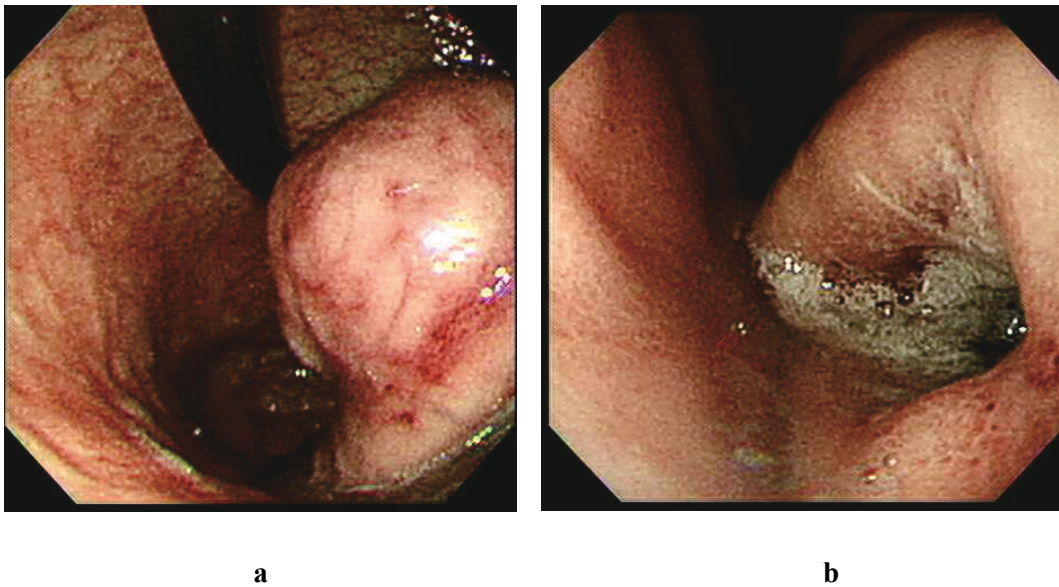


Fig. 2. a, b) Endoscopic finding of the lesion. The lesion was regarded as SMT, with ulceration detected in the center in the anterior wall of the upper stomach.

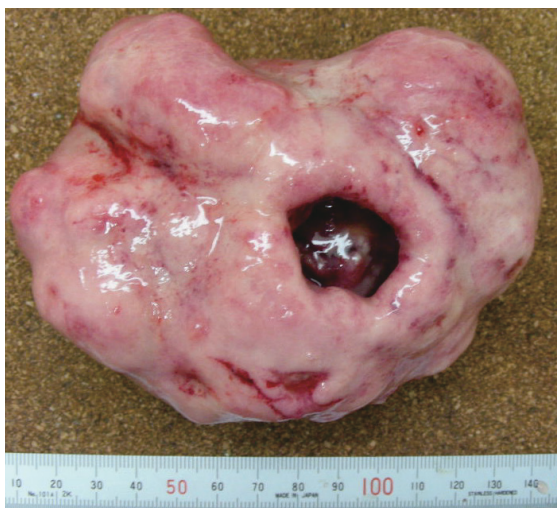

Fig. 3. Resected specimen. The resected tumor was 10.5×7.5 cm with infiltration into the serosa.

administered at 2 g/day. A chest CT taken on day 7 revealed that the pneumomediastinum had improved accordingly by this conservative treatment. However, he was sometimes heated, showing elevated CRP (7.14 mg/dl). Then 2 g/day ceftriaxone was added from day 9. After further improvement of CRP and anemia by blood transfusion, the patient was transferred to the Department of Surgery on day 14 of hospitalization. The patient underwent partial gastrectomy. At that time, no contamination of the abdominal cavity, emphysema in the peritoneum or under the diaphragm was shown.

The resected specimen showed no perforated site. The route of air into the mediastinum was not specified (Fig. 3). The tumor size was 10.5×7.5

cm. Its deepest point reached the serosa. It showed proliferation of interlacing bundles of spindle-shaped tumor cells. No perforation was observed (Fig. 4a). Immunohistological findings of c-kit (+), CD34 (+), SMA (-), Desmin (-), and S-100 protein (-) led to a diagnosis of GIST (Figs. 4b, 4c). The mitotic figures were fewer than 5 per 50 HPFs and the tumor diameter was greater than 10 cm, suggesting a high risk according to Fletcher's classification and intermediate risk according to Miettinen's classification.

DISCUSSION

Pneumomediastinum is generally said to result from an increase of intrathoracic pressure, pulmonary lesions, tracheobronchial disruption, esophageal rupture, trauma in the head and neck, and surgeries¹⁾. The present case had a huge GIST with a deep ulcer in the upper body of the stomach, complicated by pneumomediastinum.

We infer that pneumomediastinum might occur idiopathically. So-called idiopathic pneumomediastinum, which allows no opportunity to isolate the course of air inflow, is widely known to have Macklin's theory as its developmental mechanism²⁾. The airway pressure, which becomes positive for some reason, engenders elevated intra-alveolar pressure. The alveoli explode. The air from the alveoli reaches the pulmonary hilus to form pneumomediastinum. In addition, genetic weakness of the alveolar wall or acquired weakness by long repeated inspiration–expiration is inferred as

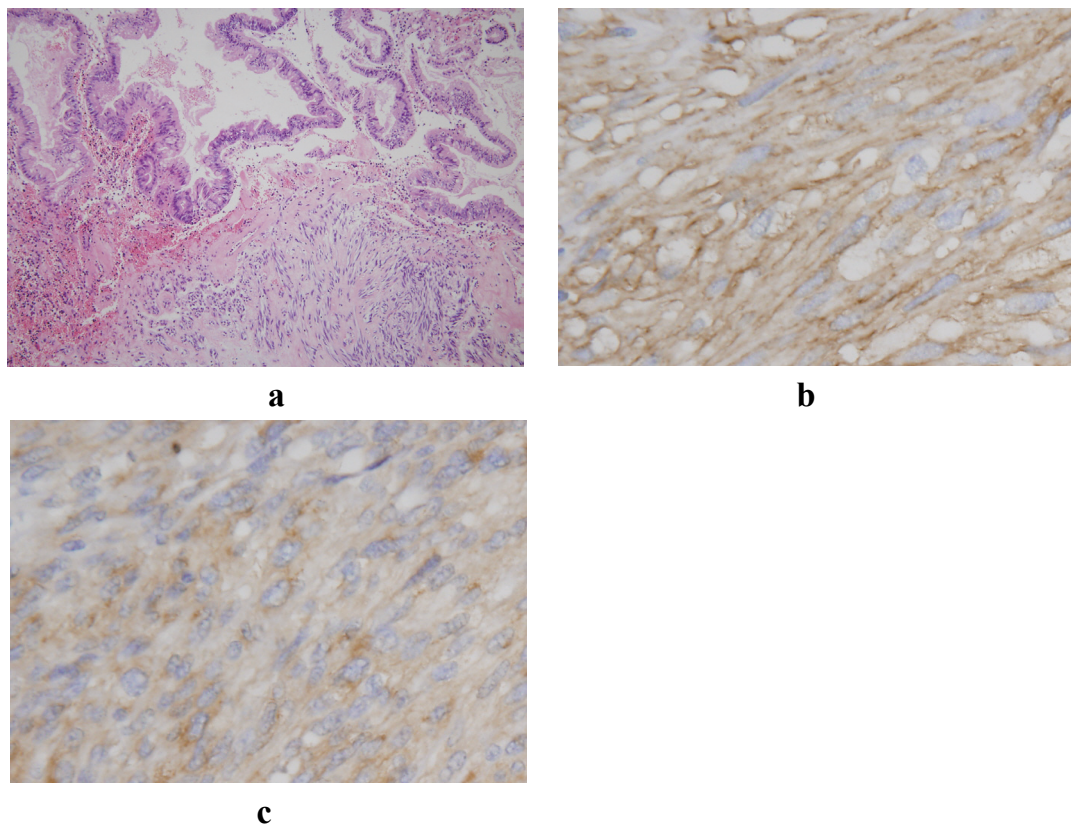


Fig. 4. Histopathological findings.

A) The tumor was detected at the deepest point of ulcer floor, with no evident perforation (HE staining). B, C) Immunohistological staining revealed CD34 (+) and CD117 (c-kit) (+), and led to a diagnosis of GIST.

Table 2. Complications of gastric lesions and pneumomediastinum

Reported year	Author	Age	Sex	Location	Diagnosis	Treatment (Period until the surgery)	Diameter of perforation	Prognosis
1988	Kawabata et al. ⁸⁾	40	Male	Lesser curvature of body	Gastric ulcer	Surgery (emergency)	No record	Discharge
1990	Amemiya et al. ⁹⁾	40	Male	Lesser curvature of body	Gastric ulcer	Surgery (emergency)	No record	No record
2009	Hussain et al. ⁶⁾	65	Male	Posterior wall of body	Gastric ulcer	Surgery (no record)	Not confirmed	Discharge
2009	Pallotta et al. ⁷⁾	75	Male	Cardia	Gastric cancer	Surgery (emergency)	3 mm	Discharge
2010	Fujishiro ⁵⁾	55	Female	Cardia	Gastric cancer	Conservative treatment	Not confirmed	Discharge
2012	Our case	52	Male	Anterior wall of upper body	GIST	Surgery (14 days)	Not confirmed	Discharge

GIST, gastrointestinal stromal tumor

the cause^{3,4)}. However, this patient did not complain of symptoms that elevate intra-alveolar pressure. He was not designated as having genetic alveolar weakness.

Five cases were reported in *Igaku-Chuo Zasshi*, published during 1983–2010 and in PubMed during 1979–2010, when searched using “pneumomediastinum” along with “gastric tumor”, “gastric ulcer”, “submucosal tumor”, and “GIST” (Table 2)^{5–9)}. The locations were lesser curvature and the posterior wall near the cardia of the stomach. Some cases had no evident perforation. In only one case was microperforation suspected to cause air to enter. The patient with gastric cancer in the cardia

num” along with “gastric tumor”, “gastric ulcer”, “submucosal tumor”, and “GIST” (Table 2)^{5–9)}. The locations were lesser curvature and the posterior wall near the cardia of the stomach. Some cases had no evident perforation. In only one case was microperforation suspected to cause air to enter. The patient with gastric cancer in the cardia

underwent endoscopic submucosal dissection (ESD). Pneumomediastinum developed postoperatively as a complication⁵⁾. In the case reported herein, because the tumor reached the serosa, indicating a deeper lesion than those in the reports described above, temporary microperforation might have occurred and caused pneumomediastinum. Among the cases described above, Hussain *et al*⁶⁾ reported a case of pneumomediastinum and portal venous gas, although no obvious perforation site was confirmed. Pallotta *et al*⁷⁾ reported pneumomediastinum attributable to a 3 mm perforation in a gastric cancer and Fujishiro *et al*⁵⁾ reported that pneumomediastinum might occur by microperforation after ESD. As each case showed, with low oxygen saturation in the blood, pneumomediastinum might have led to severe conditions after onset, even if the perforation was small. However, it is difficult to consider the presence of perforation or air leakage of the alimentary tract lesion, or pneumomediastinum if no marked abdominal disorder or difficulty breathing is observed, as in our case. In our case, although emphysema in the abdominal cavity was not observed, the possibility of air leakage from gastric GIST was inferred, with necrosis in the upper stomach causing pneumomediastinum.

The authors state that they have no conflict of interest.

REFERENCES

1. Nakadate T. Pneumomediastinum. *Kokyu (Respiration Research)*, **31** : 367-372, 2012 (in Japanese).
2. Macklin CC. Transport of air along sheaths of pulmonic blood vessels from alveoli to mediastinum. *Arch Inter Med*, **64** : 913-926, 1939.
3. Hamman L. Spontaneous mediastinal emphysema. *Bull Johns Hopkins*, **64** : 1-21, 1939.
4. Bodey GP. Medical mediastinal emphysema. *Ann Intern Med*, **54** : 46-56, 1961.
5. Fujishiro M. The possibility of pneumomediastinum or pneumothorax caused by microperforation should be considered when ESD is performed in the cardiac region. *Naika (Internal Medicine)*, **106** : 1070-1072, 2010 (in Japanese).
6. Hussain A, Mahmood H, Ansari T, El-Hasani S. Pneumomediastinum, stomach wall and hepatic portal vein gas secondary to partial necrosis of the stomach wall. *Singapore Med J*, **50** : 166-169, 2009.
7. Pallotta S, Manes G, Ferrara EC, Trabucchi E, Pace F, Bianchi PG. Bilateral pneumothorax and pneumomediastinum during upper endoscopy: The role of gastric perforation and of cardiopulmonary resuscitation maneuvers. *Endoscopy*, **41** : 97, 2009.
8. Kawabata M, Sugiyama K, Iba T, Aoki M, Hukunaga M, Kidokoro A, Tani H, Itaya H, Yagi Y. A case of perforating gastric ulcer accompanied by subcutaneous and mediastinal pneumatosis. *Nihon kyokyu igakkai Kantoshi (KANTO Journal of JAAM)*, **9** : 108-109, 1988 (in Japanese).
9. Amemiya K, Yumoto K, Tamamoto F, Hirano A, Ozaki Y, Sumi Y, Katayama H, Kidokoro A, Kawabata M, Yagi Y, Ishi K. A case of stomach ulcer perforation with widespread retroperitoneal emphysema and pneumomediastinum. *Gazoshindan (Japanese Journal of Diagnostic Imaging)*, **10** : 103-107, 1990 (in Japanese).