



## A case of Henoch-Schoenlein purpura nephritis recurring after 3 years remission

メタデータ	<p>言語: English</p> <p>出版者: The Fukushima Society of Medical Science</p> <p>公開日: 2011-07-05</p> <p>キーワード: HSPN, Recurrence, Plasmapheresis, Mizoribine Methylprednisolone and urokinase pulse therapy, Child, Female, Glomerulonephritis, IGA, Humans, Plasmapheresis, Prednisolone, Purpura, Schoenlein-Henoch, Recurrence, Time Factors, Urokinase-Type Plasminogen Activator</p> <p>作成者: Ushijima, Yumiko, Kawasaki, Yukihiro, Kaneko, Mariko, Haneda, Kentaro, Sakai, Nobuko, Suyama, Kazuhide, Hashimoto, Koichi, Hosoya, Mitsuaki</p> <p>メールアドレス:</p> <p>所属:</p>
URL	<p><a href="https://fmu.repo.nii.ac.jp/records/2001777">https://fmu.repo.nii.ac.jp/records/2001777</a></p>

## A CASE OF HENOCH-SCHOENLEIN PURPURA NEPHRITIS RECURRING AFTER 3 YEARS REMISSION

YUMIKO USHIJIMA, YUKIHIKO KAWASAKI, MARIKO KANEKO,  
KENTARO HANEDA, NOBUKO SAKAI, KAZUHIDE SUYAMA,  
KOICHI HASHIMOTO and MITSUAKI HOSOYA

*Department of Pediatrics, Fukushima Medical University School of Medicine, 1 Hikariga-oka, Fukushima City,  
Fukushima, Japan*

(Received November 18, 2009, accepted April 14, 2010)

**Abstract :** Henoch-Schoenlein purpura (HSP) is a systemic disorder characterized by leukocytoclastic vasculitis involving the capillaries with IgA immune complexes deposition, and about 7% of patients with HSP experience recurrence. Most patients with recurring of HSP nephritis show a recurrence of clinical symptoms over a period ranging from 2 to 5 months, even after the disappearance of initial symptoms. Here we report a 9-year-old girl diagnosed with recurrent HSP and severe crescentic glomerulonephritis 3 years after complete resolution of the initial symptoms of HSP. Our case is unique in respect of the recurrence at more than 3 years after the complete resolution of initial symptoms, suggesting that careful follow-up is required in spite of improved renal symptoms in cases of HSP.

**Key words :** HSPN, Recurrence, Plasmapheresis, Mizoribine Methylprednisolone and urokinase pulse therapy

### INTRODUCTION

Henoch-Schoenlein purpura (HSP) is an immunoglobulin (Ig) A-mediated immune-complex vasculitis predominantly affecting the skin, joints, gastrointestinal tract, and kidneys. It occurs most frequently in childhood and the prognosis for HSP patients is largely predicted by the severity of renal involvement.

The majority of children with HSP nephritis (HSPN) presenting with only hematuria and/or low-grade proteinuria have a good chance of recovery. However, those patients with massive proteinuria at onset frequently show a progressive course<sup>1,2)</sup>. In specialized centers, the proportion of children with HSPN progressing to renal failure or end-stage renal disease varies from 12% to 19%<sup>3-6)</sup>.

---

牛嶋裕美子, 川崎幸彦, 金子真理子, 羽田謙太郎, 酒井信子, 陶山和秀, 橋本浩一, 細矢光亮  
Corresponding author : Yukihiko Kawasaki E-mail : kyuki@fmu.ac.jp  
http : //fmu.ac.jp/lib/F-igaku/ http : //www.sasappa.co.jp/online/

The epidemiology of HSP is obscure. As to the recurrence of HSP, Cakir *et al.* reported that 8 (6.9%) of 116 patients with HSPN showed recurring clinical symptoms over a period ranging from 2 to 5 months, even after complete resolution of initial symptoms<sup>7</sup>. However, there have been few reports on the recurrence of HSPN at more than 3 years after the complete resolution of symptoms of HSP<sup>8</sup>.

Here we report a 9-year-old girl presenting with recurrent HSP and severe crescentic glomerulonephritis at 3 years after complete resolution of the initial symptoms of HSP.

#### CASE REPORT

The patient first presented with purpura, abdominal pain and bloody stools at 7 years of age in December 2004 and her family physician was consulted. Her family physician diagnosed HSP on the basis of abdominal pain, purpura, arthralgia, proteinuria and hematuria. The patient was referred to a hospital and admitted. Laboratory tests revealed a leukocyte count of  $7,100/\text{mm}^3$ , erythrocyte count of  $482 \times 10^4/\text{mm}^3$ , platelet count of  $47.4 \times 10^4/\text{mm}^3$ , a serum total protein level of 6.7 g/dl, serum albumin of 4.0 g/dl, serum creatinine of 0.4 mg/dl, and serum total cholesterol of 185 mg/dl. Urinalysis revealed protein excretion of 0.4 g/day, with sediment containing 50 erythrocytes, 10 leukocytes, and a few granular casts per high-power field. Creatinine clearance (24-h) was 124.2 ml/min per  $1.73 \text{ m}^2$ . Immunology studies revealed a C3 of 118 mg/dl, C4 of 35 mg/dl, CH50 of 72.0 U/ml, antinuclear antibody titer of <160 X, negativity for anti-DNA antibody, and negativity for titers of serum anti-neutrophil cytoplasmic antibodies. Prothrombin time and activated partial thromboplastin time were normal, and factor XIII activity was 54%.

At Day 10 of hospitalization, the patient's urinary protein excretion was 1.8 g/day. She was diagnosed with HSPN and treated intravenously with two courses of methylprednisolone pulse therapy (600 mg/day), followed by daily oral administration of prednisolone (PSL, initially 30 mg/day). After treatment, her urinary protein excretion decreased and microhematuria disappeared. Subsequently, the prednisolone treatment was tapered off after 6 months of treatment because the proteinuria and hematuria had completely disappeared. Regular urine analysis did not reveal any abnormalities for more than 3 years.

In November 2008 the girl experienced a second attack of purpura on her legs, with associated pharyngitis, persistent purpura, abdominal pain and proteinuria. Urinary protein excretion increased to more than 5 g/day despite treatment with intravenous PSL (2 mg/kg/day). The girl was, therefore, referred to our hospital in December 2008.

Laboratory tests revealed a serum total protein level of 5.7 g/dl, serum albumin of 2.8 g/dl, serum creatinine of 0.6 mg/dl, and serum total cholesterol of 283 mg/dl. Urinalysis revealed protein excretion of 4.0 g/day, with sediment containing 50 erythrocytes, 50 leukocytes, and many granular casts per high-power field. Creatinine clearance (24-h) was 44.1 ml/min per  $1.73 \text{ m}^2$ . Immunology studies revealed a C3 of 107 mg/dl, C4 of 32 mg/dl, CH50 of 42 U/ml, antinuclear antibody titer of <160 X, negativity for anti-DNA antibody, and negativity for titers of serum anti-neutrophil cytoplasmic antibodies. Prothrombin time and activated partial thromboplastin time were normal, and factor XIII activity was 54%. A diagnosis

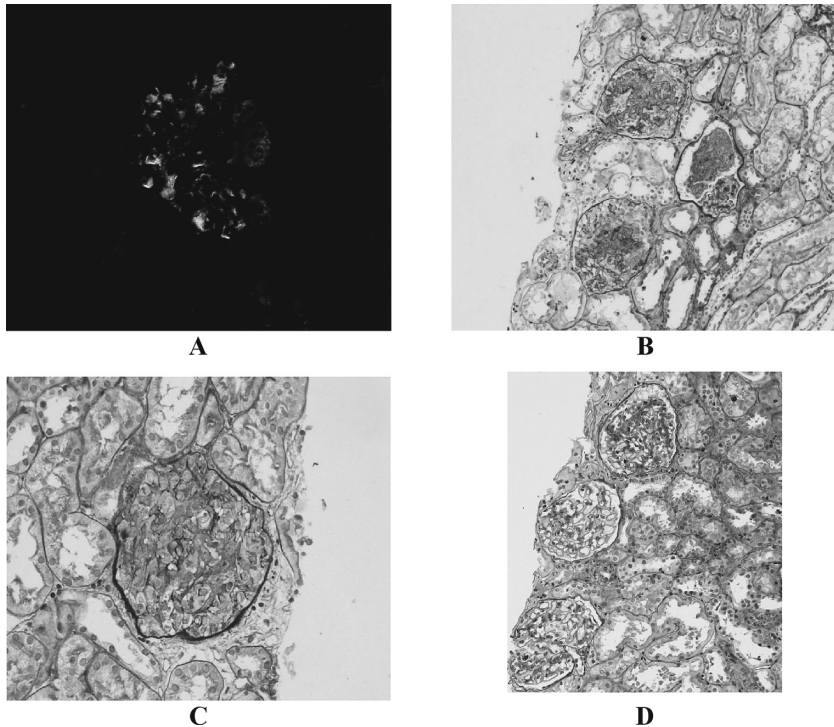


Fig. 1. A : Immunofluorescence microscopic examination revealed predominant IgA deposition with C3 in the mesangial area ( $\times 200$ ).  
 B : Light microscopic examination showed diffuse mesangial proliferation, and a small increase in the mesangial matrix was found (PAS stain,  $\times 100$ ).  
 C : Cellular crescent formation was found in glomeruli (PAS stain,  $\times 400$ ).  
 D : Light microscopic examination showed little segmental mesangial cell proliferation, and only mild mesangial matrix accumulation was found.

of nephrotic syndrome was made on the basis of the severe proteinuria, hypoproteinemia, edema, and hypercholesteremia. A first renal biopsy was performed, and immunofluorescence microscopic examination revealed a predominant IgA deposition with C3 in the mesangial area. Light microscopic examination showed diffuse mesangial proliferation, and a small increase in the mesangial matrix was found. Eleven of 14 glomeruli (78%) showed cellular crescent formation. The patient was, therefore, diagnosed with HSPN with an International Study of Kidney Disease in Children (ISKDC) classification of grade V and nephrotic syndrome, and was treated with three courses of methylprednisolone pulse therapy, 625 mg/day, followed by daily intravenous administration of PSL (60 mg/day) and plasmapheresis (PP) was performed 5 times. Urinary protein excretion decreased, as a result of this treatment, but proteinuria (2-3 g/day) continued. We, therefore, decided to use mizoribine (MZB) (150 mg/day, in a single dose). After 2 weeks of MZB treatment, the proteinuria began to gradually decrease, and fell to less than 0.5 g/day over the next 2 months. The administration of PSL was tapered off to 20 mg/day. During the tapering of the PSL treatment, purpura appeared three times, but urinary protein excretion decreased. In April 2009, a second renal

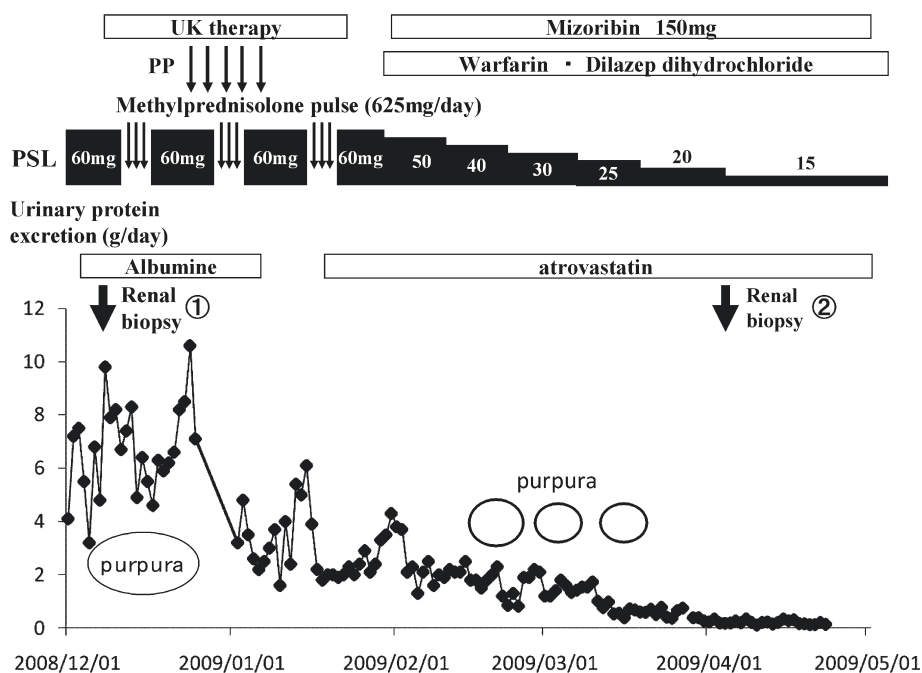


Fig. 2. Clinical course of the patients.

PSL ; prednisolone, PP ; plasmapheresis, UK ; urokinase

biopsy was performed to investigate the efficacy of treatment. Immunofluorescence microscopic examination revealed a small degree of IgA deposition with C3 in the mesangial area. Light microscopic examination showed little segmental mesangial cell proliferation, and only mild mesangial matrix accumulation was found. Three of 26 glomeruli (11.5%) showed cellular crescent formation. The patient was, therefore, diagnosed with HSPN with an ISKDC classification of grade IIIa. The purpura disappeared and urinary protein excretion was significantly decreased and there was no proteinuria or purpura observed during the 6 months of follow-up and ongoing administration PSL (15 mg/day).

#### DISCUSSION

HSP is predominantly a childhood vasculitic disease, characterized by the presence of immunoglobulin (IgA1) dominant immune deposits in the small vessels. The annual incidence of HSP has been reported to be 13.5 to 22.1 per 100,000<sup>9-11)</sup>. While HSP is often a self-limited condition, approximately 40% of pediatric patients develop nephritis within 4 to 6 weeks of the initial presentation<sup>12)</sup>. An age of more than 10 years at onset, persistent purpura, severe bowel angina, and relapse were identified as factors for the nephritis of HSP<sup>13)</sup>.

In addition, about 25-40% of HSP patients experienced one or more recurrences of any or all of the symptoms after a period of relative well-being, usually within six weeks of onset<sup>14)</sup>. However, there have been no reports on the incidence of HSPN recurrence.

In our report, the patient presented with recurring clinical symptoms of HSPN over 3 years after the complete resolution of the initial symptoms of HSP and severe diffuse mesangial proliferative glomerulonephritis with an ISKDC classification of grade V. There have been few reports on the recurrence of HSPN at more than 3 years after the complete resolution of initial HSP symptoms. Fujinaga *et al.* reported the recurrence of HSPN after a 6-year remission in a 15-year-old girl<sup>8)</sup>. Our present patient also appears to be an unique case.

As for reports concerning the prognosis of HSPN, Counahan R *et al.*<sup>3)</sup> reviewed 88 patients with HSPN and found that 15 of 26 patients (58%) with an ISKDC classification of least grade IV, and 5 of 38 (13%) without treatment had active renal disease, renal insufficiency or both. Yoshikawa *et al.*<sup>15)</sup> reported that HSPN was a significant cause of childhood chronic renal failure, accounting for 16% of all children undergoing peritoneal dialysis in Japan. Specifically, 52% (13 of 25) of the patients in their study with an ISKDC classification of at least grade IV, had renal insufficiency. Thus, it is speculated that adequate treatment is necessary to improve the prognosis of HSPN with massive proteinuria and an ISKDC classification of more than grade IV.

As for the treatment of severe HSPN, there have been some reports dealing with the use of multiple combined agents, such as PP, and immunosuppressive drugs, including cyclophosphamide and azathioprine<sup>16-19)</sup>. Iijima *et al.*<sup>17)</sup> reported that a multiple combined therapy with prednisolone, cyclophosphamide, heparin or warfarin, and dipyridamole could be effective in case of histologically severe HSPN. In addition, Flynn JT *et al.*<sup>19)</sup> reported that treating children with HSPN with high-dose corticosteroids plus oral cyclophosphamide is safe and, as in cases of nephrotic syndrome, appears to significantly reduce proteinuria. In our study, we treated the patient with PP, methylprednisolone and urokinase pulse therapy, and MZB. After treatment, urinary protein excretion was found to be significantly decreased and the macrohematuria had disappeared. The pathological findings at the second biopsy were improved compared to those at the first renal biopsy.

The mechanisms by which PP benefits the patients with severe HSPN remain largely obscure. However, experimental and clinical immunologic findings suggest that the rationale for using PP in the treatment of patients with HSPN relies on the removal of IgA-containing immune complexes or aggregates, or proinflammatory mediators including cytokines and complements; reduction in fibrinogen or other coagulation factors; and possibly desaturation of the mononuclear phagocyte system<sup>20,21)</sup>. In addition, the rationale for using prednisolone and MZB in case of severe HSPN is that corticosteroids and immunosuppressive agents reduce IgA production and minimize the abnormal immune response and inflammatory events that follow IgA deposition in the glomeruli. Urokinase, warfarin and dipyridamole are used to inhibit the mediators of glomerular damage<sup>4,18)</sup>.

We reported here a 9-years-old girl presenting with recurrent HSP and severe crescentic glomerulonephritis 3 years after the complete resolution of initial symptoms of HSP. Our case suggests that careful follow-up is required in cases of HSPN in spite of initially improved renal symptoms.

## REFERENCES

1. Habib R, Niaudet R, Levy M. Schoenlein-Henoch purpura nephritis and IgA nephropathy. In : Tisher CC, Brenner BM, eds. Renal pathology with clinical and functional correlations, 2nd edn. Lippincott, Philadelphia, 427-523, 1994.
2. Haycock GB. The nephritis of Henoch-Schoenlein purpura. In : Cameron JS, ed. Oxford Textbook of Nephrology, 2nd edn. Oxford University Press, Oxford, 585-612, 1998.
3. Counahan R, Winterborn MH, White RHR, Heaton JM, Meadow SR, Bluett NH, Swetschin H, Cameron JS, Chantler C. Prognosis of Henoch-Schoenlein nephritis in children. *Br Med J*, **2** : 11-14, 1977.
4. Watanabe T, Takahashi S, Nakajo S, Hamasaki M. Pathological improvement of IgA nephropathy and Henoch-Schoenlein purpura nephritis with urokinase therapy. *Acta Paediatrica Japonica*, **38** : 622-628, 1996.
5. Coppo R, Mazzucco G, Cagnoli L, Lupo A, Schena P, for the Italian Group of Renal Immunopathology Collaborative Study on Henoch-Schonlein purpura. Long-term prognosis of Henoch-Schoenlein nephritis in adults and children. *Nephrol Dial Transplant*, **12** : 2277-2283, 1997.
6. Niaudet P, Habib R. Methylprednisolone pulse therapy in the treatment of severe forms of Schoenlein-Henoch purpura nephritis. *Pediatr Nephrol*, **12** : 238-243, 1998.
7. Cakir M, Orhan F, Mungan T, Sonmez FM, Asian Y, Kalyoncu M, ErduranE, Gedik Y, Okten A. Henoch-Schoenlein in north-eastern Turkey. *Ann Trop Paediatr*, **26** : 59-65, 2006.
8. Fujinaga S, Ohtomo Y, Murakami H, Takemoto M, Yamashiro Y, Kaneko K. Recurrence of Henoch-Schoenlein purpura nephritis after long-term remission in a 15-year-old girl. *Pediatr Nephrol*, **21** : 1215-1216, 2006.
9. Gardner-Medwin JMM, Dolezalova P, Cummins C. Incidence of Henoch-Schonlein purpura, Kawasaki disease, and rare vasculitides in children of different ethnic origins. *Lancet*, **360** : 1197-1202, 2002.
10. Stewan M, Savage JM, Bell B. Long term renal prognosis of Henoch-Schonlein purpura in unselected childhood population. *Eur J Pediatrics*, **147** : 113-115, 1988.
11. Nielsen HE. Epidemiology of Schonlein-Henoch Purpura. *Acta Pathol Scand*, **77** : 125-131, 1988.
12. Lau KK, Suzuki H, Novak J, Wyatt RJ. Pathogenesis of Henoch-Shonlein purpura nephritis. *Pediatr Nephrol*, **25** : 19-26, 2010.
13. Shin JI, Park JM, Shin YH, Hwang DH, Kim JH, Lee JS. Predictive factors for nephritis, relapse, and significant proteinuria in childhood Henoch-Schoenlein purpura. *Scand J Rheumatol*, **35** : 56-60, 2006.
14. Allen DM, Diamond LK, Howell DA. Anaphylactoid Purpura in Children. *A.M.A Journal of diseases of children*, **99** : 147-168, 1960.
15. Yoshikawa N, Ito H, Yoshiya K, *et al.* Henoch-Schoenlein nephritis and IgA nephropathy in children : a comparison of clinical course. *Clin Nephrol*, **27** : 233-237, 1987.
16. Oner A, Tinaztepe K, Erdogan O. The effect of triple therapy on rapidly progressive type of Henoch-Schonlein nephritis. *Pediatr Nephrol*, **9** : 6-10, 1995.
17. Iijima K, Ito-Kariya S, Nakamura H, Yoshikawa N. Multiple combined therapy for severe Henoch-Schoenlein nephritis in children. *Pediatr Nephrol*, **12** : 244-248, 1998.
18. Foster BJ, Bernaro C, Drummono KN, Sbarma AK. Effective therapy for severe Henoch-Schoenlein purpura nephritis with prednisone and azathioprine : a clinical and histopathologic study. *J Pediatr*, **136** : 370-375, 2000.
19. Flynn JT, Smoyer WE, Bunchman TE, Kershaw DB, Sedman A. Treatment of Henoch-Schoenlein purpura Glomerulonephritis in Children with High-Dose Corticosteroids plus Oral Cyclophosphamide. *Am J Nephrol*, **21** : 128-133, 2001.
20. Coppo R, Basolo B, Roccatello D, Piccoli G. Plasma exchange in primary IgA nephropathy and

- Henoch-Schoenlein purpura syndrome nephritis. *Plasma Ther Transfus Technol*, **6** : 705-723, 1985.
21. Kawasaki Y, Suzuki J, Murai M, Takahashi A, Isome M, Nozawa R, Suzuki S, Suzuki H. Plasmapheresis therapy for rapidly progressive Henoch-Schonlein nephritis. *Pediatr Nephrol*, **19** : 920-923, 2004.