



A case of congenital unilateral partial absence of fallopian tube

メタデータ	<p>言語: English</p> <p>出版者: The Fukushima Society of Medical Science</p> <p>公開日: 2011-07-05</p> <p>キーワード (Ja):</p> <p>キーワード (En): absence of fallopian tube, congenital anomaly, infertility, torsion of adnexa, Adult, Fallopian Tubes, Female, Humans, Hysterosalpingography, Infertility, Female</p> <p>作成者: Yazawa, Hiroyuki, Yabe, Michihiro, Endo, Sumiko, Hayashi, Syoutaro</p> <p>メールアドレス:</p> <p>所属:</p>
URL	<p>https://fmu.repo.nii.ac.jp/records/2001776</p>

[Case Report]

**A CASE OF CONGENITAL UNILATERAL PARTIAL ABSENCE OF
FALLOPIAN TUBE**

HIROYUKI YAZAWA, MICHIIHIRO YABE, SUMIKO ENDO and SYOUTARO HAYASHI

Department of Obstetrics and Gynecology, Fukushima Red Cross Hospital, Fukushima, Japan

(Received February 3, 2010, accepted April 14, 2010)

Abstract : Congenital partial absence of a fallopian tube has rarely been reported in the literature. A 29-year-old nulligravida woman presented with a two-year history of infertility. Hysterosalpingography revealed an obstructed left fallopian tube with a normal uterine cavity and right fallopian tube. After several AIH treatments, diagnostic laparoscopy was performed, revealing segmental absence of the mid portion of the left fallopian tube. Only a 1-cm stump of the left fallopian tube remained, the majority of the isthmic portion was absent. A 3-cm distal ampullary portion with normal-appearing fimbria was attached to the left pelvic sidewall near the pelvic brim. No other abnormal findings were observed for the uterus, right fallopian tube, and ligaments surrounding the uterus.

There are two possible etiologies of partial absence of the fallopian tube: congenital absence associated with developmental alterations of the Müllerian ducts or asymptomatic torsion followed by autoamputation and reabsorption.

Key words : absence of fallopian tube, congenital anomaly, infertility, torsion of adnexa

INTRODUCTION

Congenital abnormalities of the female reproductive tract (abnormalities of the Müllerian duct) are estimated to occur in one of 500-2,000 women^{1,2)}, most commonly manifesting as various types of uterine anomalies. Partial or complete absence of the fallopian tube, a rare occurrence³⁾, is usually asymptomatic and typically only discovered by hysterosalpingography and diagnostic laparoscopy during workup for infertility.

CASE REPORT

A 29-year-old woman nulligravida presented to the infertility clinic with a two-year history of infertility. She had no remarkable family history or past pelvic surgeries. She had

矢澤浩之, 矢部通弘, 遠藤澄子, 林章太郎

Corresponding author : Hiroyuki Yazawa E-mail : ikyoku12@fukushima-med-jrc.jp
<http://fmu.ac.jp/home/lib/F-igaku/> <http://www.sasappa.co.jp/online/>

regular menstrual cycles, no complaints of dysmenorrhea or dyspareunia, and no history suggestive of pelvic inflammatory disease or endometriosis. Initial investigations confirmed normal menstrual cycles with regular ovulation, as documented by basal body temperature charting. Pelvic examination revealed a normal-sized, mobile uterus with a grossly normal cervix. Semen analysis of her husband revealed only mild oligozoospermia.

During the infertility workup, hysterosalpingography revealed a normal uterine cavity. The right fallopian tube had a normal configuration with spill, but the left fallopian tube was not visualized (Fig. 1). As treatment for infertility, three attempts at AIH (artificial insemination with husband sperm) were performed after five courses of timing therapy.

After these infertility treatments, the patient was referred to our hospital for further evaluation by laparoscopy. Diagnostic laparoscopy revealed a normal uterus and a normal right ovary and fallopian tube that spilled dye that had been injected into the uterine cavity transcervically (Fig. 2). The left fallopian tube had a 1-cm proximal portion and a 3-cm distal ampullary portion with normal-appearing fimbria attached to the left pelvic sidewall near the pelvic brim, but was missing the mid-isthmic portion (Fig. 3). There was no evidence of pelvic inflammatory disease or endometriosis. The pouch of douglas, round ligaments, uterosacral ligaments, ovarian ligaments, and vesicouterine peritoneal fold were all normal-appearing. Intravenous pyelography confirmed the presence of normal kidneys and ureters.

DISCUSSION

Among the congenital anomalies of the female genital tract, uterine malformations occur in 3-4% of infertile women and 10-15% of patients with recurrent abortions^{4,5}. Structural abnormalities of the fallopian tube, however, are very rare. Congenital fallopian tube anom-

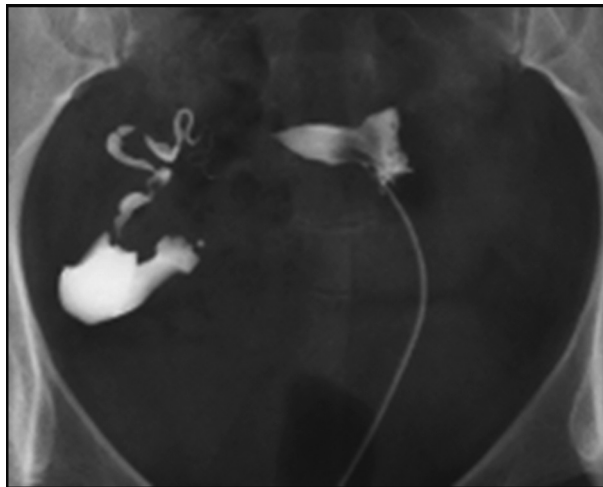


Fig. 1. Hysterosalpingography.

A hysterosalpingography revealed a normal uterine cavity. The right fallopian tube had normal configuration with spill, while the left fallopian tube was not visualized.

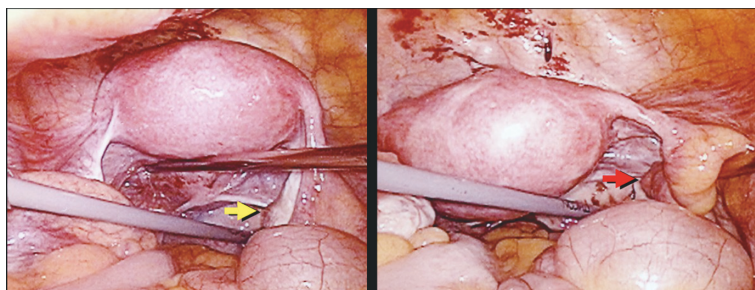


Fig. 2. Diagnostic laparoscopic view.
Laparoscopy revealed a normal uterus and normal right ovary (yellow arrow) and fallopian tube with normal fimbria (red arrow).

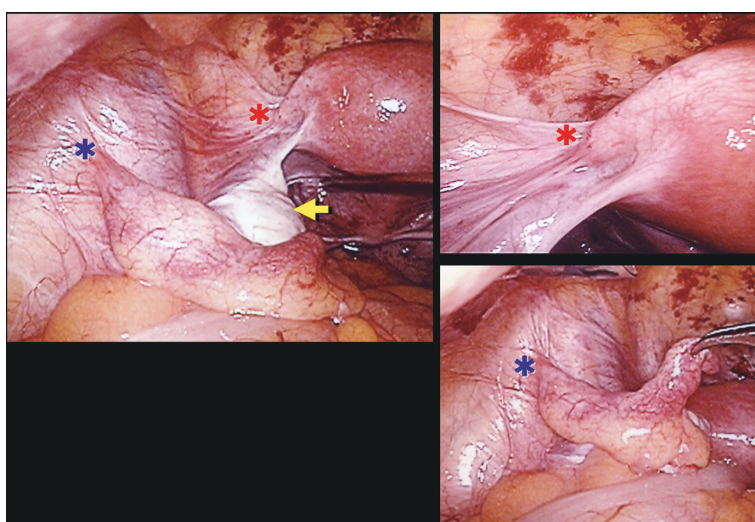


Fig. 3. Diagnostic laparoscopic view.
The left fallopian tube had an intact 1-cm proximal portion, but was missing the mid-isthmic portion (between the red and blue stars). A 3-cm distal ampullary portion with normal-appearing fimbria was attached to the left pelvic sidewall near the pelvic brim. The yellow arrow indicates a normal left ovary.

lies include accessory ostia, multiple lumina⁶⁾, duplication⁷⁾, complete absence⁸⁾, or segmental deletion of different regions of the fallopian tube³⁾. A comprehensive literature search performed by Nawroth *et al.* in 2006 only identified 18 patients with partial atresia of the fallopian tubes³⁾. Segmental atresia could occur unilaterally or bilaterally, but most reported cases (14/18) displayed unilateral partial tubal atresia. Several cases of partial tubal atresia (4/18) were associated with the uterine anomalies of bicornuate or unicornuate uterus.

Two possible etiopathogenic causes may result in this rare condition of partial absence of fallopian tube: congenital absence or torsion. Congenital absences are frequently associated with developmental alterations of the mesonephric and paramesonephric ducts. The mesonephric duct becomes apparent in the embryo at approximately five weeks, while the

pair of paramesonephric ducts, located laterally to the mesonephric ducts, become apparent at about seven weeks. The lower segment of the paramesonephric duct grows caudally from its original position, to cross the mesonephric duct and fuse with the contralateral paramesonephric duct. The upper segment of the paramesonephric duct, which lies lateral to the mesonephric duct, subsequently differentiate into the lateral part of the fallopian tube. The part of the duct that crosses the mesonephric duct differentiates into the mid portion of the tube, while the fused segment forms the uterus and proximal 4/5ths of the vagina^{8,9}. Combined congenital absence of the mesonephric and paramesonephric ducts results in the absence of the uterine horn, fallopian tube, kidney, and ureter on the affected side. Partial unilateral paramesonephric duct defects result in failure of development of varying amounts of the fallopian tube. Inadequate blood supply to the caudal part of the paramesonephric duct during development may also result in the failure of fallopian tube formation^{8,9}.

A torsion of the uterine adnexa is not a uncommon condition, comprising a gynecologic emergency typically accompanied by severe clinical symptoms. Symptoms may, however, be mild or even absent, especially when occurring during pregnancy⁸. Torsion of the fallopian tube and/or ovary may even occur in childhood or in utero¹⁰. Asymptomatic torsion consequently leads to avascular necrosis and reabsorption of the tissue (fallopian tube and/or ovary)^{8,11}. Isolated torsion of the fallopian tube is extremely rare. Although Hansen estimated the incidence as occurring in one in 1.5 million women¹², it may occur more often, at least 60 case reports were identified by a comprehensive literature search, including our case of isolated tubal torsion in a 15 year-old girl¹³. The suggested causes for torsion of the fallopian tube include intrinsic causes, such as excessive length or spiral course of the fallopian tube, hematosalpinx or hydrosalpinx, neoplasma, or long mesosalpinx, and extrinsic causes, including paraovarian cyst, uterine enlargement by pregnancy or tumor, adhesions, pelvic congestion leading to spiraling of the veins of the mesosalpinx, and hypermobility of the fallopian tube¹⁴. Recently, two similar cases of ovarian and tubal absence due to adnexal torsion were reported^{11,15}, one case of unilateral ovarian absence with a twisted fallopian tube¹¹ and one case of a unilateral fallopian tube defect with twisted adnexa (ovary and infundibulopelvic ligaments)¹⁵.

As for the frequencies of these conditions, Uckuyu *et al.* reported three cases of partial tubal absence, and the incidence of three in 2,550 (one in 850) females underwent laparoscopy or laparotomy at their institute¹⁶. Our comprehensive literature research, including 19 cases reported by Nawroth, showed that only three out of 30 patients with partial absence of the fallopian tube were complicated with ipsilateral ovarian absence (one case with absence of the proximal portion and two cases with absence of the distal portion of the fallopian tube)^{3,8,9,15–21}. In addition, Sevanesaratnam suggested that the incidence of unilateral congenital ovarian and fallopian tube agenesis is one in 11,240²².

For most of the cases reported to date, the true etiologies of partial absence of the fallopian tube remain unclear. However, the absence of any other anatomical structures such as uterine or renal abnormalities would suggest that torsion or a vascular accident, rather than a developmental anomaly, is the likely cause¹⁶.

The unilateral absence of a fallopian tube, in conjunction with a normal contralateral tube

and uterus, may have less influence on infertility. Although our patient did not have a past history of acute abdominal pain, her condition may have resulted from an asymptomatic torsion of the fallopian tube during childhood or in utero, as no other associated morphological urogenital anomalies were identified.

CONCLUSION

Congenital unilateral absence of a portion of the fallopian tube is quite rare. Two possible causes of this condition include congenital absence associated with Müllerian anomalies or asymptomatic torsion. Adnexal torsion may occur asymptotically during adulthood, especially during pregnancy, or may happen during childhood or even in utero. It is important to recognize that asymptomatic or minimally symptomatic adnexal torsion may be followed by auto-amputation and reabsorption of the fallopian tube.

REFERENCES

1. Semmens JP. Congenital anomalies of the female genital tract. Functional classification based on review of 56 personal cases and 500 reported cases. *Obstet Gynecol*, **19** : 328-350, 1962.
2. Woolf RB, Allen WM. Concomitant malformations : the frequent simultaneous occurrence of congenital malformations of the reproductive and urinary tracts. *Obstet Gynecol*, **2** : 236-265, 1953.
3. Nawroth F, Nugent W, Ludwig M. Congenital partial atresia of the fallopian tube. *Reprod Biomed Online*, **12** : 205-208, 2006.
4. Acien P, Acien M, Sanchez-Ferrer M. Complex malformations of the female genital tract. New types and revision of classification. *Hum Reprod*, **19** : 2377-2384, 2004.
5. Grimbizis GF, Camus M, Tarlatzis BC, Bontis JN, Devroey P. Clinical implications of uterine malformations and hysteroscopic treatment results. *Hum Reprod Update*, **7** : 161-174, 2001.
6. Beyth Y, Kopolovic J. Accessory tubes, a possible contributing factor in fertility. *Fertil Steril*, **38** : 382-383, 1982.
7. Daw E. Duplication of the uterine tube. *Obstet Gynecol*, **42** : 137-138, 1973.
8. Eustace DL. Congenital absence of fallopian tube and ovary. *Eur J Obstet Gynecol Reprod Biol*, **46** : 157-159, 1992.
9. Paternoster DM, Costantini W, Uglietti A, Vasile C, Bocconi L. Congenital or torsion-induced absence of fallopian tubes. *Minerva Gynecol*, **50** : 191-194, 1998.
10. Dresler S. Antenatal torsion of a normal ovary and fallopian tube. *Am J Dis Child*, **131** : 236, 1977.
11. Uckuyu A, Ozcimen EE, Ciftci FCS. Unilateral congenital ovarian absence with twisted tube. *J Minim Invasive Gynecol*, **16** : 126-127, 2009.
12. Hansen OH. Isolated torsion of the fallopian tube. *Acta Obstet Gynecol Scand*, **49** : 3-6, 1970.
13. Yazawa H, Suganuma R, Sugawara N, Furukawa S, Takahashi H. Two cases of tubal torsion treated with laparoscopic surgery. -A case of isolated torsion of hydrosalpinx and a case of tubal torsion with paraovarian cyst-. (in Japanese). *Jpn J Gynecol Obstet Endoscopy*, **23** : 104-108, 2007.
14. Antoniou N, Varras M, Akilivis C, Kitsiou E, Stefanaki S, Salanalekis E. Isolated torsion of the fallopian tube : a case report and review of the literature. *Clin Exp Obstet Gynecol*, **31** : 235-238, 2004.
15. Sankaran S, Shahid A, Odejinmi F. Autoamputation of the fallopian tube after chronic adnexal torsion. *J Minim Invasive Gynecol*, **16** : 219-221, 2009.

16. Uckuyu A, Emel E, Ozcimen, Ceylan F, Ciftci S. Unilateral congenital ovarian and partial tubal absence : report of four cases with review of the literature. *Fertil Steril*, **91** : 936.e5-e8, 2009.
17. Lavanya R, Urala MS. Segmental absence of the fallopian tube – a rare anomaly. *Int J Gynecol Obstet*, **47** : 175-176, 1994.
18. Dahan MH, Burney R, Lathi R. Congenital interruption of the ampullary portion of the fallopian tube. *Fertil Steril*, **85** : 1820-1821, 2006.
19. Suh BY, Kalan MJ. Septate uterus with left fallopian tube hypoplasia and ipsilateral ovarian agenesis. *J Assist Reprod Genet*, **25** : 567-569, 2008.
20. van der Veldt AA, Kleij SA, Pernet PJ, Oostra RJ, Jansweijer MC. Unilateral partial absence of the fallopian tube in Williams syndrome : a new feature?. *Clin Dysmorphol*, **16** : 195-196, 2007.
21. Cheung VY. Congenital atresia of the fallopian tube. *J Obstet Gynecol*, **30** : 11-12, 2008.
22. Sivanesaratnam V. Unexplained unilateral absence of ovary and fallopian tube. *Eur J Obstet Gynecol Reprod Med*, **22** : 103-105, 1986.