

[Case Report]

**COCHLEAR IMPLANTATION IN A CASE OF BILATERAL
SENSORINEURAL HEARING LOSS DUE TO MUMPS**

YUKIE SUZUKI¹⁾, HIROSHI OGAWA²⁾, YOKO BABA³⁾, TERUHISA SUZUKI²⁾,
NAOKO YAMADA¹⁾ and KOICHI OMORI²⁾

¹⁾*Fukushima Rehabilitation Center for Children, Koriyama, 963-8041, Japan,* ²⁾*Department of Otolaryngology-Head and Neck Surgery, Fukushima Medical University School of Medicine, Fukushima, 960-1295, Japan,* ³⁾*BABA clinic, Nihonmatsu, 969-1404, Japan*

(Received July 24, 2008, accepted February, 2009)

Abstract : It is well known that unilateral profound sensorineural hearing loss is caused by mumps ; however, bilateral deafness is rare. Herein we report a case of bilateral profound hearing loss caused by mumps infection in a four-year-old boy. Labyrinthitis due to the mumps virus was suspected. His verbal understanding was poor, and he completely stopped talking. He was soon fitted with a hearing aid, but it proved insufficient. Thereupon, cochlear implantation was performed on his left ear. Six months after the operation, his speech perception and speech production were improved. In cases of bilateral profound hearing loss due to mumps infection conservative therapy is ineffective ; therefore, cochlear implantation is recommended. Vaccine coverage for mumps virus is also strongly recommended in Japan.

Key words : mumps, hearing loss, cochlear implantation

INTRODUCTION

Mumps is a very common childhood illness, particularly in those parts of the world where specific immunization has not been introduced. Mild-to-moderate unilateral hearing loss is a well-known symptom, whereas bilateral profound hearing loss is very rare¹⁾. Herein we present a case of bilateral profound hearing loss caused by mumps infection. Based on the results of this case, we suggest that early surgical intervention using a cochlear implant is beneficial in preventing delays in speech and language development.

鈴木雪恵, 小川 洋, 馬場陽子, 鈴木輝久, 山田奈保子, 大森孝一

Corresponding author : K. Omori E-mail : omori@fmu.ac.jp

<http://fmu.ac.jp/home/lib/F-igaku/> <http://www.sasappa.co.jp/online/>

CASE REPORT

A boy aged 4 years 2 months fell ill with a high fever, nausea, epigastralgia, and bilateral tender parotid swelling on February 24, 2006. His verbal understanding deteriorated, and he completely stopped talking on February 27. This sudden onset of deafness was noted by his parents. His quality of life was extremely low, and he could not be separated from his parents. He and his family experienced a very traumatic period. The child was brought to our hospital on March 2, 2006.

He did not complain of either tinnitus or vertigo, and his bilateral tympanic membranes and external auditory canals were normal. Auditory steady state response (ASSR) at a sound pressure level of 110 dB was present at low frequencies (500 Hz, 1,000 Hz) in both ears, but was absent at high frequencies (2,000 Hz, 4,000 Hz). On the basis of audiogram testing, bilateral hearing levels were found to be 100 dB at high frequencies (Fig. 1). These audiological examinations confirmed bilateral profound sensorineural hearing loss.

The child had no family history of sensorineural hearing loss. His development milestones in all fields were normal for the first four years of life. He had not received a mumps vaccination.

Serum mumps-specific IgM and IgG antibody levels were found to be 18.50 (Negative <0.8) and 29.80 (Negative <2.0), respectively, by the EIA method on

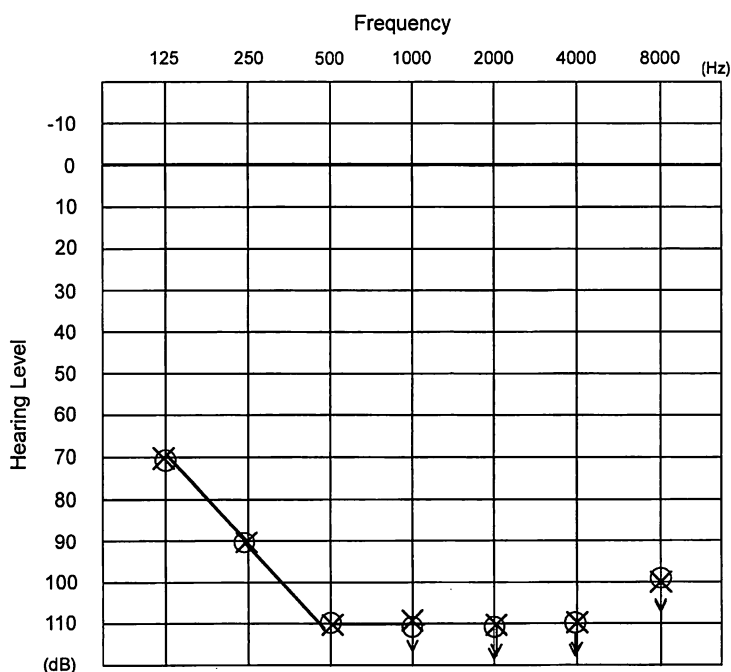


Fig. 1. Preoperative audiogram (March 14, 2006)

March 2, and 14.99 (Negative <0.8) and 34.50 (Negative <2.0), respectively, on March 14 (Table 1). Serum was negative for other IgM antibodies specific for viruses including varicella zoster, measles, rubella, and herpes simplex. It was concluded, on the basis of symptoms and antibody level, that his bilateral hearing loss was caused by a mumps infection. Mecobalamin was administered for 1 week, but his hearing did not recover. Thereafter, he was fitted with a hearing aid, but his hearing only recovered up to 80 dB, which was insufficient. On April 24, he underwent cochlear implant surgery using a CI 24M cochlear implant device for the left ear (Cochlear Co., Ltd, Australia). As many platinum ring electrodes as possible were inserted into the cochlear (at least 28 platinum ring electrodes; Fig. 2). The sound processor was connected and turned on 2 weeks after the cochlear implantation. The child was very agitated during the period of his hearing loss and his behavior changed abruptly. However, when the individual channels were first switched on, he became very calm and was able to concentrate. Continuous use of the implant device was started, and after 6 months of cochlear implant rehabilita-

Table 1. Serum mumps-virus specific IgM and IgG antibody titers (normal range)

	IgM Antibody (Negative <0.8)	IgG Antibody (Negative <2.0)
March 2, 2007	18.50	29.8
March 14, 2007	14.99	34.50

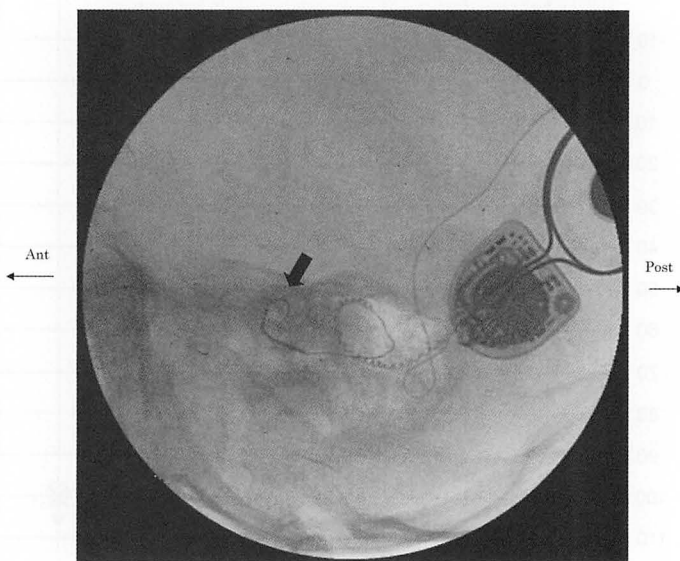


Fig. 2. As many electrodes as possible (24+4 platinum ring electrodes) were introduced to the target location (electrodes are indicated by an arrow)

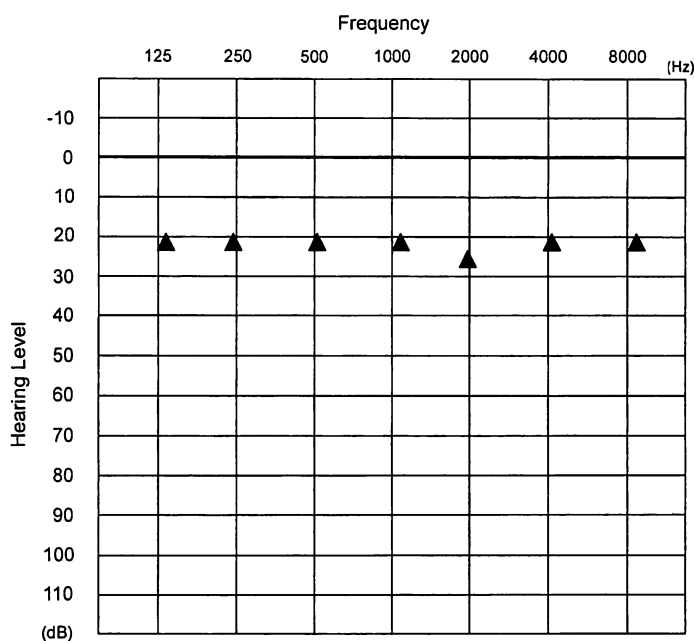


Fig. 3. Audiogram (aided sound-field thresholds using the cochlear implant device) (December 15, 2006)

tion, he recovered hearing up to 26 dB by aided sound-field thresholds using the cochlear implant (Fig. 3), and his Infant-Toddler Meaningful Auditory Integration Scale (IT-MAIS) score was 83%. His speech ability improved and he showed better understanding of conversations. He was able to return to his former nursery school.

DISCUSSION

Sensorineural hearing loss is a well-known complication ; however, as mumps-associated hearing loss is generally unilateral and occurs in patients aged between 5 and 9 years, it is often not immediately recognized by the patients or their parents³⁾. Nevertheless, for diagnosis, the temporal relationship between parotid swelling and hearing loss is important, and strict criteria for the diagnosis of mumps-associated deafness have been issued by the Acute Profound Deafness Research Committee (APDRC)²⁾. The incidence of sensorineural hearing loss after mumps has been estimated at 0.05/1,000 cases¹⁾. Mumps was also found to be the etiological factor in 0.6% of hearing-impaired children in special programs in the USA³⁾ and in 1% of deaf mutes¹⁾. The incidence of sensorineural hearing loss after mumps has been reported at between 1/30,000 and 1/2,000 cases⁴⁾.

On the basis of temporal bone histopathological examination, histological damage to the inner ear due to mumps has only been reported in two patients^{5,6)}.

Both showed atrophy and degeneration of the stria vascularis, tectorial membrane and organ of Corti, and also showed collapse of Reissner's membrane⁶⁾. The pathology of mumps infections in the inner ear is confined to structures in the endolymphatic system of the cochlea, and has been designated as endolymphatic labyrinthitis⁵⁾.

A proof that mumps can be the cause of deafness was the successful isolation of the virus, in a single unique instance, from the perilymphatic fluid of the inner ear in a patient during the acute phase of mumps⁶⁾. It was postulated that the virus penetrates the perilymphatic fluid in retrograde fashion via the cervical lymph nodes, then passes into the cerebrospinal fluid and hence into the perilymphatic zone⁶⁾. It is clear that deafness is generally not associated with mumps meningitis since none among more than 50 children suffering from proven mumps meningitis were found to have hearing loss⁷⁾.

A therapeutic regimen for sensorineural hearing loss has been previously outlined⁸⁾. Dextran is given to reduce blood viscosity and sludging, thereby improving vascular perfusion. Steroids, heparin and papaverine have been recommended to improve oxygenation of the affected area. Hyperbaric oxygen has been used for the same purpose⁹⁾. Bitnum *et al.* have instituted conventional methods for the intensive management of acute deafness to no avail⁴⁾. In addition, they have attempted therapy in a hyperbaric chamber in an effort to improve oxygenation of the organ of Corti. This, too, has proved ineffective. In such instances, an intensive regimen of speech and family therapy is recommended by Towne¹⁰⁾.

In this case, we administered mecobalamin, but his hearing did not recover. Thereafter, he was fitted with a hearing aid; however, his hearing level only improved to 80 dB, which was regarded as insufficient. If profound sensorineural hearing loss is left untreated, it can lead additional delays in language development and dysarthria. Therefore, our patient underwent cochlear implant surgery, after which he showed hearing up to 26 dB. Thereafter his speech improved, and he has been able to return to his former nursery school.

Conservative therapies such as the administration of steroids and vasodilators offer little help in cases of mumps-associated hearing loss. Hearing aids and speech training are very important for speech production after cochlear implantation. Therefore, it is necessary to diagnose bilateral profound sensorineural hearing loss associated with mumps infection and to surgically intervene with a cochlear implant as soon as possible.

As the prevalence of mumps declines, there is a corresponding decline in mumps-associated deafness. We have re-examined the usefulness of mumps vaccination by clarifying the ratio of the incidence of mumps epidemics and mumps-associated deafness. In Japan, a voluntary mumps vaccination program began in 1981 and parents have been allowed to choose a measles-mumps-rubella (MMR) vaccination instead of the monovalent measles vaccine used for routine immunization since April 1989. It was found that during the period from 1990 through the first

half of 1993, the number of mumps cases was low ; however, nation-wide surveillance identified an incidence of approximately one case of post-vaccination aseptic meningitis per 1,000 (0.1%) persons receiving the MMR vaccination containing the Urabe mumps strain¹¹⁾, so the Japanese Ministry of Health and Welfare withdraw all domestically produced MMR in April, 1993. Thereafter, according to the Infections Agents Surveillance Report (IASR), the incidence of mumps increased. Since then, mumps epidemics have recurred, beginning in the latter half of 2000 and showing a large peak in 2001. The annual number of mumps-associated deafness cases was estimated to be 300 in 1987, 400 in 1993 and 650 in 2001 based on the findings of APDRC. The National Epidemiological Surveillance of Infectious Disease (NESID) estimated the annual number of mumps cases to be 61,547 in 1987, 92,240 in 1993 and 254,711 in 2001, which confirms the correlation between the incidence of mumps and that of mumps-associated deafness. Aseptic meningitis caused by vaccination against mumps occurs as a complication in only about 1 case per 20,000-120,000 (0.0008%-0.005%) vaccinations¹²⁾. By contrast, the incidence of meningitis caused by natural infection is about 4-6%¹¹⁾. Based on data reported by WHO for the period up to April 1998, mumps vaccine is used in 23 of 25 (92%) developed countries¹³⁾. Notably, mumps-associated hearing loss has nearly vanished in most developed countries with high vaccine coverage. An effective vaccination program would prevent the development of several hundred cases of mumps-associated deafness each year in Japan. If the patient herein reported had received a mumps vaccination, he would not have experienced bilateral profound sensorineural hearing loss due to mumps. Therefore, we strongly recommend vaccine coverage for the mumps virus.

REFERENCES

1. Everberg G. Deafness following mumps. *Acta Otolaryngol*, **48** : 397-403, 1957.
2. Kawashima Y, Ihara K, Nakamura M, Nakashima T, Fukuda S, Kitamura K. Epidemiological study of mumps deafness in Japan. *Auris Nasus Larynx*, **32** : 125-128, 2005.
3. Jensema C. Children in educational programmes for hearing whose impairment is caused by mumps. *J Speech Hear Dis*, **10** : 164-169, 1975.
4. Bitnum S, Rakover Y, Rozen G. Acute bilateral total deafness complicating mumps. *J Laryngol Otol*, **100** : 943-945, 1986.
5. Lindsay JR, Davey PR, Ward PH. Inner ear pathology in deafness due to mumps. *Annals of Otology. Rhinology and Laryngology*, **69** : 918-935, 1960.
6. Westmore GA, Pritchard BH, Stern H. Isolation of mumps virus from the inner ear after sudden deafness. *British medical Journal*, **1** : 14-15, 1979.
7. Azimi PH, Cramblett HG, Haynes RE. Mumps meningoencephalitis in children. *Journal of the American Medical association*, **207** : 509-512, 1969.
8. Meyerhoff WL. The management of sudden deafness. *Laryngoscope*, **89** : 1867-1868, 1979.
9. Goto F, Fujita T, Kitani Y, Kanno M, Kamei T, Ishi H. Hyperbaric oxygen and stellate blocks for idiopathic sudden hearing loss, **88** : 335-343, 1979.

10. Towne CC. Speech and language development and disorders. *In*: Behrman RE, Vaughan VC, eds. Nerson's textbook of pediatrics. W.B. Saunders, London, 121-123, 1983.
11. Ueda K, Miyazaki C, Hidaka Y, Okada K, Kusuhara K, Kadoya R. Aseptic meningitis caused by measles-mumps-rubella vaccine in Japan. *Lancet*, 456 : 7-8, 1995.
12. Infectious Agents surveillance Report, 24 : 5 : 1-2, 2003.
13. Galazka AM, Robertson SE, Kraigher A. Mumps and mumps vaccine. a global review, 77 : 3-14, 1999.