

## THE PATHOGENESIS AND TREATMENT OF IgA NEPHROPATHY

YUKIHIKO KAWASAKI

*Department of Pediatrics, Fukushima Medical University School of Medicine, Fukushima 960-1295  
Japan*

(Received April 21, 2008, accepted June 30, 2008)

**Abstract :** IgA nephropathy (IgAN) is one of the most common causes of glomerulonephritis in the world. The proliferative and crescentic forms of IgA are found in up to 30% of cases and are associated with nephritic-range proteinuria, accelerated hypertension, and accelerated decline toward ESRD. Thus, it is important to investigate the mechanism of the onset of IgAN and to identify the most appropriate treatment. We herein review the pathogenesis and treatment of IgA nephropathy. As to the pathogenesis, we found that CB4 provoked exacerbation of renal pathologic findings in HIGA mice via endothelial injury, IFN- $\gamma$  production, and dysfunction of the mesangial pathway and could possibly become one of the factors involved in the mechanism of the onset or evolution of human IgAN. As to the treatment of IgAN, we evaluated the efficacy of tonsillectomy plus prednisolone, warfarin, and dipyridamole including methylprednisolone pulse therapy (tonsillectomy plus pulse therapy) and prednisolone, warfarin, and dipyridamole including mizoribine (PWDM) for the treatment of diffuse IgAN in children. These therapies were effective in ameliorating the proteinuria and histological severity of patients with IgAN. Furthermore the detail investigations into the pathogenesis of IgAN and double-blind randomized control studies on children with IgAN will be necessary.

**Key words :** Chronic Glomerulonephritis, hyper IgA mice, viral infection, IgA nephropathy, MPGN, LN, MGN, Prednisolone, Mizoribine

### INTRODUCTION

IgA nephropathy (IgAN) is considered to be the most common form of glomerulonephritis in the world. Diagnosis of this condition is made when renal biopsy tissue demonstrates mesangial proliferation with glomerular immune complexes

---

川崎幸彦

Corresponding author : Yukihiko Kawasaki E-mail : kyuki@fmu.ac.jp  
<http://fmu.ac.jp/home/lib/F-igaku/> <http://www.sasappa.co.jp/online/>

that include IgA as the dominant or codominant immunoglobulin deposited; complement C3 deposition is almost always present and IgG and IgM deposits are also frequently detected. There is no reduction in serum complement levels and no detectable autoantibodies to renal antigens. Patients harbor circulating immune complexes composed of IgA, complement components, fibronectin, and collagen<sup>1,2)</sup>. As a result of the requirement of a renal biopsy for correct diagnosis, the true incidence is not known<sup>3)</sup>. Although IgAN is prevalent in all ethnic groups, Japan and Korea have some of the highest recorded incidence. For example, approximately 50% of all new cases of glomerulonephritis and 40% of all cases of end-stage renal disease (ESRD) in Japan are due to IgAN. This is in contrast to the United States and Western Europe, where IgAN accounts for 10% and 30% of glomerulonephritis cases, respectively<sup>4)</sup>. Although these disparities may reflect differences in public health awareness or the willingness of nephrologists to perform diagnostic biopsies, certain populations seem to have a genetic predisposition to the development of IgAN.

The clinical presentation of a typical flair includes the development of painless hematuria concurrent with the onset of a viral pharyngitis, gastroenteritis, or pneumonia. Approximately 30% to 40% of patients with IgAN will present with gross hematuria and renal dysfunction. IgAN has been generally regarded as a benign form of glomerulonephritis, with approximately 25% to 30% of patients reaching ESRD after 10 years<sup>5-7)</sup>. Clinical risk factors linked to progressive IgA disease include hypertension, proteinuria >1.0 g/24h, male gender, and persistent microscopic hematuria.

Thus, it is therefore important to investigate the mechanism of onset of IgAN and to ascertain the most appropriate treatment of IgAN. In the present study we review the pathogenesis and treatment of IgA nephropathy<sup>6-8)</sup>.

#### THE PATHOGENESIS OF IgAN

IgAN can recur after transplantation, indicating that extrarenal factors have a role in the development of the disease. Multiple pathogenic mechanisms, including aberrant glycosylation of IgA1, impaired response to mucosal antigens, delayed clearance of immune complexes from the circulation, and abnormal interaction with mesangial IgA receptors, have been proposed and have been reviewed elsewhere<sup>9,10)</sup>.

The clinical presentation of a typical flair includes the development of painless hematuria concurrent with the onset of a viral pharyngitis, gastroenteritis, or pneumonia, or other factors such as viruses, bacteria, eumycetes or food antigens are important to stimulate B lymphocytes to produce the circulating IgA1-immunocomplex<sup>6-10)</sup>. In our review, we paid particular attention to the relationship between IgAN and viral infection.

*Viral infection and Kidney injury*

There have been many reports on the relationship between viral infection and renal injury<sup>11-18</sup>. Clinically, viral infection has often been noted to provoke transient proteinuria, hematuria, and renal dysfunction. The role of viruses in the pathogenesis and exacerbation of human renal diseases is not well understood, although it is likely that in acute infections, viruses have direct cytopathic effects on the renal tissue, whereas chronic long-standing infections may exert cytopathic effects via immune complexes<sup>19</sup>.

Recently, viral antigens were detected in renal tissues from patients with IgAN, and viral DNA has been identified with the polymerase chain reaction (PCR) technique or in situ hybridization<sup>18-24</sup>. Iwama et al. reported that Epstein-Barr virus (EBV)-specific DNA in renal biopsies was detected by PCR in seven (58%) of 12 patients with IgAN, three (50%) of six patients with membranous nephropathy, none (0%) of ten patients with minor glomerular abnormalities, and two (100%) of two patients with focal segmental lesions<sup>24</sup>. Enteroviruses are established or suspected etiological agents in numerous diseases. In particular, group B coxsackie viruses (CBs), which are enteroviruses, have been implicated in several diseases, including pancreatitis, insulin-dependent diabetes mellitus, myocarditis, and myositis [3-6]. They have also been reported to be etiological agents in some renal diseases. For example, induction of experimental nephritis by coxsackie B4 virus (CB4) was first described by Sun et al., and subsequent reports indicated relationships of CB4 with renal diseases in humans and experimental animals<sup>25</sup>. We reported positive PCR identification of the presence of enteroviral RNA for three of 10 patients with IgAN, and that enteroviral infection may play a role in the mechanism of onset or evolution of IgAN<sup>20</sup>. However, there have been no reports on the exacerbation of nephritis by viral infections or the mechanism of such exacerbation.

On the other hand, there have been reports on an IgAN model mouse. Muso *et al.* established an inbred murine model of IgAN, a high IgA strain (HIGA) of ddY mice, by selective mating of pooled crude ddY mice which have been reported to spontaneously develop mesangioproliferative glomerulonephritis with glomerular IgA deposition<sup>26</sup>. HIGA mice exhibited constantly high serum levels of IgA from 10-60 weeks of age with polymeric IgA dominant mesangial deposition and enhanced extracellular matrix accumulation.

To examine the renal effects of CB4 in IgAN, we evaluated renal injury following viral inoculation in HIGA mice<sup>27</sup>. We have performed three experiments as follows.

*Experiment 1: Administration of live and inactivated CB4 once a month from 2 to 12 months of age*

Seventy-five mice in the injected group were inoculated intravenously with 0.3 ml of  $10^7$  TCD<sub>50</sub> per 0.1 ml of live CB4 (Group A) and inactivated (Group B) CB4 once

a month from 1 to 12 months of age. Mice in the control group (Group C) were inoculated in a similar fashion with the supernatant of Vero cells not infected with CB4.

These mice were sacrificed once every 10 weeks from 10 to 50 weeks of age under chloroform anesthesia. Five mice in each group were sacrificed at 10, 20, 30, 40, and 50 weeks of age.

*Experiment 2 : Single intravenous administration of live and inactivated CB4 to mice at 6 weeks age*

Forty-five 6-week-old mice in the injected group were given a single intravenous inoculation with 0.3 ml of  $10^7$  TCD<sub>50</sub> per 0.1 ml of live (Group I) or inactivated (Group II) CB4. Mice in the control group (Group III) were inoculated in a similar fashion with the supernatant of Vero cells not infected with CB4. These mice were sacrificed at 6, 24 hours, or 5 days after administration under chloroform anesthesia.

*Experiment 3 : Single intravenous administration of colloidal carbon and CB4 to mice at 12 weeks of age*

Sixty mice in the injected group were inoculated intravenously once with 6 mg

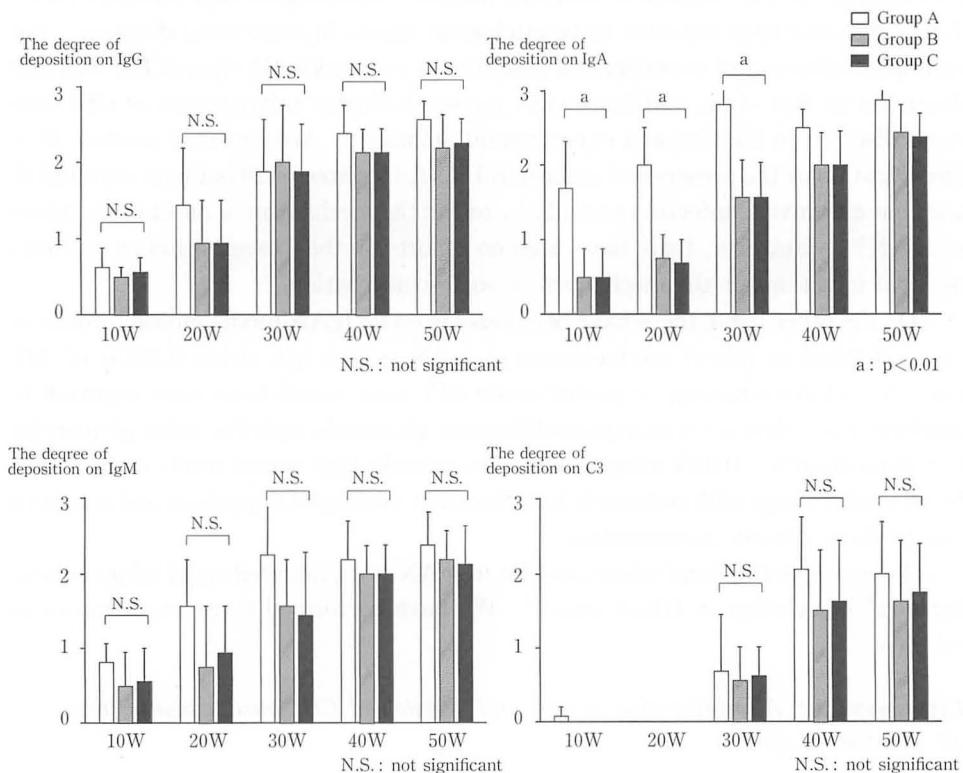


Fig. 1. Comparison of the degree of deposition of IgG, IgA, IgM, and C3 among the groups

per 0.1 ml of carbon (Pilot) and 0.3 ml of  $10^7$  TCD<sub>50</sub> per 0.1 ml of live (Group 1) or inactivated (Group 2) CB4 once at 12 weeks of age. Mice in the control group (Group 3) were inoculated in a similar fashion with the supernatant of Vero cells not infected with CB4. Five mice in each group were sacrificed at 12 hours, 36 hours, 5 days, and 10 days after administration. In all experiments, after cardiac puncture for blood sampling, the kidneys were removed, weighed, cut into portions, and used for assessment by light microscopy (LM), immunofluorescence (IF), immunohistochemical microscopy (IHM), and electron microscopy (EM).

We obtained the following results: Experiment 1): The degree of deposition of immunoglobulins (such as IgG, IgM, and IgA) and C3 are shown in Fig. 1. The degrees of deposition of IgA at 20 weeks were higher in Group A than in Groups B and C. The degrees of deposition of IgA from 10 weeks to 30 weeks of age were higher in Group A than in Groups B and C. The depositions of IgA are shown in Fig. 2. Glomerular IgA deposition was significantly shown at 20 weeks of age in Group

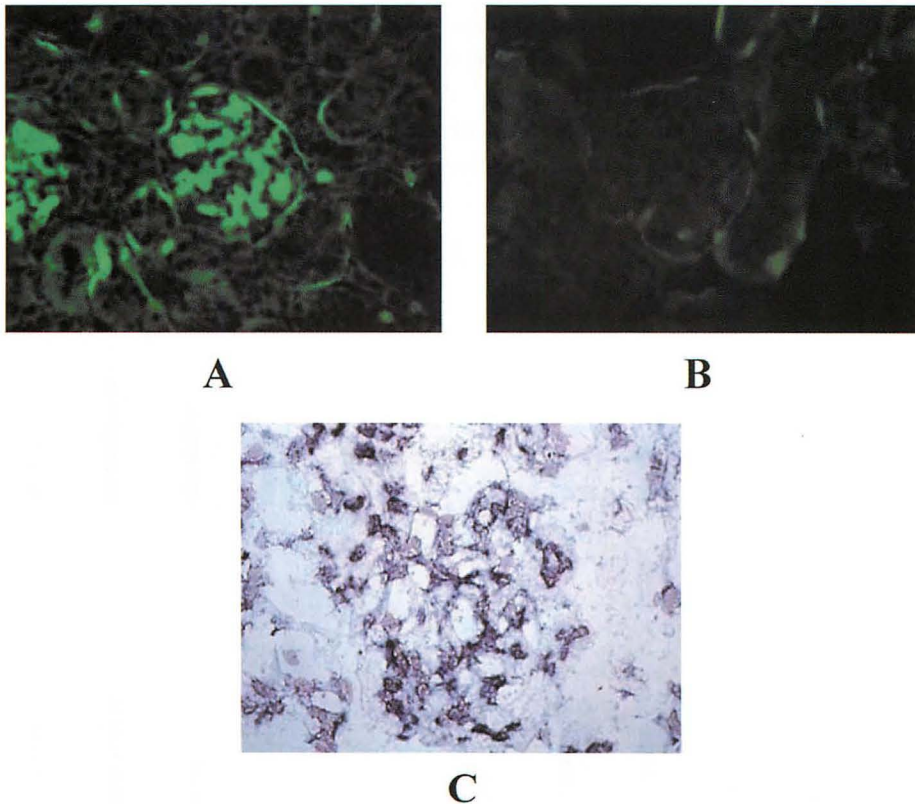


Fig. 2. A: Glomerular IgA deposition is significantly shown at 20 weeks of age in Group A ( $\times 400$ ).  
B: Glomerular IgA deposition is almost never shown at 20 weeks of age in Group C ( $\times 400$ ).  
C: At 20 weeks, strong positive signals are seen in the mesangial cells of Group A in situ hybridization ( $\times 400$ ).

A (Fig. 2-A) and glomerular IgA deposition was almost never shown at 20 weeks of age in Group C (Fig. 2-B).

The proportions of crescent formation from 10 weeks to 50 weeks of age were higher in Group A than in Groups B and C. The scores for PCNA-positive cells at 20 weeks were higher in Group A than in Groups B and C. The scores for PCNA-positive cells from 10 weeks to 20 weeks were higher in Group A than in Groups B and C (Fig. 3, 4). The scores for alpha-SMA-positive cells at 20 weeks were higher in Group A than in Groups B and C. The scores for alpha-SMA-positive cells from 10 weeks to 20 weeks were higher in Group A than in Groups B and C. Proportions of crescent formation, scores for PCNA-positive cells, and scores for alpha-SMA-positive cells did not differ between Groups B and C.

Matrix scores increased from 40 weeks to 50 weeks in each group. Matrix scores at 30 weeks were higher in Group A than in Groups B and C. Matrix scores from 20 weeks to 40 weeks of age were higher in Group A than in Groups B and C. At 20 weeks, strong positive signals were seen in mesangial cells of Group A and positive signals were not seen in mesangial cells of Groups B and C (Fig. 2-C).

Urinary protein from 10 weeks and 50 weeks of age was detected in Group A and was not detected in Groups B and C. At 30 weeks, urinary protein (mg/day) increased mildly in Group A compared with Groups B and C ( $1.9 \pm 0.8$  vs  $0.1 \pm 0.0$   $p < 0.05$ ,  $1.9 \pm 0.8$  vs  $0.1 \pm 0.0$   $p < 0.05$ , respectively). Serum IgA concentrations (mg/dl)

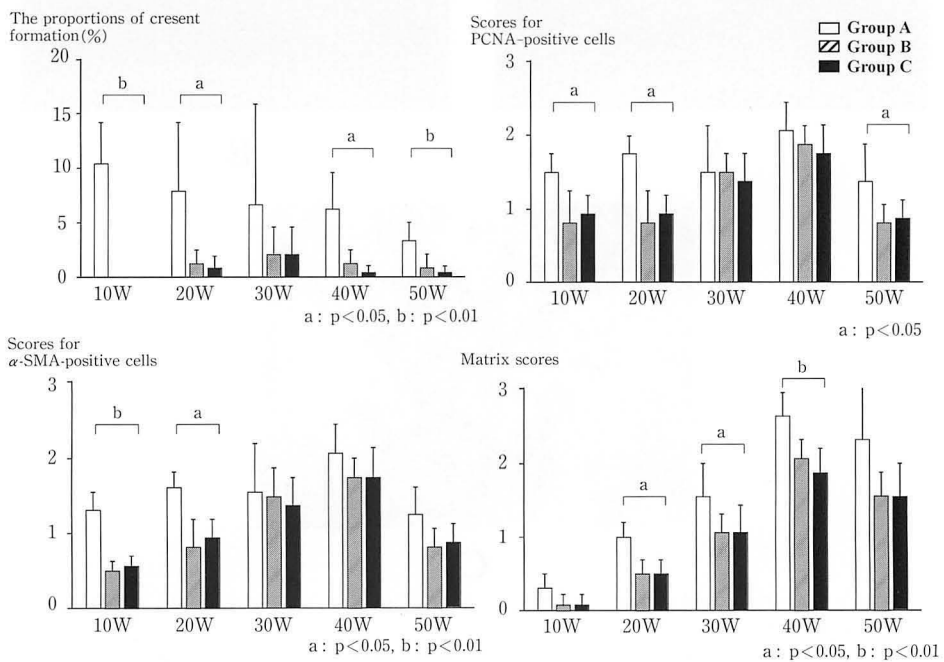


Fig. 3. Comparison of the proportions of crescent formation, scores for PCNA-positive cells, scores for alpha-SMA-positive cells, and matrix scores among the three groups.

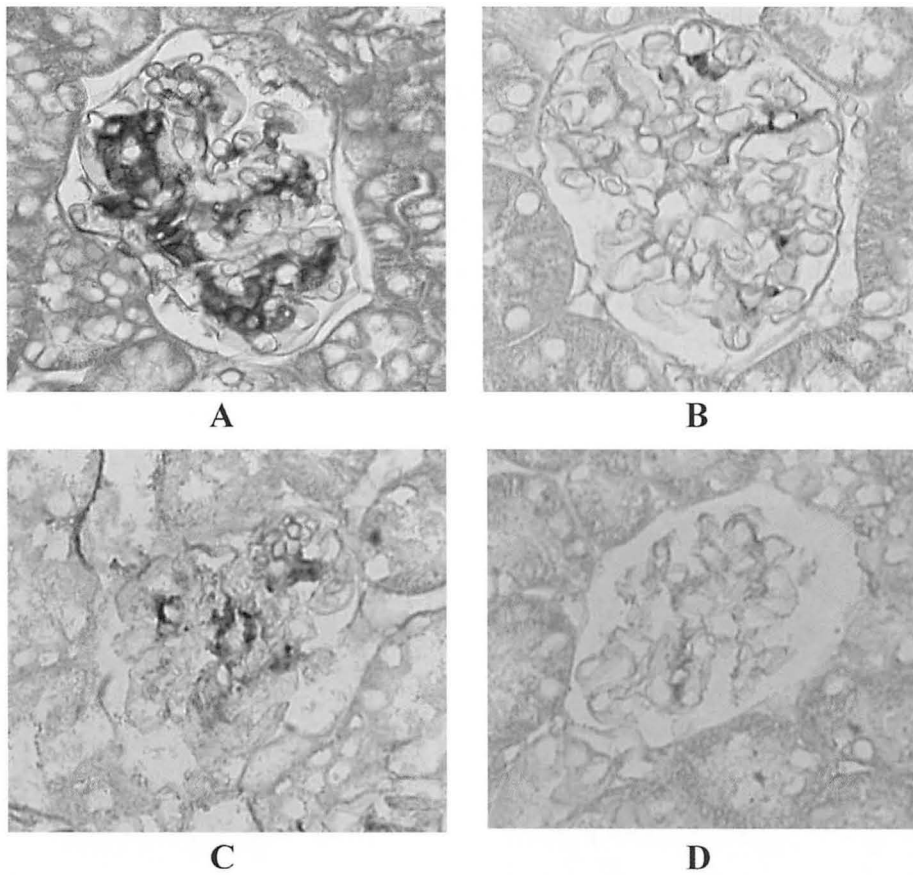


Fig. 4. A : PCNA positive cells are frequently found in the glomeruli at 20 weeks in Group A.  
 B : PCNA positive cells are not seen in the glomeruli at 20 weeks in Group C.  
 C : Alpha-SMA-positive cells are frequently expressed in the glomeruli at 20 weeks in Group A.  
 D. Alpha-SMA-positive cells are not expressed in the glomeruli at 20 weeks in Group C.

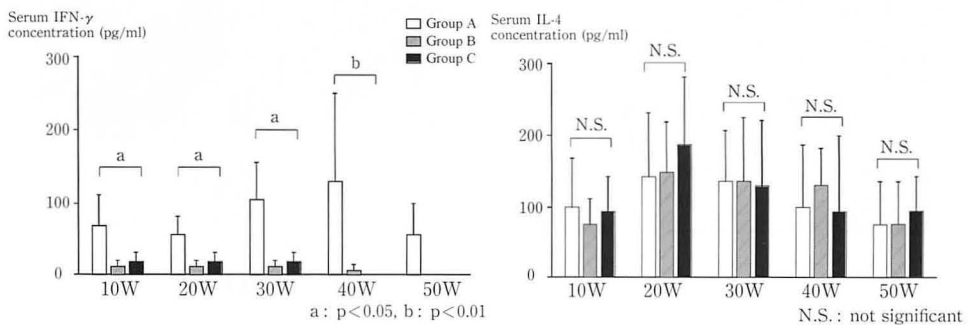


Fig. 5. Comparison of serum IFN-gamma and IL-4 concentrations among the three groups.



increased markedly after 30 weeks in all three groups, and did not differ among them. Serum IFN- $\gamma$  concentration increased from 10 weeks to 40 weeks in Group A, and serum IFN- $\gamma$  concentration was hardly detected in Groups B and C (Fig. 5). Serum IL-4 concentration increased from 10 to 50 weeks in Groups A, B, and C, with no differences in concentration among the three groups.

*Experiment 2) : Comparison of the pathological findings among the groups (Fig. 6)*

On LM examination, the proliferation and matrix scores did not differ among the three groups. On EM examination, swelling and detachment of endothelial cells from 3 hours to 5 days after inoculation were found in all mice of Group I, whereas none from 3 hours to 5 days were found in all mice of Groups II and III. Swelling and detachment of endothelial cells was more frequently found in Group I than in Groups II and III.

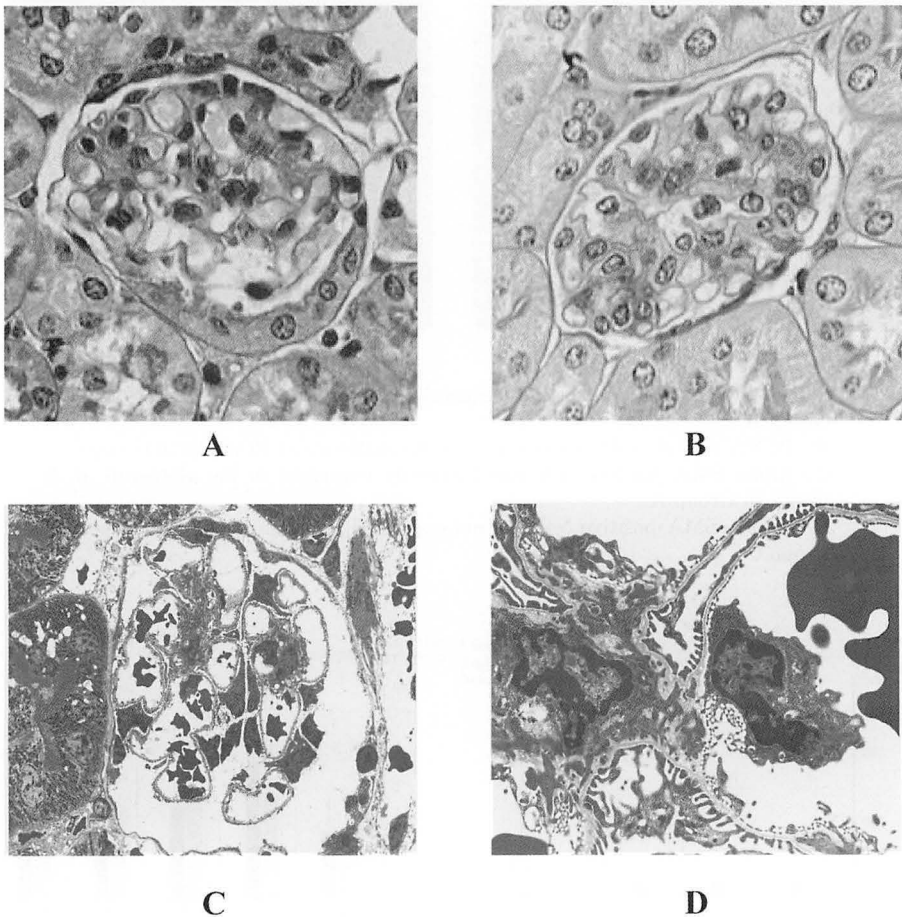


Fig. 6. Pathological findings in experiment 2.  
Swelling and detachment of endothelial cells at 24 hours of age after inoculation are seen in Group I. ( $\times 800$ , A) ( $\times 2,500$ , B)



*Experiment 3): Many carbon particles were present in the peripheral and central zones of the mesangium from 5 to 10 days in mice with carbon and live CB4 (Fig. 7)*

Our findings showed that CB4 promoted IgA deposition in mesangial lesions and increased mesangial cell and matrix proliferation in the glomeruli of HIGA mice. Endothelial cell injury and crescent formation were more frequently found in HIGA mice with live CB4 than in HIGA mice without CB4 and HIGA mice with inactivated CB4.

The mechanism of exacerbation of renal injury by viral infection is still unclear. However, there has been some speculation regarding the mechanism of exacerbation of renal injury by CB4 infection. With recent advances in immunopathological and molecular biological techniques, it has become possible to clarify the mechanisms of induction of glomerulonephritis by viruses. There are two explanations for the

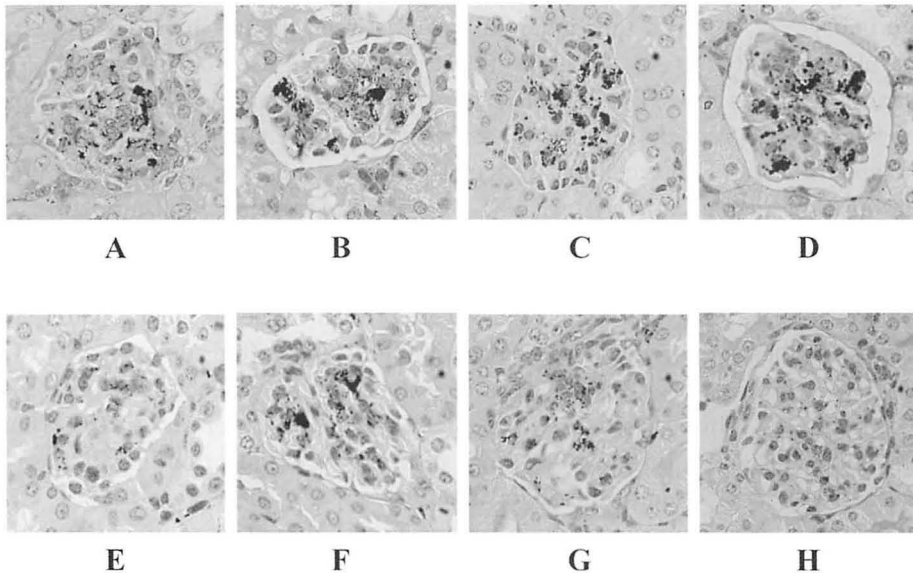


Fig. 7. Comparison of the pathological findings of experiment 3 between groups 1 and 3. (A) Large carbon particles are present in the surrounding capillary lumina from 12 h after administration in group 1. (B) Large carbon particles are still present in the capillary lumen, and the mesangium contains small amounts of carbon particles at 36 h after administration in group 1. (C) Many carbon particles are present in the peripheral and central zones of the mesangium from 5 d after administration in group 1. (D) Many carbon particles are still present in the peripheral and central zones of the mesangium from 10 d after administration in group 1. (E) Large carbon particles are present in the surrounding capillary lumina at 12 h after administration in group 3. (F) moderate numbers of carbon particles are present in the peripheral zone of the mesangium at 36 h after administration in group 3. (G) Many carbon particles are present in the peripheral and central zones of the mesangium and laci cell areas at 5 d after administration in group 3. (H) Most carbon particles have disappeared from the mesangium and laci areas at 10 d after administration in group 3.

renal injury. First, direct injury by viruses can cause renal injury. In our study, the detachment and swelling of endothelial cells were more frequently found in HIGA mice with CB4 than in HIGA mice without CB4 and HIGA mice with inactivated CB4. These findings showed that CB4 directly injured glomerular endothelial cells. In addition, the serum IFN- $\gamma$  concentration in HIGA mice with live CB4 was higher than in both HIGA mice without CB4 and HIGA mice with inactivated CB4. IFN- $\gamma$  is the major cytokine secreted from T-helper 1 cells and promotes cellular immunity including macrophages and natural killer cells<sup>28</sup>. CB4 promoted IgA deposition in mesangial lesions and mesangial cell and matrix proliferation in the glomeruli of HIGA mice, and crescent formation and infiltration by macrophages were more frequently observed in HIGA mice with live CB4. IFN- $\gamma$  might have caused these pathological changes. Thus, direct injury and mediators such as IFN- $\gamma$  produced by viral infection in the glomerulus may play important roles in the etiology of these pathological changes.

Second, dysfunction of the mesangial pathway induced by viruses can cause renal injury<sup>29,30</sup>. As to a functional pathway between the mesangium and juxtaglomerular apparatus (JGA), Leiper JM et al. reported that the iron-dextran complex as tracer particles was initially taken into the matrix channels of the mesangium from which it progressed over the course of 8 hours to the matrix of the juxtaglomerular apparatus and intercellular spaces of the macula densa and the above-mentioned mesangial pathway, which is a continuous functional pathway from the glomerular capillary lumen to the macula densa cells of the distal tubule for material taken up by the mesangium<sup>29</sup>.

In our results, many carbon particles were present in the peripheral and central zones of the mesangium from 5 to 10 days in HIGA mice after administration with live CB4. These findings suggest that mesangial pathway function decreased in HIGA with CB4. In addition, IgA concentrations did not differ among the groups. These findings suggest that low clearance of IgA by CB4 infection might cause an increase in the deposition of mesangial IgA.

There has been some speculation concerning renal injury by immune complexes<sup>25,31</sup>. Immune complexes consist of antigen and antibody, and the antigen may be a virus or renal tissue injured by viral infection. Deposition of these immune complexes in the mesangium and basement membrane can cause renal injury. However, in our study, the pathological examination results did not differ between HIGA without CB4 and HIGA with inactive CB4. Thus, immune complexes induced by inactive CB4 may not cause renal disease in our model.

We conclude that CB4 provokes exacerbation of renal pathological findings in HIGA mice via endothelial injury, IFN- $\gamma$  production and dysfunction of the mesangial pathway.

## TREATMENT OF IgA NEPHROPATHY

IgAN is a leading cause of chronic renal disease and end-stage renal disease in adult patients, and recent long-term studies assessing the prognosis in children have challenged earlier views that the condition represents a benign disorder. Thus IgAN presents a therapeutic challenge in both adults and children.

There have been many reports on the treatment of the abnormal state of immunity in childhood IgAN. In 1972, McEnery et al. reported that treatment of four children with mild IgAN with one month of daily prednisolone followed by alternate-day prednisolone for about one year resulted in a decrease in the frequency of episodes of macroscopic hematuria and resolution of microscopic hematuria<sup>32)</sup>. In 1989, Andreoli and Bergstein demonstrated the efficacy of 1 year of treatment with prednisolone and azathioprine in 10 children with severe IgAN<sup>33)</sup>. Yoshikawa et al. reported the beneficial effects of multiple-drug therapy consisting of prednisolone, azathioprine, heparin-warfarin, and dipyridamole, for severe childhood IgAN<sup>34)</sup>. These results demonstrated the efficacy of multiple drug combination therapies for IgAN.

*Action and side effects of each drug in multiple drug combination therapies including prednisolone, immunosuppressive drugs, warfarin, and dipyridamole*

*Corticosteroids*

Corticosteroids inhibit T cell proliferation, T cell-dependent immunity, and cytokine gene transcription (including Interleukine-1, IL-2, IL-6, interferon-gamma and tumor necrosis factor- $\alpha$  genes). While no individual cytokine can totally reverse the inhibitory effects of corticosteroids upon mitogen-stimulated T cell proliferation, a combination of cytokines is effective in restoring T cell proliferation<sup>35)</sup>.

*Immunosuppressive drugs**Azathioprine (AZP)*

Azathioprine is the 1-methyl-4-nitro-5-imidazolyl derivative of 6-mercaptopurine. Azathioprine, a purine analogue, functions as a purine antagonist and thereby inhibits cellular proliferation<sup>35)</sup>.

*Mizoribine (MZB)*

Mizoribine (p-INN : 4-carbamoyl-1- $\beta$ -D-ribofuranosyl imidazolium-5-olate) is an antibiotic agent produced by the soil fungus *Eupenicillium brefeldianum*<sup>36)</sup>. In the early 1980s, Japanese studies began to appear which demonstrated the inhibitory effects of MZB on T- and B-lymphocyte activity *in vitro* and examined the pharmacokinetics and immunosuppressive effects of MZB *in vivo*<sup>37-38)</sup>. In view of its inhibition of purine synthesis and its relative lack of toxicity, MZB has been used increasingly in Japan during the last decade instead of azathioprine as part of

immunosuppressive drug regimens: it was first approved by the Ministry of Health and Welfare of Japan as a drug indicated for the prevention of rejection in renal transplantation in 1984, and since then the indication has been extended to lupus nephritis in 1990, rheumatoid arthritis in 1992, and primary nephritic syndrome in 1995<sup>39)</sup>.

In the following section I give an outline mainly on our reports but including other reports on multiple drug combination therapies for IgAN.

*A. Retrospective studies reports on the efficacy of multiple drug combination therapies*

Since 1990, corticosteroids, immunosuppressive agents, antiplatelet drugs, and anticoagulation have been used alone or in combination to treat IgAN<sup>33,34,39-45)</sup>. However, there have been no reports comparing the efficacy of the above treatments. To evaluate the efficacy of multiple-drug therapy combined with MZB (PWDM) for diffuse IgAN in childhood, we compared the clinical features and pathological findings of diffuse IgAN patients treated with PWDM with those of patients who received multiple-drug therapy without MZB (PWD) and combined with methylprednisolone pulse therapy (PWD-pulse)<sup>46)</sup>.

We collected data on 61 patients who had been diagnosed as having diffuse IgAN in the Department of Pediatrics of Fukushima Medical University School of Medicine between 1984 and 1993. The patients were retrospectively divided into three groups without randomization. The duration from initiation of therapy in the PWD group, PWD-pulse group, and PWDM group were  $8.9 \pm 5.2$ ,  $8.1 \pm 3.9$ , and  $7.7 \pm 3.8$  year, respectively. At the latest follow-up examination, the mean urinary protein excretion ( $\text{mg}/\text{m}^2/\text{h}$ ) was  $17 \pm 10$  in PWD group,  $22 \pm 20$  in PWD-pulse group, and  $6 \pm 6$  in PWDM group, and had decreased significantly in PWDM group compared to the other groups. The activity index in all three groups was lower at the second biopsy than at the first biopsy ( $5.1 \pm 0.8$  vs  $6.5 \pm 2.1$  in Group A,  $p < 0.05$ ;  $5.6 \pm 0.9$  vs  $6.6 \pm 1.7$  in Group B,  $p < 0.01$ ; and  $4.5 \pm 1.0$  vs  $6.8 \pm 1.9$  in PWDM group,  $p < 0.01$ ). The chronicity index in the PWD group and PWD-pulse group at the second biopsy was higher than at the first biopsy ( $7.3 \pm 1.4$  vs  $4.8 \pm 1.0$  in PWD group,  $p < 0.01$ ;  $8.1 \pm 2.0$  vs  $5.3 \pm 0.9$  in PWD-pulse group,  $p < 0.01$ ), but was unchanged in the PWDM group. At the latest follow-up examination, one patient (4.8%) in the PWD group, 3 (15%) in the PWD-pulse group, and none (0%) in PWDM group had renal insufficiency. These results suggest that PWDM appears to be more effective than PWD or PWD-pulse in ameliorating the proteinuria and histological severity of patients with IgAN.

*B. Prospective studies reports on the efficacy of multidrugs combination therapies*

To date, there have been only a few reports concerning cocktail therapy, including prednisolone and MZB, for diffuse IgAN. In the present study, to evaluate the efficacy of prednisolone and MZB therapy for diffuse IgAN, we prospectively

investigated the pretherapy clinical manifestation and pathological findings in IgAN patients and compared these data with the post-therapy findings following prednisolone and MZB therapy<sup>47)</sup>.

Between January 1992 and December 1999, patients were eligible for the study if they had been biopsied and were newly diagnosed as having diffuse IgAN with severe proteinuria.

On entry into the study, medical histories were obtained from all patients, and all patients underwent a physical examination. Patients were followed-up once a month during the study.

The clinical features, the above laboratory data, pathological findings, and the prognosis between pre-therapy and post-therapy were prospectively investigated. The mean urinary protein excretion after 6 months of treatment had decreased significantly compared to pre-therapy.

The incidence of hematuria in post-therapy was lower than that of pre-therapy. The AI decreased significantly from  $4.8 \pm 2.1$  at the first biopsy to  $2.3 \pm 1.7$  at the second biopsy ( $p < 0.001$ ) and the CI decreased significantly from  $4.1 \pm 1.9$  at the first biopsy to  $2.7 \pm 2.4$  at the second biopsy ( $p < 0.05$ ). Macrophage infiltration and alpha-smooth muscle actin positive cells in the glomerulus and interstitial region decreased significantly in post-therapy compared with pre-therapy. At the most recent follow-up, none of the 34 patients had renal insufficiency. These findings suggested that prednisolone and mizoribine therapy is effective for those patients at risk of progression of IgAN.

Yoshikawa et al. has showed that treatment of children with severe IgA nephropathy (IgAN) using prednisolone, azathioprine, heparin-warfarin, and dipyridamole for 2 yr early in the course of disease reduced the severity of immunologic renal injury and prevented any increase in the percentage of sclerosed glomeruli<sup>34)</sup>. In addition, Yoshikawa presented a study comparing the effects of prednisolone, azathioprine, warfarin, and dipyridamole (combination) with those of prednisolone alone in 80 children with newly diagnosed IgAN that showed diffuse mesangial proliferation. Thirty-six (92.3%) of the 39 patients who received the combination and 29 (74.4%) of the 39 who received prednisolone reached the primary end point by the 2-yr follow-up point ( $P = 0.007$  log-rank). The percentage of sclerosed glomeruli was unchanged in the patients who received the combination but increased from  $3.1 \pm 4.8$  to  $14.6 \pm 15.2\%$  in the prednisolone group ( $P = 0.0003$ ). The frequency of adverse effects was similar in the two groups. It is concluded that combination treatment may be better for severe IgAN than treatment with prednisolone alone<sup>48)</sup>.

### *C. Studies on comparison of tonsillectomy plus steroid pulse and multidrugs combination therapies*

There have been several reports of the efficacy of tonsillectomy for IgAN in adults. Xie Y et al. reported that tonsillectomy had a significant beneficial effect on

the outcome, and in many studies tonsillectomy was performed in conjunction with immunosuppressive medication<sup>49)</sup>. Hotta et al. found that tonsillectomy combined with steroid pulse therapy reduced proteinuria and improved renal function in IgAN patients during a 5-year follow-up period<sup>50)</sup>.

There have also been several reports on the efficacy of tonsillectomy against IgAN in childhood. In 1985, Lozano et al. compared the clinical outcome of 8 patients who underwent tonsillectomy and 20 similar patients who did not and found that the patients in the tonsillectomy group had significantly fewer episodes of macroscopic hematuria than the controls<sup>51)</sup>. Maeda et al. observed improvement in the urinalysis data of all seven Japanese children with IgAN who underwent tonsillectomy<sup>52)</sup>. Wyatt RJ, on the other hand, claimed that tonsillectomy cannot be recommended for IgAN based on evidence-based criteria<sup>53)</sup>. To evaluate the efficacy of tonsillectomy plus pulse therapy against diffuse IgAN in childhood, we prospectively evaluated the efficacy of tonsillectomy plus pulse therapy without an immunosuppressant in the treatment of diffuse IgAN in comparison with PWD<sup>54)</sup>. The patients were randomly assigned to be treated with tonsillectomy plus pulse therapy for 2 years (Group A,  $n=16$ ) or PWD for 2 years (Group B,  $n=16$ ). The clinical features and pathological findings in both groups were analyzed prospectively. The mean urinary protein excretion after 6 months of treatment in both groups had decreased significantly compared to pre-therapy. The activity index in both groups was lower at the time of the second biopsy than at the time of the first biopsy. The chronicity index in Groups A and B did not differ between the first and second biopsies. At the latest follow-up examination none (0%) of the patients in either group had renal insufficiency. None of the patients in Group A, but 6 patients in Group B experienced an acute exacerbation of IgAN as a result of tonsillitis ( $p<0.05$ ).

The results of our study show that tonsillectomy plus pulse therapy reduced urinary protein excretion, and it appeared to be as effective as PWD in ameliorating histological severity and preventing acute exacerbation of IgAN by tonsillitis. Tonsillectomy plus pulse therapy and PWD had similar therapeutic effects. Severe side effects of the drug regimens were relatively rare, and tonsillectomy plus pulse therapy was well tolerated and safe in all patients. However, it is necessary to understand the risk of complications of tonsillectomy, because it is a surgical operation.

Although the mechanism of the favorable effect of tonsillectomy plus pulse therapy on IgAN is still unclear, previous studies have suggested that the tonsils are closely associated with the pathogenesis of IgAN<sup>49-52)</sup>. IgAN is initiated by glomerular deposition of polymeric IgA1. Tomino et al. demonstrated that antibodies eluted from the renal tissue of IgAN patients specifically bind to the nuclear region of tonsillar cells, and the binding between the eluted antibodies and tonsillar cells was completely inhibited by the addition of antihuman IgA antiserum<sup>55)</sup>. These findings indicate that at least some of the polymeric IgA1 deposited in the mesan-

gium is of tonsillar origin. Recurrent tonsillitis appears to be the most frequent extrarenal clinical manifestation of IgAN, and there are close temporal relationships between episodes of pharyngeal infection and bouts of hematuria and/or proteinuria<sup>56</sup>. The histological findings in the tonsils removed by tonsillectomy in our study revealed chronic tonsillitis in all patients, and these findings suggest a relationship between the tonsils and IgAN. Suzuki et al. reported finding antigens of the outer membranes of the common bacterium *Haemophilus parainfluenzae* on the tonsils of IgAN patients and antibodies to them in their glomerular mesangium and sera<sup>56,57</sup>. Thus, tonsillectomy may lead to the disappearance of lymphoid tissue that actively recruits activated IgA-producing cells and removal of a pharyngeal infectious focus, and that would partly explain the decrease in serum IgA level and mesangial IgA deposits, and subsequent remission of IgAN.

Hotta *et al.* have stated that tonsillectomy plus pulse therapy is more effective than tonsillectomy alone and that steroid pulse therapy after tonsillectomy reduces urine protein excretion and inhibits inflammatory responses<sup>50,58</sup>. In our study, I think that the treatment which combined tonsillectomy and steroid pulse therapy was effective for IgAN. The rationale for using tonsillectomy plus pulse therapy in IgAN in our study was that steroid pulse therapy and tonsillectomy reduce IgA production and minimize the abnormal immune response and inflammatory events following glomerular IgA deposition.

Although there was no untreated control group in this study, the results suggested that tonsillectomy plus pulse therapy is as effective as PWD in ameliorating proteinuria and histological severity in IgAN patients and in preventing acute exacerbation of IgAN by tonsillitis. However, a long-term follow-up study in children with IgAN is needed, because the observation period was short.

#### CONCLUSION

We have reviewed the pathogenesis of IgAN, especially the relationship between the onset and exacerbation of IgAN and viral infections, and treatment including multiple drug combination therapies for IgAN. Further detailed investigation of the pathogenesis of IgAN and a double-blind randomized control study for children with IgAN will be necessary.

#### REFERENCES

1. van Es LA, van den Wall Bake AW, Valentijn RM, Daha MR. Composition of IgA-containing circulating immune complexes in IgA nephropathy. *Am J Kidney Dis*, **12**: 397-401, 1988.
2. Baldree LA, Wyatt RJ, Julian BA, Falk RJ, Jennette JC. Immunoglobulin A-fibronectin aggregate levels in children and adults with immunoglobulin A nephropathy. *Am J Kidney Dis*, **22**: 1-4, 1993.
3. Stratta P, Segoloni GP, Canavese C, Sandri L, Mazzucco G, Roccatello D, Manganaro M,



- Vercellone A. Incidence of biopsy-proven primary glomerulonephritis in an Italian province. *Am J Kidney Dis*, **27** : 631-639, 1996.
4. Galla J. IgA nephropathy. *Kidney Int*, **47** : 377-387, 1995.
  5. Praga M, Guitierrez-Millet V, Navas J, Ruilope LM, Morales JM, Akcazar JM, Bello I, Rodicio JL. Acute worsening of renal function during episodes of macroscopic hematuria in IgA nephropathy. *Kidney Int*, **28** : 69-74, 1985.
  6. Donadio J, Grande J. Immunoglobulin A nephropathy : A clinical perspective. *J Am Soc Nephrol*, **8** : 1324-1332, 1997.
  7. D'Amico G. Natural history of idiopathic IgA nephropathy : Role of clinical and histological prognostic factors. *Am J Kidney Dis*, **36** : 227-237, 2001.
  8. Descamps-Latscha B, Witko-Sarsat V, Nguyen-Khoa T, Nguyen AT, Gausson V, Mothu N, Cardoso C, Noel LH, Guerin AP, London GM, Jungers P. Early prediction of IgA nephropathy progression : Proteinuria and AOPP are strong prognostic markers. *Kidney Int*, **66** : 1606-1612, 2004.
  9. Barratt J, Feehally J. IgA nephropathy. *J Am Soc Nephrol*, **16** : 2988-2097, 2005.
  10. Donadio JV, Grande JP. IgA nephropathy, **347** : 738-748, 2002.
  11. Burch GE, Colcolough HL. Progressive coxsackie viral pancarditis and nephritis. *Ann Intern Med*, **71** : 963-970, 1969.
  12. Burch GE, Chu KC, Colcolough HL, Sohal RS. Immunofluorescent localization of Coxsackie B antigen in the kidney observed at routine autopsy. *Am J Med*, **47** : 36-42, 1969.
  13. Bayatpour M, Zhitnew A, Dempster G, Miller KR. Role of coxsackievirus B4 in the pathogenesis of acute glomerulonephritis. *Can Med Assoc J*, **109** : 873-875, 1973.
  14. Belgiojoso GB, Ferrario F, Landriani N. Virus-related glomerular disease : histological and clinical aspects. *J Nephrol*, **15** : 469-479, 2002.
  15. Batisky DL, Roy S 3<sup>rd</sup>, Gaber LW. Congenital nephrosis and neonatal cytomegalovirus infection : a clinical association. *Pediatr Nephrol*, **7** : 741-743, 1993.
  16. Blowey DL. Nephrotic syndrome associated with an Epstein-Barr virus infection. *Pediatr Nephrol*, **10** : 507-508, 1996.
  17. Ohtomo Y, Kawamura R, Kaneko K, Yamashiro Y, Kiyokawa N, Taguchi T, Mimori K, Fujimoto J. Nephrotic syndrome associated with human parvovirus B19. *Pediatr Nephrol*, **18** : 280-282, 2003.
  18. Gregory M, Hammond ME, Brewer ED. Renal deposition of cytomegalovirus antigen in immunoglobulin-A nephropathy. *Lancet*, **2** : 11-14, 1988.
  19. Ronco P, Verroust P, Maroger LM. Viruses and glomerulonephritis. *Nephron*, **31** : 97-102, 1982.
  20. Takahashi A, Kawasaki Y, Yoshida K, Mochizuki K, Isome M, Honzumi K, Nozawa R, Suzuki S, Hosoya M, Suzuki J, Suzuki H. Detection of enteroviruses in renal biopsies from patients with immunoglobulin A nephropathy. *Pediatr Nephrol*, **20** : 1578-1582, 2005.
  21. Tomino Y, Yagame M, Omata F, Nomoto Y, Sakai H. A case of IgA nephropathy associated with adeno- and herpes simplex viruses. *Nephron*, **47** : 258-261, 1987.
  22. Müller GA, Müller CA, Blum GE, Kühn W, Risler T, Bohle A, Lipkovski JM. Human cytomegalovirus in immunoglobulin A nephropathy : Detection by polymerase chain reaction. *Nephron*, **62** : 389-393, 1992.
  23. Sinniah R, Khan TN, Dodd S. An in situ hybridization study of herpes simplex and Epstein Barr viruses in IgA nephropathy and non-immune glomerulonephritis. *Clin Nephrol*, **40** : 137-141, 1993.
  24. Iwama H, Horikoshi S, Shirato I, Tomino Y. Epstein-Barr virus detection in kidney biopsy specimens correlates with glomerular mesangial injury. *Am J Kidney Dis*, **32** : 785-793, 1998.
  25. Sun SH, Burch GE, Sohal RS, Chu KC. Coxsackie B4 viral nephritis in mice and its autoimmune-like phenomena. *Proc Soc Exp Biol Med*, **126** : 882-885, 1967.

26. Muso E, Yoshida H, Takeuchi E, Yashiro M, Matsushima H, Oyama A, Suyama K, Kawamura T, Kamata T, Miyawaki S, Izui S, Sasayama S. Enhanced production of glomerular extracellular matrix in a new mouse strain of high serum IgA ddY mice. *Kidney Int*, **50** : 1946-1957, 1996.
27. Kawasaki Y, Hosoya M, Isome M, Nozawa R, Suzuki H. Renal effects of Coxsackie B4 virus in hyper-IgA mice. *J Am Soc Nephrol*, **17** : 2760-2769, 2006.
28. Maraskovsky E, Chen WF, Shortman K. IL-2 and IFN-gamma are two necessary lymphokines in the development of cytolytic T cells. *J Immunol*, **143** : 1210-1214, 1989.
29. Leiper JM, Thomson D, Macdonald MK. Uptake and transport of Imposil by the glomerular mesangium in the mouse. *Lab Invest*, **37** : 526-533, 1977.
30. Latta H, Fligiel S. Mesangial fenestrations, sieving, filtration, and flow. *Lab Invest*, **52** : 591-598, 1985.
31. Yoshida K, Suzuki S, Kume K, Mutoh S, Suzuki J, Kato K, Suzuki H. Experimental IgA nephropathy induced by Coxsackie B4 virus in mice. *Am J Nephrol*, **17** : 81-88, 1997.
32. McEnery PT, McAdams AJ, West CD. Glomerular morphology, natural history and treatment of children with IgA-IgG mesangial nephropathy. In: Kincaid-Smith P, Mathew TH, Becker EL, eds. *Glomerulonephritis: natural history and treatment*. Wiley, New York, 305-320, 1972.
33. Andreoli SP, Bergstein JM. Treatment of severe IgA nephropathy in children. *Pediatr Nephrol*, **3** : 248-253, 1989.
34. Yoshikawa N, Ito H, Ninomiya M, the Japanese pediatric IgA nephropathy treatment study group. A controlled trial of combined therapy for newly diagnosed severe childhood IgA nephropathy. *J Am Soc Nephrol*, **10** : 101-109, 1999.
35. Haycock GB. The treatment of glomerulonephritis in children. *Pediatr Nephrol*, **2** : 247-255, 1988.
36. Mizuno K, Tsujino M, Takada M, Hayashi M, Atsumi K. Studies on Bredinin: I. Isolation, characterization and biological properties. *J Antibiot (Tokyo)*, **27** : 775-782, 1974.
37. Hughes SE, Gruber SA. New immunosuppressive drugs in organ transplantation. *J Clin Pharmacol*, **36**, 1081-1092, 1996.
38. Ishikawa H. Mizoribine and mycophenolate mofetil. *Current Med Chem*, **6** : 575-597, 1999.
39. Yoshioka K, Ohashi Y, Sakai T, Ito H, Yoshikawa N, Nakamura H, Tanizawa T, Wada H, Maki S. A multicenter trial of mizoribine compared with placebo in children with frequently relapsing nephrotic syndrome. *Kidney Int*, **58** : 317-324, 2000.
40. Yoshimura M, Kida H, Saito Y, Takaeda M, Sugioka G. Effects of methylprednisolone pulse therapy on progressive IgA nephropathy. *Nippon Jinzo Gakkai Shi*, **33** : 761-768, 1991.
41. Woo KT, Lee GS, Lau YK, Chiang GS, Lim CH. Effects of triple therapy in IgA nephritis A follow-up study 5 years later. *Clin Nephrol*, **36** : 60-66, 1991.
42. Welch TR, Fryer C, Shely E, Witte DP, Quinlan M. Double-blind, controlled trial of short-term prednisone therapy in immunoglobulin A glomerulonephritis. *J Pediatr*, **121** : 474-477, 1992.
43. Murakami K, Yoshioka K, Akano N, Takemura T, Okada M, Aya N, Hino S, Miyazato H, Yagi K, Maki S. Combined therapy in children and adolescents with IgA nephropathy. *Nippon Jinzo Gakkai Shi*, **36** : 38-43, 1994.
44. Goumenos D, Ahuja M, Shortland JR, Brown CB. Can immunosuppressive drugs slow the progression of IgA nephropathy? *Nephrol Dial Transplant*, **10** : 1173-1181, 1995.
45. Kobayashi Y, Hiki Y, Kokubo T, Horii A, Tateno S. Steroid therapy during the early stage of progressive IgA nephropathy: A 10-year follow-up study. *Nephron*, **72** : 237-242, 1996.
46. Kawasaki Y, Hosoya M, Suzuki J, Onishi N, Takahashi A, Isome M, Nozawa R, Suzuki H. Efficacy of multidrug therapy combined with mizoribine in children with diffuse IgA

- nephropathy in comparison with multidrug therapy without mizoribine and with methyl-prednisolone pulse therapy. *Am J Nephrol*, **24** : 576-581, 2004.
47. Kawasaki Y, Suzuki J, Sakai N, Etoh S, Murai H, Nozawa R, Suzuki H. Efficacy of prednisolone and mizoribine therapy for diffuse IgA nephropathy. *Am J Nephrol*, **24** : 147-153, 2004.
  48. Yoshikawa N, Honda M, Iijima K, Awazu M, Hattori S, Nakanishi K, Ito H ; Japanese Pediatric IgA Nephropathy Treatment Study Group. Steroid treatment for severe childhood IgA nephropathy : a randomized, controlled trial. *Clin J Am Soc Nephrol*, **1** : 11-17, 2006.
  49. Xie Y, Nishi S, Ueno M, Imai N, Sakatsume M, Narita I, Suzuki Y, Akazawa K, Shimada H, Arakawa M, Gejyo F. The efficacy of tonsillectomy on long-term renal survival in patients with IgA nephropathy. *Kidney Int*, **63** : 1861-1867, 2003.
  50. Hotta O, Miyazaki M, Furuta T, Tomioka S, Chiba S, Horigome I, Abe K, Taguma Y. Tonsillectomy and steroid pulse therapy significantly impact on clinical remission in patients with IgA nephropathy. *Am J Kidney Dis*, **38** : 736-743, 2001.
  51. Lozano L, Garcia-Hoya R, Egido J, Blasco R, Sancho J. Tonsillectomy decreases the synthesis of polymeric IgA by blood lymphocytes and clinical activity in patients with IgA nephropathy. *Proc EDTA-ERA*, **22** : 33-37, 1985.
  52. Maeda Y, Terazawa K, Kawakami S, Ogura Y, Sugiyama N. Clinical and immunological study of IgA nephropathy before and after tonsillectomy. *Acta Otolaryngol Suppl*, **508** : 29-35, 1988.
  53. Wyatt RJ, Hogg RJ. Evidence-based assessment of treatment options for children with IgA nephropathies. *Pediatr Nephrol*, **16** : 156-167, 2001.
  54. Kawasaki Y, Takano K, Suyama K, Isome M, Suzuki H, Sakuma H, Fujiki T, Suzuki H, Hosoya M. Efficacy of tonsillectomy pulse therapy versus multiple-drug therapy for IgA nephropathy. *Pediatr Nephrol*, **21**, 1701-1706, 2006.
  55. Tomino Y, Sakai H, Endoh M, Miura M, Suga T, Kaneshige H, Nomoto Y. Cross-reactivity of IgA antibodies between renal mesangial areas and nuclei of tonsillar cell in patients with IgA nephropathy. *Clin Exp Immunol*, **51** : 605-610, 1983.
  56. Suzuki S, Nakatomi Y, Sato H, Tsukada H, Arakawa M. Haemophilus parainfluenzae antigen and antibody in renal biopsy samples and serum of patients with IgA nephropathy. *Lancet*, **343** : 12-16, 1994.
  57. Suzuki S, Fujieda S, Sunaga H, Yamamoto C, Kimura H, Gejyo F. Synthesis of immunoglobulins against Haemophilus parainfluenzae by tonsillar lymphocytes from patients with IgA nephropathy. *Nephrol Dia Transplant*, **15** : 619-624, 2000.
  58. Hotta O. Tonsillectomy combined with steroid pulse therapy : a curative therapy for IgA nephropathy. *Acta Otolaryngol*, **555** : 43-48, 2004.