

KEISHIKAJUTSUBUTO (GUIZHI-SHU-FU-TANG) TREATMENT FOR REFRACTORY ACCUMULATION OF SYNOVIAL FLUID IN A PATIENT WITH PUSTULOTIC ARTHRO-OSTEITIS

KOICHIRO SATOH¹⁾, SHIZUKO TAKANO²⁾ and TOSHIO KOBAYASHI¹⁾

¹⁾*Institute of Physical Medicine and Rehabilitation, Fukushima Medical University,
Fukushima, 960-0201, Japan*

²⁾*Department of Pharmacology, Fukushima Medical University,
Fukushima, 960-1295, Japan*

(Received December 4, 2006, accepted February 5, 2007)

Abstract : We present a patient, a sixty-seven-year-old woman, who had refractory accumulation of synovial fluid in the knee joints with pustulotic arthro-osteitis for more than 10 years. Fifty ml of synovial fluid from her right knee contained 6,480 pg/ml of interleukin-8 (IL-8) and 15,000/mm³ of neutrophils. At first, she was treated with 400 mg/day of indomethacin farnesil (a prodrug that is converted to indomethacin after intestinal absorption) for 24 weeks. Although, the volume of synovial fluid in her right knee had decreased to 35 ml at the 16th week, it increased to 50 ml at the 24th week again. She was treated with Kampo medicine, Keishikajutsubuto (Guizhi-shu-fu-tang). In the present case, Keishikajutsubuto showed more therapeutic effect to pustulotic arthro-osteitis to reduce volume of synovial fluid to almost 0 ml, IL-8 concentration to 673 pg/ml and number of neutrophils to 660/mm³. Our data showed that Keishikajutsubuto might be suitable for this patient to regulate synovial fluid volume, reduce IL-8 concentration in synovial fluid, and block neutrophils migration to synovial fluid compared to indomethacin therapy.

Key words : keishikajutsubuto, synovial fluid, interleukin-8, neutrophil

INTRODUCTION

Pustulotic arthro-osteitis (PAO) is a rheumatic syndrome of unknown cause, characterized by an inflammatory osteitis of the sternocostoclavicular region and pustulotic rashes on the palm and soles¹⁾. Although accumulation of synovial fluid with arthritis is common symptom, few reports are available on accumulation of synovial fluid with PAO. For the treatment of PAO, non-steroidal anti-

佐藤弘一郎, 高野静子, 小林利男

Correspondence to : Koichiro Satoh, Haraguchi 3, Iizaka-machi, Fukushima 960-0201, Japan.

E-mail : kouichi@fmu.ac.jp

inflammatory drugs (NSAIDs) are considered the first choice. It could alleviate the pain^{2,3)}. Although radical treatment to PAO has not been established yet, sulfapyridine or methotrexate was reported to be effective²⁾. Combination therapy of two Kampo formula, Unkeito and Keishinieppiittokaryojutsubu, was reported to be effective for PAO⁴⁾. However no reports are available on successful treatment of Keishikajutsubuto for PAO.

Information about various arthritic diseases and systemic rheumatic diseases has been gained by gross, microscopic, and laboratory analyses of the synovial fluid. Although the normal knee joint contains only a few drops to a maximum of 4 ml, it is often possible to aspirate a large volume of joint fluid from patients with arthritis such as osteoarthritis or rheumatoid arthritis. Normal synovial fluid contains <200 cells/mm³. In inflammatory joint disease the synovial fluid contains more than 1,000 cells/mm³ and in noninflammatory joint diseases less than that. Generally, neutrophils dominate in inflammatory joint diseases and monocytes are the common encountered cells in non-inflammatory joint diseases⁵⁾. Some investigators showed high concentration of IL-8 which has been shown to be chemotactic for neutrophils, in inflammatory synovial fluid^{6,7)}.

Kampo is a traditional form of medicine that is used in current clinical practice all over Japan. Keishikajutsubuto is one of famous Kampo medicine which is suitable for treatment of joint or nerve pain in patients with reduced physical strength and poor blood circulation⁸⁾. Although the clinical effect of Keishikajutsubuto is time-honored drug for treatment of joint or nerve pain, the mechanisms of its action are not clearly understood. Little is known about the pharmacological mechanisms of NSAIDs used for treating abnormal synovial fluid with inflammatory joint disease.

CASE REPORT

A 67-year-old Japanese woman had swelling of both knee joints caused by accumulation of synovial fluid with PAO for more than 10 years. She had no other serious illness. Her mother and sister had rheumatoid arthritis. Physical findings were pustuloses of the palms and soles, and a tender mass at the anterior thoracic wall. Tenderness was observed in the both iliosacral joints. In laboratory data of 1995, blood cell count, urinalysis and renal and liver function tests were normal, and rheumatoid factor, C-reactive protein, antistreptolysin-O titers and HLA-B27 were negative. Erythrocyte sedimentation rate was 42 mm/h. Plain radiographs showed hyperostosis of both sternocostoclavicular joints, and a narrow and irregular joint space in both knee joints.

From 1995 to 1998, she had taken NSAIDs and injected corticosteroids in her knee joints. The treatments resulted in a favorable response but also induced allergic responses such as nausea and hot flash. She underwent synovectomy for her left knee joint in 2000. Her complaints were resolved temporarily.

In the late autumn of 2002, however, she visited our hospital due to recurrence of accumulation of synovial fluid. We were able to isolate 20 ml of synovial fluid from her left knee and 55 ml of synovial fluid from her right knee. The synovial fluid from her right knee contained 6,480 pg/ml of IL-8 and also 15,000/mm³ of neutrophils (Fig. 1A, B). Treatment with 400 mg/day of indomethacin farnesil (a prodrug that is converted to indomethacin) was started. After 16 weeks, the volume of synovial fluid in her right knee had decreased to 35 ml. The fluid still contained 5,160 pg/ml of IL-8 and 9,730/mm³ of neutrophils. Although this therapy was continued for 8 more weeks, synovial fluid increased to 50 ml again (Fig. 1C).

In the early summer of 2003, the drug therapy was switched to 7.5 g/day of Keishikajutsubuto from indomethacin farnesil. After 8 weeks, level of IL-8, number of neutrophils and volume of synovial joint fluid were reduced to 673 pg/ml, 660/mm³ and 19 ml, respectively. An additional 2 weeks of the therapy resulted in reduction of synovial fluid of both knee joints to almost 0 ml (Fig. 1C).

In the mid summer of 2003, however, the patient requested termination of Keishikajutsubuto treatment because of symptoms that included flush, dizziness and palpitation, and treatment with sodium diclofenac was started. After 8 months, IL-8, neutrophils and volume of synovial fluid had returned to the high levels seen in indomethacin therapy in the late autumn of 2003 (Fig. 1A-C).

DISCUSSION

The present case is the first report showed that Keishikajutsubuto is an effective drug for treating accumulation of synovial fluid with inflammatory joint disease, as evidenced by reduction in IL-8 level and number of neutrophils in synovial fluid, compared to the effects of NSAIDs such as indomethacin farnesil and sodium diclofenac.

Accumulation of synovial fluid is caused by irreversible anatomical destruction of the normal tissue architecture, with consequent articular dysfunction in consequence of inflammatory arthritis⁴⁾. How do neutrophils gain access to joints? The endothelium in synovial tissues binds neutrophils through adhesion molecules such as endothelial leukocyte adhesion molecule-1⁹⁾. The neutrophils migrate from the synovial venules, through the synovial tissue, and into the synovial fluid¹⁰⁾ by chemoattractants such as IL-8 that are produced by chondrocytes¹¹⁾, synovial macrophages and synovial fibroblasts¹²⁾. The activated neutrophils release a large amount of antioxidant¹³⁾ and antiprotease¹⁴⁾, which attack the shield of synovial tissue. In consequence of inflammatory arthritis, accumulation of synovial fluid is caused by irreversible joint destruction of the normal tissue architecture, which leads to articular dysfunction¹⁵⁾. IL-8 has been shown to accumulate in synovial fluid of patients with inflamed arthritis such as rheumatoid arthritis¹⁶⁾.

Therefore, IL-8 levels within the joint suggest ongoing inflammatory reaction. In present case, IL-8 production was unaffected by indomethacin farnesil and sodium

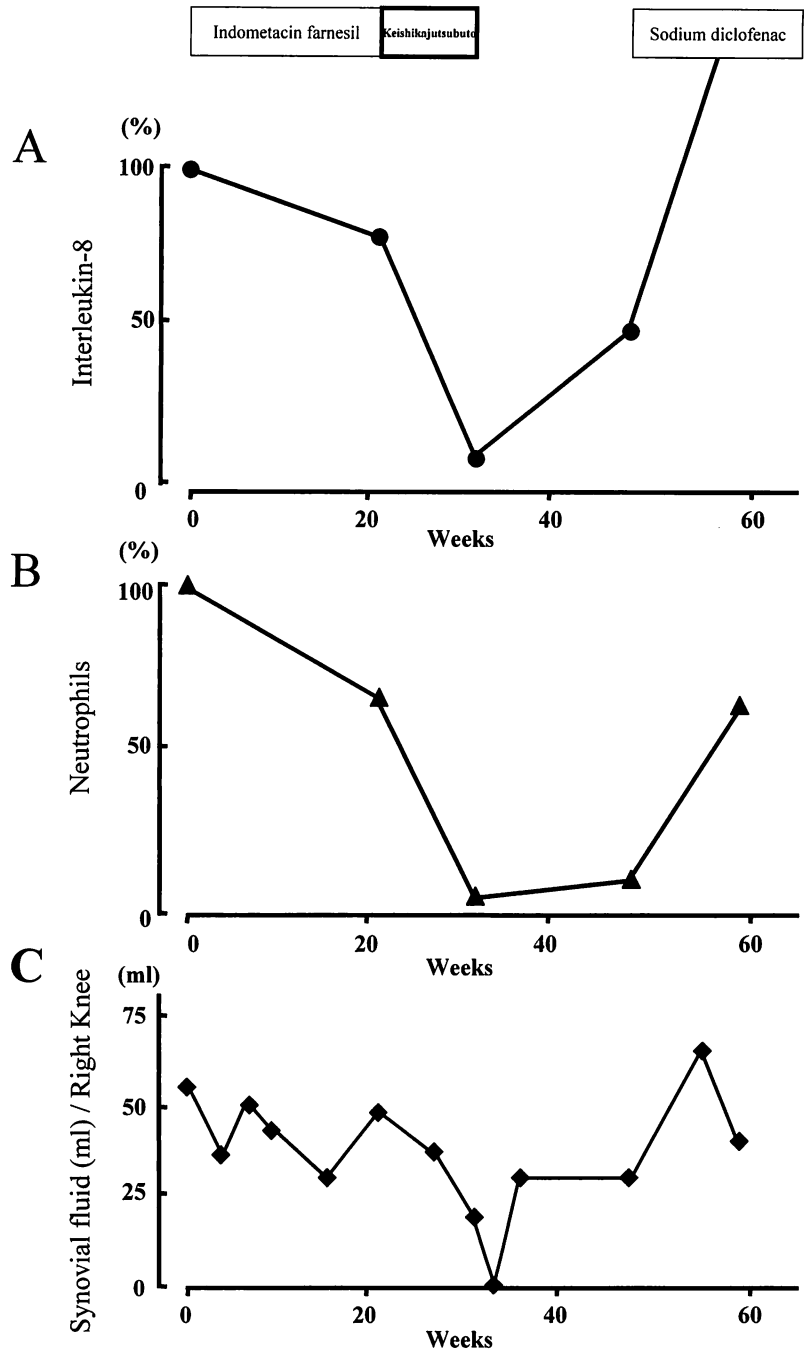


Fig. 1. Changes in IL-8 (A), neutrophils (B) and volume of synvial fluid (C) during treatments with indometacin farnesil, Keishikajustubuto and diclofenac sodium. 0 week indicates the first day when the patient visited us before drug therapy. Changes in IL-8 and neutrophils are expressed as percents: 100% indicates 6,480 pg/ml of IL-8 and 15,000/mm³ of neutrophils.

diclofenac. However, Keishikajutsubuto decreased IL-8 levels. Accordingly, this drug controls neutrophils migration, and accumulation of synovial fluid. Present case showed Keishikajutsubuto might be effective for treatment of arthritis through inhibition of IL-8 production. Despite the good therapeutic effect of Keishikajutsubuto, the patient requested unfortunately termination of the treatment because of flush, dizziness and palpitation.

Keishikajutsubuto consists of 7 herbs (Cinnamomi Cortex, Atractylodis Lanceae Rhizoma, Zingiberis Rhizoma, Aconite Tuber, Paeniae Radix, Zizyphi Fructus and Glycyrrhizae Radix). Keishikajutsubuto is appropriate for the treatment of arthralgia, paralysis of the face as well as lower body, and rheumatoid arthritis. However nobody knows the detailed mechanisms of Keishikajutsubuto for arthritis.

As concerns the anti-inflammatory effect of Keishikajutsubuto, it has been reported that Atractylodis Lanceae Rhizoma, Aconite Tuber and Glycyrrhizae Radix have anti-inflammatory effects at the early stage such as increased vascular permeability or leukocyte migration. On the other hand, at the late stage of inflammation Glycyrrhizae Radix has been reported effective¹⁷⁾. Our data showed that Keishikajutsubuto inhibit neutrophils migration related with decreasing IL-8 concentration in synovial fluid. Anti-inflammatory effects of Keishikajutsubuto is supposed by this evidence for the first time.

The 4 former herbs (Cinnamomi Cortex, Atractylodis Lanceae Rhizoma, Zingiberis Rhizoma, Aconite Tuber) work to warm human bodies and recover the physical strength of patients. Of the 4 herbs, the most is Aconite Tuber, and that is used against hypofunctional state and cold state. Aconite Tuber drug group treatment is applicable in patients with reduced physical strength, coldness or pain of limbs and body, decreased urine volume, and edematous conditions. The patient of the present case was prescribed by Keishikajutsubuto for 10 weeks from early summer. At the mid summer, the patient complained of flush, dizziness and palpitation. These unexpected symptoms could be supposed the synergic results between development of warming and activating effects on physical body by the herb, and high temperature of mid summer.

Present case showed that Keishikajutsubuto remarkably improved the accumulation of synovial fluid. The positive response may be due to inhibit IL-8 release in synovial fluid and to inhibit neutrophils migration to synovial fluid. A limitation of a case report can not deny that medicine worked for the disease accidentally. Further studies with large numbers of patients are needed to validate our results.

REFERENCES

1. Sonozaki H, Mitsui H, Miyana Y, Okitsu K, Igarashi M, Hayashi Y, Matsuura M, Azuma A, Okai K, Kawashima M. Clinical features of 53 cases with pustulotic arthro-osteitis. *Ann Rheum Dis*, **40**: 547-553, 1981.
2. Jang KA, Sung KJ, Moon KC, Koh JK, Choi JH. Four cases of pustulotic arthro-

- osteitis. *J Dermatol*, **25**: 201-204, 1998.
3. Vaccaro M, Borgia F, Guarneri F, Blandiono A, Cannavò SP, Guarneri B. Successful treatment of pustulotic arthro-osteitis (Sonozaki Syndrome) with systemic cyclosporin. *Clin Exp Dermatol*, **26**: 45-47, 2001.
4. Mantani N, Kogure T, Chino A, Shimada Y, Terasawa K. A case of pustulotic arthro-osteitis successfully treated with Kampo medicines. *J Trad Med*, **19**: 76-80, 2002.
5. Freemont AJ. Synovial fluid analysis. *In*: Klippel J, Dieppe PA, eds. *Rheumatology*. 2nd ed. Mosby, London, Philadelphia, St Louis, Sydney and Tokyo, 11.1-11.4, 1997.
6. Kasama Y, Iwabuchi H, Hanaoka R, Takeuchi HT, Miwa Y, Jing L, Mori Y, Kobayashi K, Negishi M, Ide H, Adachi M. Synovial fluid neutrophil expression of interleukin-8 in rheumatoid arthritis. *Jpn J Rheumatol*, **9**: 175-187, 1999.
7. Bertazzolo N, Punzi L, Stefani MP, Cesaro G, Pianon M, Finco B, Todesco S. Interrelationships between interleukin (IL)-1, IL-6 and IL-8 in synovial fluid of various arthropathies. *Agents Actions*, **411**: 90-92, 1994.
8. Aconiti Tuber drug group. *In*: Introduction to Kampo, Japanese Traditional Medicine. The Japan Society for Oriental Medicine ed. Elsevier Japan K.K, Tokyo, 82-83, 2005.
9. Koch AE, Burrows JC, Haines GK, Carlos TM, Harlan JM, Leibovich SJ. Immunolocalization of leukocyte and endothelial adhesion molecules in human rheumatoid and osteoarthritic synovial tissues. *Lab Invest*, **64**: 313-320, 1991.
10. Harris ED Jr. Rheumatoid arthritis: pathophysiology and implications for therapy. *N Engl J Med*, **322**: 1277-1289, 1990.
11. Lotz M, Terkeltaub R, Villiger PM. Cartilage and joint inflammation regulation of IL-8 expression by human articular chondrocytes. *J Immunol*, **148**: 466-473, 1992.
12. Koch AE, Kunkel SL, Burrows JC, Evanoff HL, Haines GK, Pope RM, Strieter RM. Synovial tissue macrophage as a source of the chemotactic cytokine IL-8. *J Immunol*, **147**: 2187-2195, 1991.
13. Ossanna PJ, Test ST, Matheson NR, Regiani S, Weiss SJ. Oxidative regulation of neutrophil elastase- α 1-protease inhibitor interaction. *J Clin Invest*, **77**: 1939-1951, 1993.
14. Abbink JJ, Kamp AM, Nuijins JH, Regiani S, Weiss SJ. Proteolytic inactivation of α 1-antitrypsin and chymotrypsin by neutrophils in arthritic joints. *Arthritis Rheum*, **36**: 168-180, 1993.
15. Elford PR, Cooper PH. Induction of neutrophil-mediated cartilage degradation by interleukin-8. *Arthritis Rheum*, **35**: 325-332, 1991.
16. Verburgh CA, Hart MHL, Aarden LA, Swaak AJG. Interleukin-8 (IL-8) in synovial fluid of rheumatoid and nonrheumatoid joint effusions. *Clin Rheumatol*, **12**: 494-499, 1993.
17. Shiroishi H, Terasawa K, Torizuka K, Yamamoto Y, Nakagawa H. Studies on anti-inflammatory effects of Japanese Oriental (Kampo) medicines: Inhibitory effects on experimental acute and chronic inflammatory models in rats. *J Trad Med*, **6**: 89-99, 1989.