

[Case Report]

**A CASE OF STEROID-REFRACTORY ULCERATIVE COLITIS  
COMPLICATED WITH CYTOMEGALOVIRUS PNEUMONIA**

SHUZO SATO<sup>1)</sup>, HIROKO KOBAYASHI<sup>1)</sup>, RIE SAITO<sup>1)</sup>,  
TOMOMI SASAJIMA<sup>1)</sup>, HIROSHI ORIKASA<sup>1)</sup>, HIROSHI WATANABE<sup>1)</sup>,  
HIROMASA OHIRA<sup>1)</sup>, KAZUHIRO TASAKI<sup>2)</sup> and MASAFUMI ABE<sup>2)</sup>

<sup>1)</sup>*Department of Internal Medicine II, Fukushima Medical University School of Medicine,  
Fukushima, 960-1295, Japan*

<sup>2)</sup>*Department of Pathology I, Fukushima Medical University School of Medicine,  
Fukushima, 960-1295, Japan*

(Received September 5, 2006, accepted January 26, 2007)

**Abstract :** We present a case of late-onset ulcerative colitis (UC) complicated with cytomegalovirus (CMV) pneumonia revealed by autopsy. A 77-year-old woman had a diagnosis of UC, and received high-dose steroids and leukocytapheresis. Then she received ganciclovir because CMV-pp65 antigenemia test revealed positive which suggested systemic or colonic CMV infection. But ganciclovir was discontinued because of thrombocytopenia and liver dysfunction. After that she had interstitial pneumonia and died of a respiratory failure. Autopsy revealed CMV colitis based on UC, and CMV pneumonia with diffuse alveolar damage. Evaluation of CMV infection in patients with steroid-refractory UC should be considered before proceeding with immunosuppressive therapy or surgery, especially in elderly patients.

**Key words :** ulcerative colitis, cytomegalovirus pneumonia, CMV infection

INTRODUCTION

Cytomegalovirus (CMV) is a species-specific  $\beta$ -herpesvirus that is present in the majority of the population (60%-90%)<sup>1)</sup>. Active CMV infection often develops in immunocompromised hosts, such as human immunodeficiency virus infection, receiving chemotherapy for malignant tumors, and immunosuppressive agents for organ transplantation or autoimmune diseases.

---

佐藤秀三, 小林浩子, 斉藤理恵, 折笠博史, 佐々島朋美, 渡辺浩志, 大平弘正, 田崎和洋, 阿部正文

Correspondence to: Shuzo Sato, Department of Internal Medicine II, Fukushima Medical University School of Medicine, Fukushima City 960-1295, Japan.

E-mail: shuzo@fmu.ac.jp

Recently, several reports suggest that steroid-refractory ulcerative colitis (UC) correlates with CMV infection<sup>2-4</sup>. CMV infection can aggravate UC on a basis of immunosuppressive state, and cause fatal organ damage. However, there has been no previous report describing a case with CMV pneumonia developed in a patient with UC. In this report, we present a case of late-onset UC complicated with CMV pneumonia, revealed by autopsy.

#### CASE REPORT

A 77-year-old woman had experienced lower abdominal pain and diarrhea since January, 2003. In February, she had a diagnosis of UC and received prednisolone for three months, but the colitis was refractory to the therapy. She was referred to our hospital in May. On admission, she suffered from lower abdominal pain. She had bloody stool or diarrhea 5 times a day. On physical examination, her body temperature was 37.0°C, her heart beat was 80/min, and blood pressure was 110/80 mmHg. Her bowel sounds were weak. She had tenderness in the left lower quadrant of abdomen. Hematological examination showed anemia, red blood cell count of  $311 \times 10^4/\mu\text{l}$  and hemoglobin of 9.0 g/dl, and normal white blood cell count of  $5,100/\mu\text{l}$ . The level of C-reactive protein was 1.3 mg/dl, and erythrocyte sedimentation rate was 52 mm in 1 hour. The levels of total protein and serum albumin were 5.6 g/dl, 2.4 g/dl, respectively. Disease activity of UC was moderate according to the Truelove and Witt's criteria, which classified by the extent of bloody stool, fever, pulsation, anemia, repeat of defecation, and a high erythrocyte sedimentation rate<sup>5</sup>. Sigmoidoscopy showed abrupt mucosa, pseudopolypoidosis, and consecutive multiple deep ulcers from the rectum to sigmoid colon (Fig. 1). Biopsied specimen

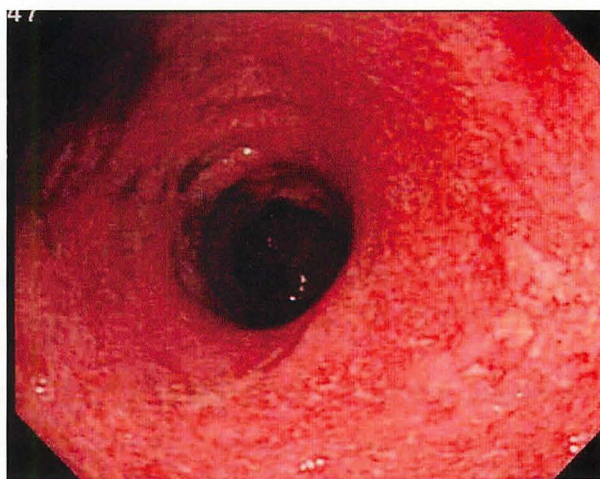

Fig. 1. Sigmoidoscopy showed consecutive abrupt mucosa, spontaneous bleeding and multiple deep ulcers.

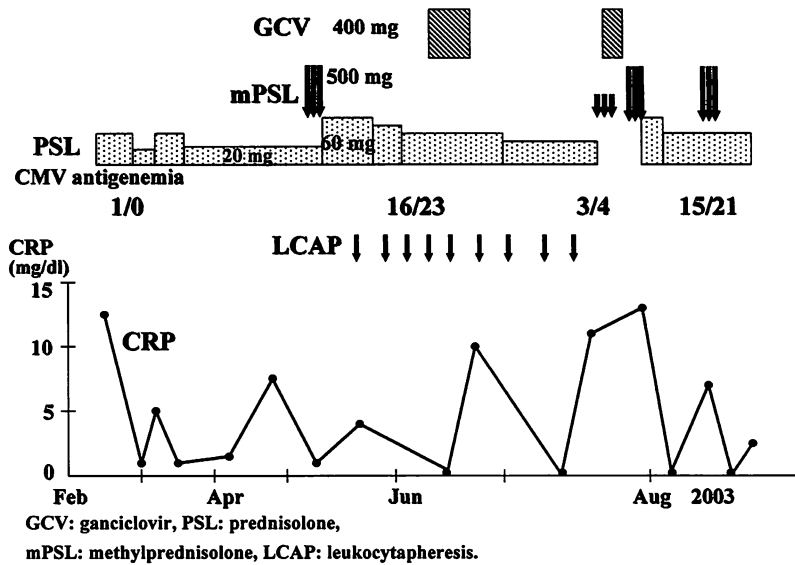


Fig. 2. Clinical course of the patient.

showed typical histological findings of UC. She received methylprednisolone in a dose of 500 mg for 3 days, followed by high doses of prednisolone (60 mg/day) (Fig. 2). Also, she was treated with leukocytapheresis once a week for 10 times. Her symptoms improved slightly, but did not disappear. In June, CMV-pp65 antigenemia test revealed positive, which suggested systemic or colonic CMV infection. She received ganciclovir (GCV) in a dose of 5 mg/kg for 11 days, but GCV was discontinued because of thrombocytopenia and liver dysfunction. Then, she was referred to surgery because the colitis was refractory to the therapy. In July, she suddenly experienced high fever and dyspnea. Chest X-ray and CT showed ground-glass appearance of both lungs. In spite of intensive care, she suffered from acute respiratory distress syndrome and bilateral pneumothorax. She died of a respiratory failure and severe anemia. Autopsy findings showed consecutive deep ulcers from rectum to transverse colon compatible with UC, and severe CMV infection in capillary endothelium of proper muscle layer (Fig. 3A). Both lungs showed diffuse alveolar damage (DAD) with organized hyaline membrane in alveolar walls, including numerous CMV-infected cells (Fig. 3B). Cause of death was respiratory failure due to organized DAD. Massive bleeding from colon ulcers might also contribute to the deterioration of general condition.

#### DISCUSSION

CMV is a common infection, and it appears to be an important contributing factor to steroid-refractory disease in patients with UC<sup>2-4)</sup>. As in this case, CMV infection may be systemic, and it is a potentially fatal complication in patients with

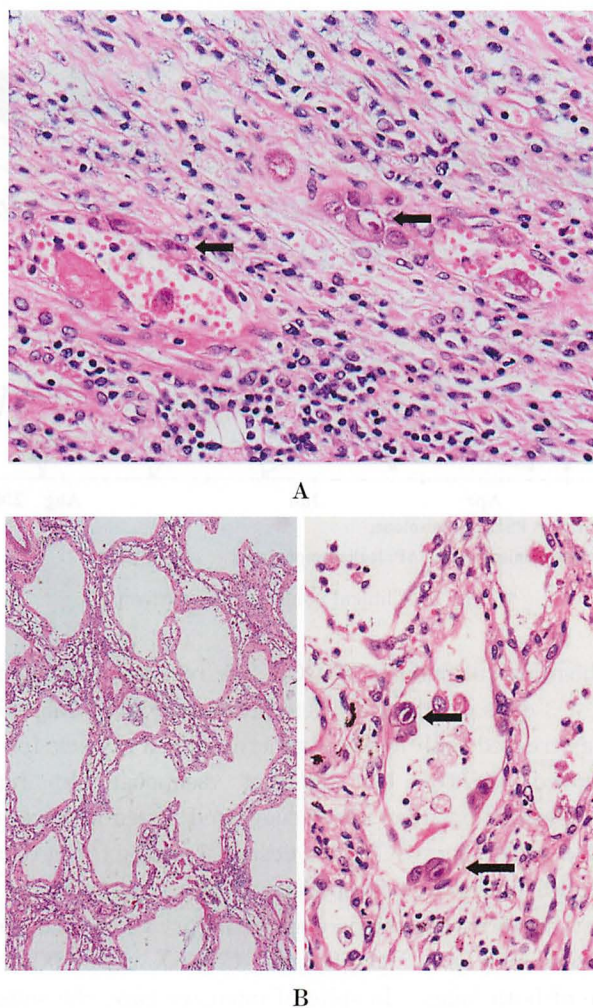


Fig. 3. Histological findings of the transverse colon and the lung. A. Numerous CMV infected cells were observed especially in capillary endothelium, showing CMV colitis based on ulcerative colitis. Arrows indicate the inclusion bodies ( $\times 400$ ). B. Diffuse alveolar damage was shown with organized hyaline membrane in alveolar walls (left,  $\times 150$ ). Numerous CMV-infected cells on the alveolar walls are indicated by arrows (right,  $\times 400$ ).

inflammatory bowel disease, especially in those treated with multiple immunomodulators. Outcome of CMV infections in patients with inflammatory bowel disease (IBD) has been reported mortality rate of 30%<sup>4)</sup>. Prompt diagnosis of CMV colitis by CMV pp65 test, anti-CMV IgM, PCR, and histological analysis allows prompt treatment with GCV, which provides clinical response in steroid-refractory UC<sup>3,4,6)</sup>. However, establishing a diagnosis of active CMV infection is challenging in those patients because CMV colitis is often clinically indistinguishable from an episode of acute colitis. In fact, GCV was administered in this patient before

establishing a diagnosis of CMV colitis or pneumonia because positive CMV pp65 antigenemia test suggested a systemic CMV infection. However, the antiviral therapy was insufficient because of the GCV side effects. To the best of our knowledge, there has been no previous report describing a case with CMV pneumonia developed in a patient with UC. Two cases with CMV pneumonia developed in patients with Crohn's disease have been reported<sup>3,7)</sup>. Their ages were 19 and 51-years old. They were treated with steroid, 6-mercaptopurine, ciclosporin, or 5-aminosalicylic acid before the onset of CMV pneumonia. Both patients received GCV for the treatment of CMV pneumonia; one of them was discharged and the other died.

Although risk factors of CMV infection have not fully been investigated in UC patients, Kishore *et al.* suggested female gender, pancolitis, or histological activity were the independent risk factors<sup>4)</sup>. CMV colitis is well described in acquired immunodeficiency syndrome patients, in organ transplant patients, in patients receiving immunosuppressants or steroids, in patients with cancer or receiving chemotherapy, and in the elderly, particularly those who suffer from chronic illness<sup>8)</sup>. Onset of UC after the age of 65 is not common, for example, the number of the patients who had a diagnosis of UC at the age of over 60 were 12 of 168 (7.14%) in Japan<sup>9)</sup>. Late-onset UC was shown to be more aggressive, resistant to the conventional therapy, and associated with high rate of complications. Almogy *et al.* proposed that urgent surgery and hypoalbuminemia were predictors of adverse outcome in the elderly population suffering from late-onset UC and requiring an operation<sup>10)</sup>. It is difficult to manage elderly patients with severe colitis unresponsive to conventional therapy. Absolute indications for surgery are exsanguinating hemorrhage, perforation, and documented or strongly suspected carcinoma<sup>11)</sup>. In this case, surgical treatment was planned without absolute indications for surgery, because her colitis was unresponsive to the conventional therapy. But it was unable because of the onset of CMV pneumonia. Majority of patients with UC does not require surgery, however, this case may propose that elderly patients should be referred to surgery earlier than young patients if the colitis was refractory to the conventional therapy, and that we should be aware of the risks and benefits of operations within different clinical settings.

In conclusion, we described a rare case of UC complicated with CMV pneumonia revealed by autopsy. Further studies are needed in elderly patients with steroid-refractory UC to establish new tools for diagnosing CMV colitis at early stage, to evaluate high risk group for CMV infection, and to assess an indication of prophylactic therapy with GCV in such group.

#### REFERENCES

1. Sugisaki K, Maekawa S, Mori K, Ichii O, Kanda K, Tai M, Suzuki T, Ochiai H, Ejiri Y, Takahashi M, Hakozaiki H. Self-limited Colitis during the Course of Rubella and

- Cytomegalovirus Infection in an Immunocompetent Adult. *Intern med*, **43**: 404-409, 2004.
2. Kambham N, Vij R, Cartwright CA, Longacre T. Cytomegalovirus Infection in Steroid-refractory Ulcerative Colitis. *Am J Surg Pathol*, **28**: 365-373, 2004.
  3. Papadakis KA, Tung JK, Binder SW, Kam LY, Abreu MT, Targan SR, Vasiliauskas EA. Outcome of Cytomegalovirus Infections in Patients With Inflammatory Bowel Disease. *Am J Gastroenterol*, **96**: 2137-2142, 2001.
  4. Kishore J, Ghoshal U, Ghoshal UC, Krishnani N, Kumar S, Singh M, Ayyagari A. Infection with cytomegalovirus in patients with inflammatory bowel disease: prevalence, clinical significance and outcome. *J Med Microbiol*, **53**: 1155-1160, 2004.
  5. Truelove SC, Witts LJ. Cortisone in ulcerative colitis: Final report on a therapeutic trial. *Br Med J*, **2**: 1041-1048, 1955.
  6. Hamlin PJ, Shah MN, Scott N, Wyatt JI, Howdle PD. Systemic cytomegalovirus infection complicating ulcerative colitis: a case report and review of the literature. *Postgrad Med J*, **80**: 233-235, 2004.
  7. Hookey LC, Depew W, Boag A, Vanner S. 6-Mercaptopurine and inflammatory bowel disease: Hidden ground for the cytomegalovirus. *Can J Gastroenterol*, **17**: 319-322, 2003.
  8. Goodname RW. Gastrointestinal Cytomegalovirus Disease. *Ann Intern Med*, **119**: 924-935, 1993.
  9. Ishibashi N, Hirota N, Ikeda M, Hirohata T. Ulcerative colitis and colorectal cancer: a follow-up study in Fukuoka, Japan. *Int J Epidemiol*, **28**: 609-613, 1999.
  10. Almogy G, Bordian CA, Greenstein AJ. Surgery for late-Onset ulcerative colitis: predictors of short-term outcome. *Scand J Gastroenterol*, **9**: 1025-1028, 2002.
  11. Kornbluth A, Sachar DB. Ulcerative colitis practice guidelines in adults (update): American College of Gastroenterology, Practice Parameters Committee. *Am J Gastroenterol*, **99**: 1371-1385, 2004.