

[Case Report]

**CASE OF AN ELDERLY MAN WITH ASSOCIATED HENOC-SCHÖNLEIN
PURPURA DURING TREATMENT OF ACUTE PANCREATITIS**

SHUZO SATO, ATSUSHI IRISAWA, KIORI SHIO, TADAYUKI TAKAGI
and HIROMASA OHIRA

*Department of Internal Medicine II, Fukushima Medical University School of Medicine,
Fukushima, 960-1295, Japan*

(Received July 5, 2006, accepted September 21, 2006)

Abstract: A 70-year-old man with acute pancreatitis (acute exacerbation of chronic pancreatitis) was admitted to our department. Despite temporary improvement, the pancreatitis worsened on the 21st hospital day, forming a pancreatic pseudocyst, with infection in the cyst. After treatment with various antibiotics, a blood test on the 71st hospital day indicated improved inflammatory response despite continuing abdominal cramps. From the 75th hospital day, the patient developed purpura and arthralgia of the lower limbs, with melena and hematuria. Henoch-Schönlein purpura was diagnosed definitively by skin biopsy. Such a complication of acute pancreatitis with Henoch-Schönlein purpura is rare. This case also suggests that microvasculitis around the pancreas resulting from Henoch-Schönlein purpura might have prolonged the pancreatitis.

Key words: acute pancreatitis, Henoch-Schönlein purpura

INTRODUCTION

Henoch-Schönlein purpura (HSP) is non-thrombocytopenic purpura with skin, abdominal, and arthritic manifestation, developing systemic inflammation of small vessels. Although its cause has not been clarified, it is inferred to have some allergic mechanism¹⁻⁴⁾. It is often manifested in children, but rarely in adults, whose rate of incidence is reportedly 0.65/100,000⁵⁾.

Although acute pancreatitis is a benign disease, it has clinical symptoms that vary from minor cases to severe cases, the latter leading to death by multiple organ failure⁶⁾. It is sometimes complicated with pancreatic necrosis or by pancreatic

佐藤秀三, 入澤篤志, 塩 季織, 高木忠之, 大平弘正

Correspondence to: Atsushi Irisawa, Department of Internal Medicine II, Fukushima Medical University School of Medicine, Fukushima City 960-1295, Japan.

E-mail: irisawa@fmu.ac.jp

abscess⁷⁾, both of which are caused mainly by gallstones, long-term alcohol abuse and partial injuries, tumors, and agents. Chronic pancreatitis is often attributed to long-term alcohol abuse (70%). Other factors might include gallstones, tumors, and genetic factors, etc. Although pathologies of chronic pancreatitis are generally distinct from those of acute pancreatitis, cases of chronic pancreatitis are sometimes acutely exacerbated, thereby also manifesting symptoms of acute pancreatitis.

Association of HSP with acute pancreatitis is rare: only a dozen cases have been reported⁸⁻¹⁰⁾. Additionally, in most of those cases, acute pancreatitis coincided with HSP. Consequently, the former is presumably the result of microvasculitis around the pancreas caused by the latter. Because the presented case, which describes development of HSP during the process of treatment following development of acute pancreatitis, is very rare and etiologically interesting, we report it herein.

CASE REPORT

Case: A 70-year-old man consulted our department because of appetite loss, abdominal pain, and nausea which had begun two days prior. He was diagnosed as having alcoholic chronic pancreatitis around 1977 (alcohol intake: 90 g/day). He had no history of any drug allergy. At the first consultation, his body temperature was 37.2°C; blood pressure was 160/100 mmHg. Blood tests revealed the following: white blood cells (WBC) were 15,300/ μ l (normal value: 3,000-9,800/ μ l); AST, 63 IU/l (10-30 IU/l); ALT, 26 IU/l (6-25 IU/l); TB, 2.0 g/dl (0.3-1.2 g/dl); blood glucose level, 157 mg/dl (70-110 mg/dl); AMY, 363 IU/l (70-240 IU/l); and CRP, 0.6 mg/dl (under 0.3 mg/dl). An abdominal CT scan showed swollen pancreas with mild fluid collection. The patient was diagnosed as having acute pancreatitis (acute exacerbation of chronic pancreatitis).

The clinical course is shown in Fig. 1. After admission, administration of sulbactam/cefoperazone (2 g/day) and gabexate mesilate (600 mg/day) was started. The acute pancreatitis responded to that treatment, which engendered smooth improvement of symptoms. Blood tests and diagnostic imaging also showed decreased inflammatory response and an improved image of pancreatitis. Consequently, the patient began to have meals (fat-restricted diet) on the 19th hospital day. On the 21st hospital day, however, he again complained of abdominal pain, accompanied with fever. Blood tests showed that, although AMY was 90 IU/l, lipase was 132 IU/l (normal value: 13-49 IU/l); furthermore, trypsin, 770 ng/ml (100-500 ng/ml), pancreatic enzyme and inflammatory response rose (CRP, 6.2 mg/dl and WBC, 22,000/ μ l). Abdominal CT images also depicted pancreatic swelling, which had improved temporarily, and fluid collection around the pancreas (Fig. 2). Formation of a pseudocyst was also apparent on the pancreas head. The CT showed a miniscule calcified calculus within the gallbladder, but no marked evidence of obstruction by the calculus or hepatic dysfunction was indicated. Therefore,

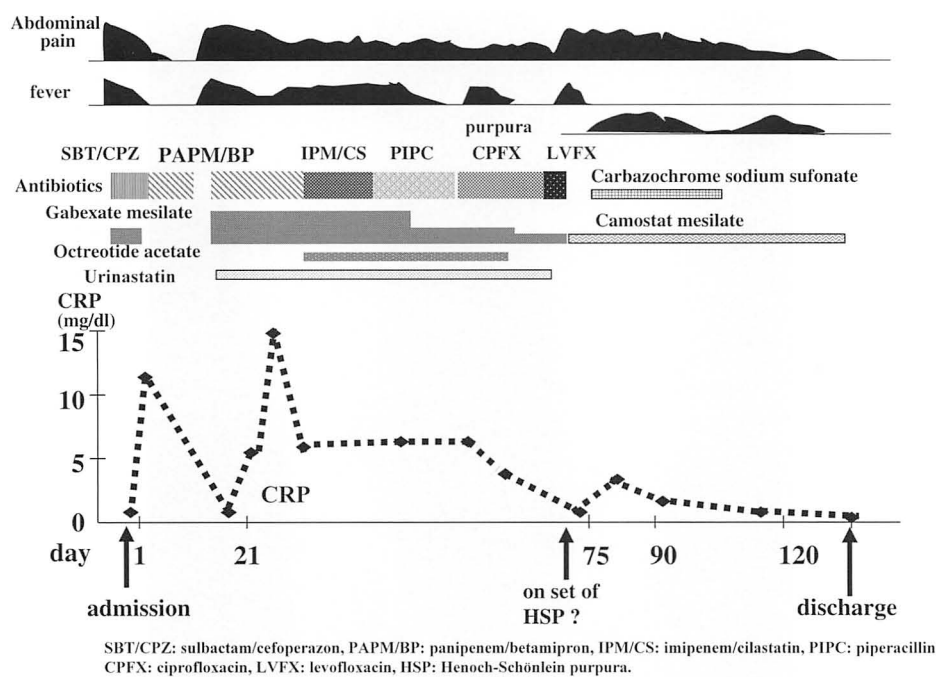


Fig. 1. Clinical course.

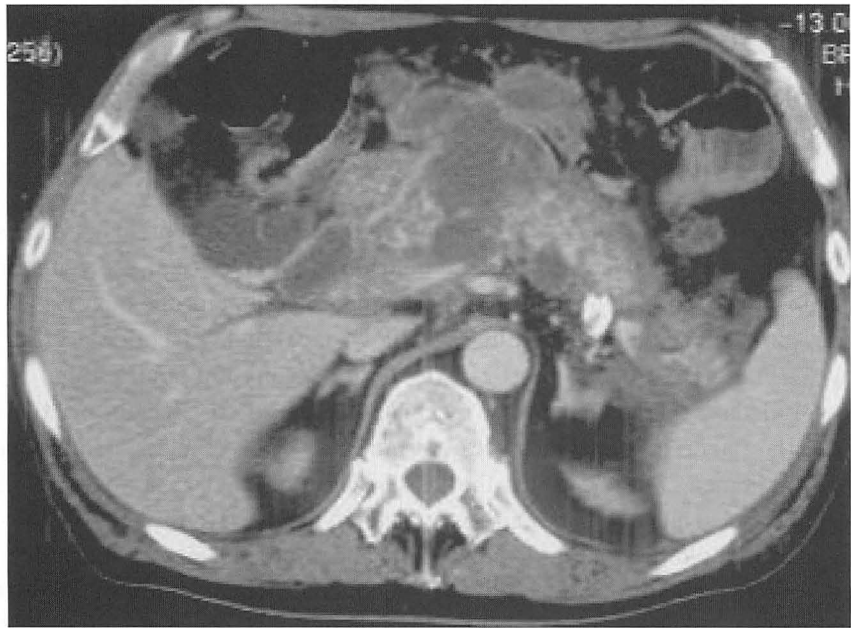

Fig. 2. Abdominal enhanced CT on day 21 showed swollen pancreas, fluid collection, and a pseudocyst. It was inferred to be severe inflammation because pancreatitis involved organs around the pancreas.

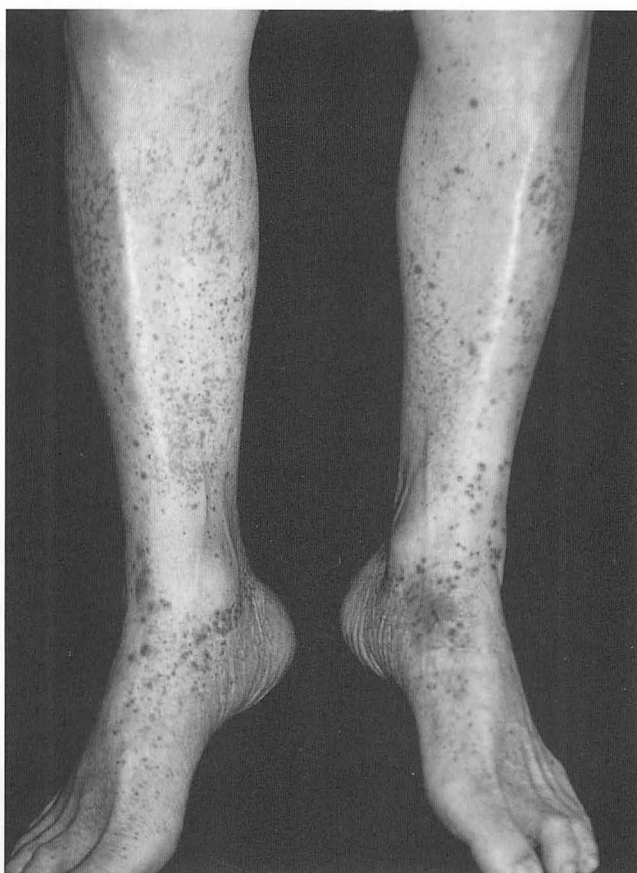

Fig. 3. Purpura on the lower limbs appearing on the 75th hospital day. The purpura was manifested sporadically on each of the lower limbs.

biliary pancreatitis was denied. We diagnosed the relapse of acute pancreatitis and infection of the pseudocyst. We administered many kinds of antibiotics (imipenem/cilastatin, panipenem/betamipron, piperacillin, ciprofloxacin), gabexate mesilate (2,000 mg/day), urinastatin (30×10^4 U/day), and octreotide acetate (150 μ g/day). These treatments improved the severe symptoms and status. By the 71st hospital day, the inflammatory response decreased to CRP 0.7 mg/dl, WBC 6,000/ μ l; the pancreatic enzymes were normalized. Nevertheless, colicky pain in the upper abdomen continued. On the 75th hospital day, purpura appeared on the lower limbs, subsequently spreading to the trunk and extremities (Fig. 3). The patient also complained of ankle joint pain and mild melena. Laboratory data showed a WBC count of 5,200/ μ l, red blood cell (RBC) count of 290×10^4 / μ l (normal value: $416\text{--}558 \times 10^4$ / μ l), hemoglobin of 10.1 g/dl (normal value: 13.2–16.8 g/dl), and a platelet count of 16.7×10^4 / μ l (normal value: $14.7\text{--}34.1 \times 10^4$ / μ l). The eosinophil count was not elevated (2% of WBC). In coagulation, the partial thrombin time was normal, but prolonged activated partial thromboplastin time (41.8 s,

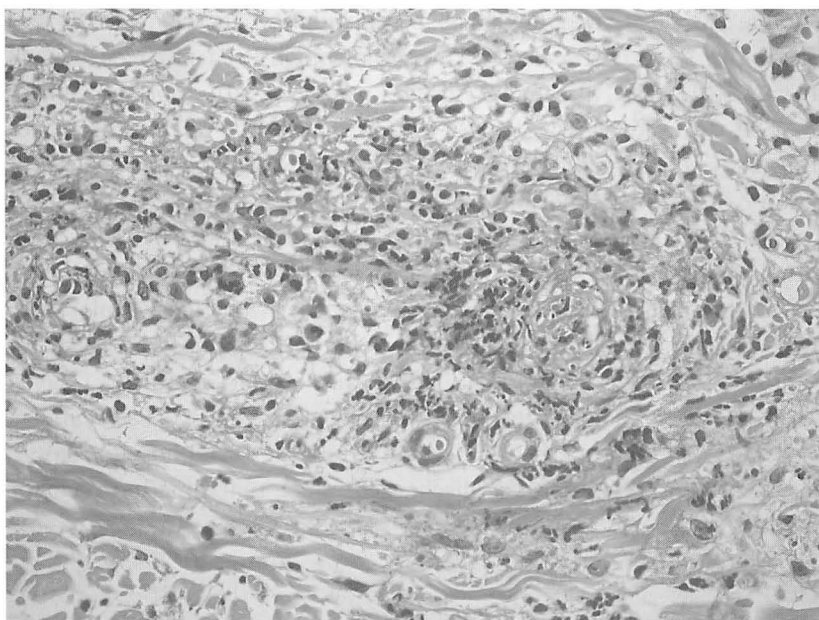

Fig. 4. Biopsied specimen of purpuric skin rash. In the dermis, prominent infiltration of neutrophils was identified around small vessels; vascular fibrinoid degeneration was also apparent. These findings suggested HSP (H&E stain, $\times 400$).

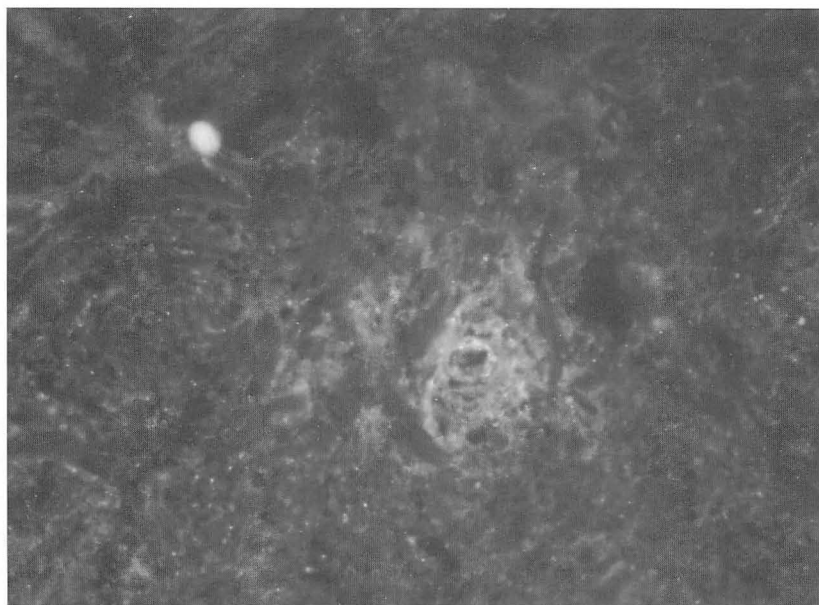

Fig. 5. IgA stain of the biopsied specimen. Immunofluorescence microscopy showed IgA deposition in a small vessel of the dermis ($\times 400$).

normal value: 31–45 s), and low level of coagulation factor XIII (41%, normal value: over 70%) were observed. The serum blood urea nitrogen was 14 mg/dl (normal value: 9–20 mg/dl), and creatinine was 0.7 mg/dl (normal value: 0.6–1.1 mg/dl). The IgA level was high: 594 mg/dl (normal value: 115–359 mg/dl). Urinalysis showed microscopic hematuria (100 > RBC/high power field). Low inflammatory response and normal pancreatic enzymes suggested a mild recurrence based on chronic pancreatitis. A skin biopsy of purpura showed WBC infiltration around the small vessels and fibrinoid necrosis, suggesting leukocytoclastic vasculitis. Immunostaining demonstrated IgA deposition on the vascular wall (data not shown). The findings above established the HSP diagnosis. By virtue of the use of antiallergic drugs, hemostatic drugs, and steroid ointments, the eruption disappeared on the 119th hospital day. The inflammatory response became negative and the coagulation factor XIII was normalized on the 122nd hospital day. On the 136th hospital day, the patient was discharged. Since that time, no recurrence has been reported.

DISCUSSION

Henoch-Schönlein purpura is a non-thrombocytopenic purpura with three cardinal signs: skin manifestation (purpura, papule, and local edema), articulation manifestation, and abdominal manifestation (abdominal pain and melena)^{1–5}. It sometimes becomes difficult to make a diagnosis when all signs do not appear simultaneously, especially when purpura appear later. The incidence rate of cases with purpura following abdominal pain is reportedly about 8% in adults⁴. Despite another report that it should take five days for purpura to appear after the appearance of digestive manifestation, the interval between appearances sometimes becomes more than one week⁹. It is presumed to develop favorably in children (4–7 years old) and rarely in older patients, with upper respiratory infection preceding the other manifestations in 50% of these cases. Systemic inflammation of small vessels is essential, which is considered to be an allergic response to some incentive. As incentives, the following factors have been described: various viruses (EBV, adenovirus, parvovirus B19, varicella, measles, and rubella), bacteria (Group A beta-hemolytic streptococci, mycoplasma, helicobacter, and *Bartonella henselae*), drugs (antibiotics such as penicillin, tetracycline, and erythromycin, NSAID, thi-azide, and propylthiouracil), food, insect bites, low temperature, and so on. Nevertheless, reports have failed to identify a cause related to HSP in two thirds of cases^{2,11}. Purpura is visible in more than 90% of the cases, repeatedly withdrawing. In 56% of adult patients, abdominal manifestations are complicated exclusively with complaints of abdominal pain as a subjective symptom. Inflammation of small vessels sometimes engenders edema of GI tract walls and bleeding. With a strong manifestation, such as that of GI tract bleeding, surgical operations are sometimes required. Although nephropathy occurs in about 30% of children, it is seen more

frequently in adult patients. Comparison of cases involving adults and children reveals that adult patients tend to develop digestive manifestations (e.g. melena), hematuria, renal damage, and skin ulcers²⁾. Biopsy of purpura site tissues shows leukocytoclastic vasculitis, with disposition of IgA, C3, and IgG, which are useful for establishing a diagnosis⁹⁾.

Complication of HSP with acute pancreatitis is rare, with only 14 cases reported⁸⁻¹⁰⁾. Although details of complicating factors remain unknown because HSP manifestation precedes the others in most cases, it is suggested that inflammation of small blood vessels surrounding the pancreas might cause acute pancreatitis. One typical case report of a child describes that HSP developed 9 days after the occurrence of acute pancreatitis⁸⁾. In that case, no manifestation factor of acute pancreatitis was identified aside from HSP: the interval separating appearances of acute pancreatitis and HSP was small, suggesting that HSP had developed before the typical symptoms of HSP appeared, allowing inflammation of small blood vessels surrounding the pancreas to thereby cause acute pancreatitis. Subsequently, skin manifestations were actualized.

In case described herein, after acute pancreatitis recurred, partly because of complication of a pseudocyst infection, the patient took a considerable length of time to heal. Although inflammatory responses and pancreatic enzyme increases were improved, abdominal cramps continued; then skin manifestations appeared as a typical symptom of HSP. Consideration of this process introduces the possibility that HSP might have manifested prior to the appearance of skin manifestations, with abdominal manifestations. Another possibility is that this HSP might have caused inflammation of small blood vessels around the pancreas; such inflammation is associated with delayed pancreatitis or continuous abdominal pain. Chronic pancreatitis existed as an underlying disease and the initiated pancreatitis was mild in this case, perhaps explaining the lack of severe inflammation and hyperamylasemia in the vicinity of HSP occurrence. Regarding the incentive of HSP manifestation in this case, various antibiotics were administered because advanced inflammatory response, including the complication of pseudocyst infection was apparent after recurrence. An allergic response to these was also likely to cause HSP¹²⁻¹⁴⁾.

In conclusion, when abdominal manifestations precede skin manifestations, it is difficult to diagnose HSP. Especially for diagnoses of acute pancreatitis, HSP might be involved in cases where transiently quiescent pancreatitis recurrence is delayed without any incentive or in which abdominal pain is prolonged even though pancreatitis itself is improved.

REFERENCES

1. Ballinger S. Henoch-Schönlein purpura. *Curr Opin Rheumatol*, **15**: 591-594, 2003.
2. Blanco R, Martinez-Taboada VM, Rodriguez-Valverde V, Garcia-Fuentes M, Gonzalez-

- Gay MA, *et al.* Henoch-Schönlein purpura in adulthood and childhood: two different expressions of the same syndrome. *Arthritis Rheum*, **40**: 859-864, 1997.
3. Kaneko K. Henoch-Schönlein purpura. (in Japanese) *Nippon Rinsho*, **63**: 346-351, 2005.
 4. Pillebout E, Thervet E, Hill G, Alberti C, Vanhille P, Nochy D. Henoch-Schönlein purpura in adults: outcome and prognostic factors. *J Am Soc Nephrol*, **13**: 1271-1278, 2002.
 5. Ameral Guirado AI, Montes Santiago J. Henoch-Schönlein purpura in adults: a study of 9 cases. *An Med Interna*, (in Spanish, English abstract) **21**: 79-80, 2004.
 6. Mitchell RMS, Byrne MF, Baillie J. Pancreatitis. *Lancet*, **361**: 1447-1455, 2003.
 7. Andren-Sandberg A, Derveniz C. Pancreatic pseudocysts in the 21st century. Part 1: classification, pathophysiology, anatomic considerations and treatment. *JOP*, **5**: 8-24, 2004.
 8. Cheung KM, Mok F, Lam P, Chan KH. Pancreatitis associated with Henoch-Schönlein purpura. *J Paediatr Child Health*, **37**: 311-313, 2001.
 9. Chen SY, Kong MS. Gastrointestinal manifestations and complications of Henoch-Schönlein purpura. *Chang Gung Med J*, **27**: 175-181, 2004.
 10. Puppala AR, Cheng JC, Steinheber FU. Pancreatitis—a rare complication of Schönlein-Henoch purpura. *Am J Gastroenterol*, **69**: 101-104, 1978.
 11. Gracia-Porrúa C, Gonzalez-gay MA, Lopez-Lazaro L. Drug associated cutaneous vasculitis in adults in northwestern Spain. *J Rheumatol*, **26**: 1942-1944, 1999.
 12. Gamboa F, Rivera JM, Gomez Mateos JM, Gomez-Gras E. Ciprofloxacin-induced Henoch-Schönlein purpura. *Ann Pharmacother*, **29**: 84, 1995.
 13. Pace JL, Gatt P. Fatal vasculitis associated with ofloxacin. *BMJ*, **299**: 658, 1989.
 14. Di Perna CD, Vanni S, Allegri L, Manganelli P, Buzio C. Severe glomerulonephritis and isolated ileitis in adult Henoch-Schönlein purpura. *Clin Nephrol*, **56**: 487-489, 2001.