

## A CASE OF ANNULAR PANCREAS IN A MALE ADULT

MASATSUGU MIYAZAWA, ATUSHI MUTO, MASAYUKI SATO,  
KAORI KOYAMA, HISAHITO ENDO and YOSHIKAZU ASHINO

*Department of Surgery, Fukushima Rosai Hospital, Fukushima*

(Received September 3, 2004, accepted October 21, 2004)

**Abstract :** Annular pancreas is a rare congenital anomaly, which consists of a ring of pancreatic tissue partially or completely encircling the descending portion of the duodenum. We reported a case of symptomatic annular pancreas in a 40 year-old man admitted to our hospital complaining of abdominal pain, nausea and vomiting without body weight loss in January 2000. The patient underwent laparoscopic cholecystectomy for acalculous cholecystitis in September 1996. Initially, he was diagnosed with duodenal stenosis due to a duodenal ulcer scar, but laboratory data showed no abnormalities. His symptoms did not improve with medication or endoscopic balloon dilatation. Duodenography revealed a narrow segment with a smooth mucosal surface in the 2nd portion of the duodenal loop in the duodenum, and a computed tomography (CT) scan demonstrated a thickened pancreas head around this narrow segment. We were therefore able to diagnose annular pancreas. A duodeno-duodenostomy was performed in March 2000. The patient's postoperative course was uneventful, and he was discharged from our hospital on the 19th postoperative day. Although definite diagnosis of annular pancreas is frequently made at laparotomy, the development of a recurrent imaging modality might assist in the preoperative diagnosis.

**Key words :** Annular pancreas, adult, duodeno-duodenostomy

### INTRODUCTION

Annular pancreas is a rare congenital anomaly named by Ecker<sup>1)</sup> in 1862, which consists of a ring of pancreatic tissue partially or completely encircling the descending portion of the duodenum. Half the cases of annular pancreas develop during neonatal and infantile periods as a result of duodenal atresia or stenosis. However,

---

宮澤正紹, 武藤 淳, 佐藤正幸, 児山 香, 遠藤久仁, 蘆野吉和  
Correspondence to : Masatsugu Miyazawa, Department of Surgery, Fukushima Rosai  
Hospital, 3 Numajiri, Uchigo-tzuramati, Iwaki City 973-8403, Japan.  
E-mail : m-miyazawa@fukushima-rosai.jp

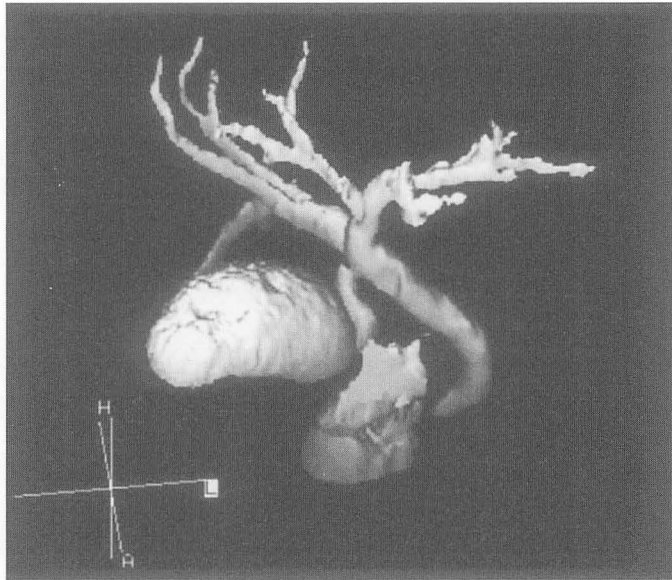


Fig. 1. Drip infusion cholangiographic three dimensional CT shows no abnormality of the biliary tract and just a slight dilatation of the common bile duct before laparoscopic cholecystectomy.

the clinical symptoms of annular pancreas in adults are poor, and diagnosis is usually made at surgery or autopsy. In this study, we report a case of annular pancreas diagnosis in an adult.

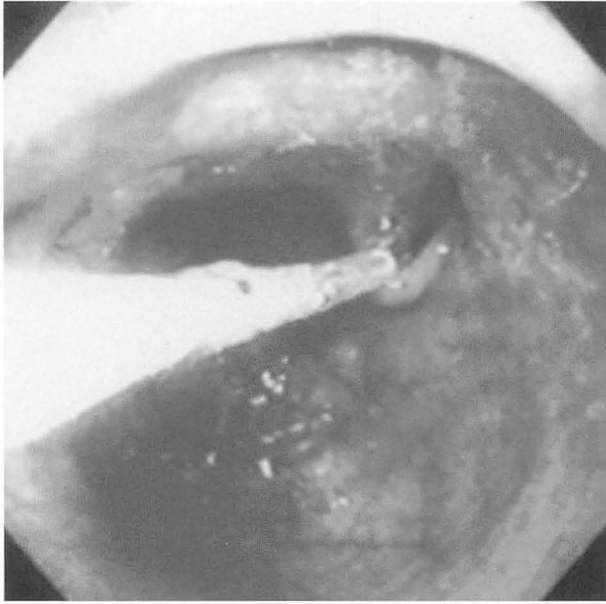
#### CASE REPORT

A 40 year-old man was admitted to our hospital complaining of nausea and vomiting without body weight loss in January 2000. The patient underwent laparoscopic cholecystectomy for acalculous cholecystitis in September 1996 (Fig. 1). Initially, he was diagnosed with duodenal stenosis due to the presence of a duodenal ulcer scar. His symptoms did not improve with medication or endoscopic balloon dilatation (Fig. 2). Duodenography revealed a narrow segment with a smooth mucosal surface in the 2nd portion of the duodenal loop in the duodenum (Fig. 3). A computed tomography (CT) scan demonstrated thickened soft tissue around this narrow segment (Fig. 4); therefore, we were able to diagnose annular pancreas.

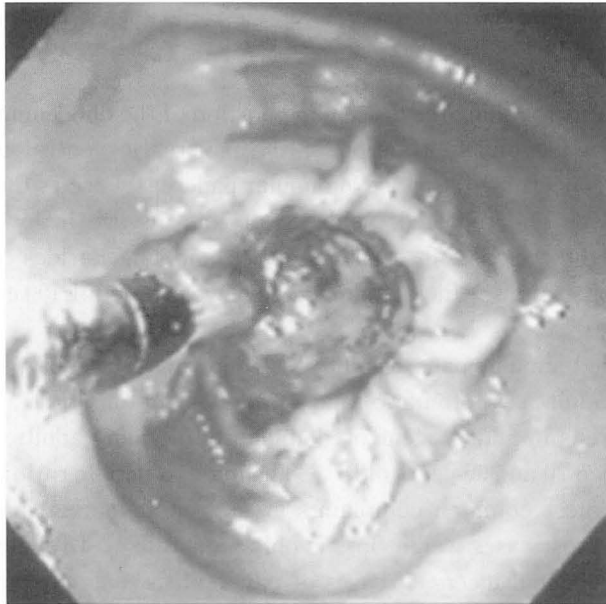
We confirmed it was annular pancreas from operative findings (Fig. 5), and a duodeno-duodenostomy was performed in March 2000. The patient's postoperative course was uneventful, and he was discharged on the 19th postoperative day.

#### DISCUSSION

Annular pancreas is a rare congenital malformation characterized by a ring of



(a)



(b)

Fig. 2. (a) Endoscopic findings revealing severe stenosis of the duodenum proximal to the papilla of Vater with a smooth mucosal surface. (b) Endoscopic balloon dilatation was therefore performed.

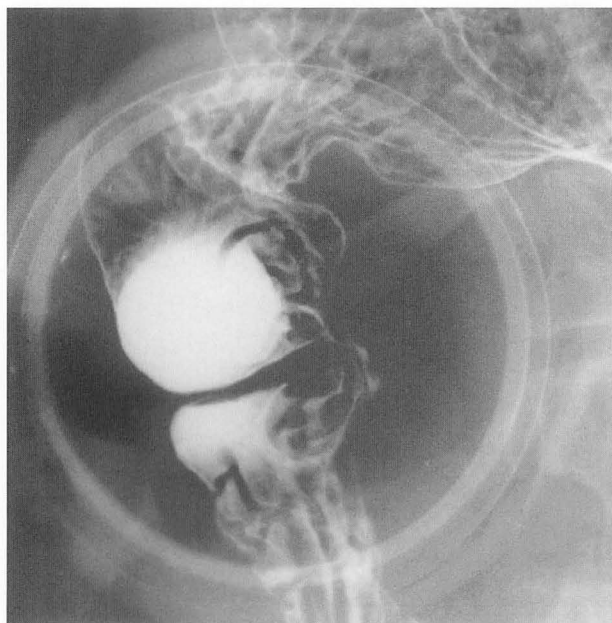
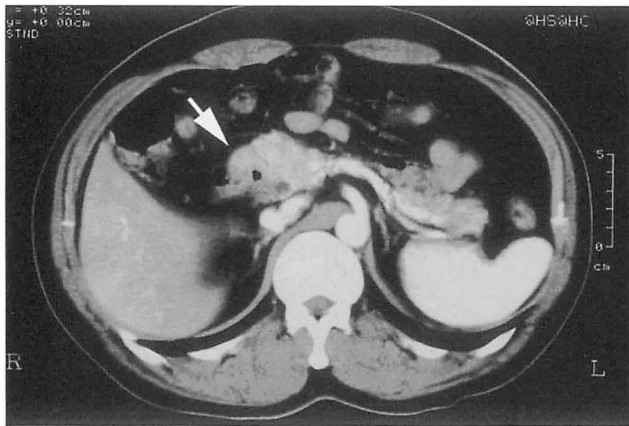


Fig. 3. Upper gastrointestinal series demonstrating eccentric narrowing and medial retraction in the duodenal sweep in the 2nd portion of the duodenum with a smooth mucosal surface.

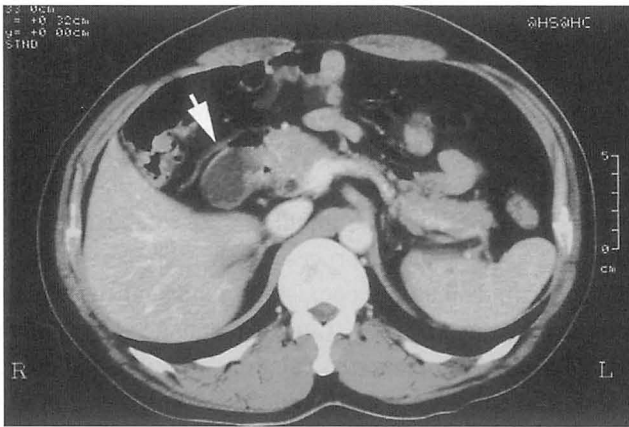
pancreatic tissue surrounding the descending portion of the duodenum. It is thought to originate from incomplete rotation of the pancreatic ventral bud<sup>2-4</sup>). Of the several theories concerning the cause of annular pancreas, Lecco's theory is the most widely accepted<sup>2</sup>). The reported incidence of this disease is low, for example, Ravitch<sup>5</sup>) reported three cases in 20,000 autopsies, and Theodorides<sup>6</sup>) described three cases in 24,519 operations. In Japan, Yogi reviewed in detail 109 cases of annular pancreas in adults<sup>7</sup>).

Drey classified annular pancreas into the following four subtypes: 1) neonatal, 2) pediatric, 3) adult-asymptomatic, and 4) adult-symptomatic<sup>8</sup>). The symptoms of annular pancreas in adults occur predominantly in young adults, and more than half occur between 20 and 50 years old<sup>3,8</sup>). The male to female ratio is approximately 2:1<sup>7,8</sup>). The most common complaints are upper abdominal pain, nausea and vomiting, but in most cases weight loss is only moderate<sup>3</sup>). Drey also described 17 cases of gastroduodenal ulcers, 15 cases of pancreatitis, one case of cholecystitis/cholelithiasis, and jaundice in 62 adult cases of annular pancreas<sup>8</sup>). Urayama *et al.*<sup>9</sup>) described 5 cases of cholecystectomy, one of cholecystitis, gastric ulcer, and one of pancreatitis as past medical histories in 7 cases of annular pancreas. These incidences of pancreatitis or biliary tract disease may be associated with duct obstruction or stricture in the pancreatic drainage and biliary tract systems.

The case presented here was a 40 year-old man who complained of nausea and vomiting without body weight loss. He previously underwent laparoscopic



(a)



(b)

Fig. 4. (a) Contrast-enhanced CT demonstrating the thickened pancreas head (arrow) around the narrow segment of the duodenal loop, and (b) the dilated second portion of the duodenum (arrow) proximal to the stenosis.

cholecystectomy for acalculous cholecystitis, which might have been caused by an abnormality of the biliary tract and/or the pancreatic duct as a result of annular pancreas. However, we were unable to demonstrate that the cholecystitis was associated with an abnormality of the biliary tract or the pancreatic duct by three dimensional CT for biliary tract examination, and the laparoscopic cholecystectomy in September 1996.

Diagnosis of annular pancreas in adults cannot be made on the basis of clinical findings alone. Multimodality methods including upper gastrointestinal series, CT, endoscopic retrograde cholangiopancreatography (ERCP), endoscopic ultrasound (EUS), and magnetic resonance cholangiopancreatography (MRCP) have been applied to diagnose this disease. The upper gastrointestinal series is the most common diagnostic method, and double-contrast upper gastrointestinal studies are

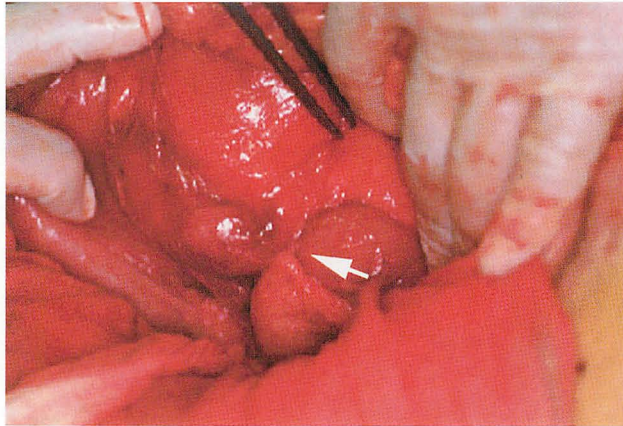


Fig. 5. Operative findings showing annular pancreas (arrow) almost completely obstructing the second portion of the duodenum

generally superior to single-contrast studies in fully evaluating the duodenum. If near complete obstruction of the duodenum exists, only proximal dilatation might be seen, with a slight trickle of contrast through the narrowed segment. With lesser degrees of obstruction, however, there is eccentric narrowing and medial retraction of the duodenal sweep at the level the annulus. The duodenal mucosa is usually normal unless there is an associated process such as pancreatitis or peptic ulcer disease<sup>10</sup>. CT is useful in delineating coexistent abnormalities such as pancreatitis or pancreatic and duodenal neoplasms. Contrast-enhanced abdominal CT is useful in directly visualizing the complete or partially annular pancreatic tissue and apparent circumferential thickening of the duodenal wall associated with duodenal stenosis<sup>11</sup>. ERCP is particularly useful in visualizing the annulus duct coursing around the duodenum, and its also useful in evaluating other diagnoses such as pancreaticobiliary abnormalities or neoplasms<sup>11,12</sup>. EUS and MRCP have been used for diagnosis in several reports<sup>13-15</sup>. For example, Gress *et al.*<sup>13</sup> reported two cases using EUS and suggested an algorithm approach for differential diagnosis utilizing EUS for duodeno-pancreatic abnormalities.

In our case, the UGI series showed eccentric narrowing and medial retraction of the duodenal sweep at the level of the annulus without mucosal abnormalities by endoscopic examination. Furthermore, contrast-enhanced abdominal CT directly demonstrated complete annular pancreatic tissue, and indirectly, dilatation of the duodenum associated with duodenal stenosis. We could not perform examination by ERCP because of severe duodenal stenosis proximal to the papilla of Vater.

Yogi *et al.*<sup>16</sup> reported in detail the surgical procedures of 106 annular pancreas patients in Japan since 1922. Forty-nine patients were correctly diagnosed pre-operatively, but direct surgery was only performed in 26 patients. The Whipple procedure was performed on 16 patients, 9 of whom had malignant diseases. A bypass was performed on 26 patients and included 14 cases of duodenoduodeno-

tomy, and a Billroth II gastrectomy was performed on 28 patients. The preferred treatment is a bypass operation such as a duodenoduodenostomy or duodenojejunostomy.

In our case we were able to diagnose annular pancreas pre-operatively and confirm it intra-operatively. A duodenoduodenostomy was performed due to the lack of pancreatic and duodenal neoplasms or pancreatitis.

In conclusion, annular pancreas is rare in adults but should be considered in the differential diagnosis of pancreatic and duodenal neoplasms and pancreatitis. Although diagnosis of annular pancreas is frequently made at laparotomy, the development of a recurrent imaging modality might assist in preoperative diagnosis.

#### REFERENCES

1. Ecker A. Bildungsfehler des Pankreas und des Herzens. *Z Rat Med*, **14**: 354-356, 1862.
2. Lecco TM. Zur Morphologie des Pankreas Annulare. *Sitzungsb Wein Akad Wissensch*, **119**: 391-406, 1910.
3. Lloyd-Jones W, Mountain JC, Warren KW. Annular pancreas in the adult. *Ann Surg*, **176**: 163-170, 1972.
4. Suda K. Immunohistochemical and gross dissection studies of annular pancreas. *Acta Pathol Jpn*, **4**: 505-508, 1990.
5. Ravitch MM. The pancreas in infants and adults. *Surg Clin North Am*, **55**: 377-385, 1975.
6. Theodorides T. Pancreas annulare. *J Chir*, **87**: 445-462, 1964.
7. Yogi Y, Shibuya T, Hshimoto S. Annular pancreas detected in adults, diagnosed by endoscopic retrograde cholangiopancreatography: Report of four cases. *Gastroenterol Jpn*, **22**: 92-99, 1987.
8. Drey NW. Symptomatic annular pancreas in the adult. *Ann Int Med*, **46**: 750-772, 1957.
9. Urayama S, Kozarek R, Ball T, Brandabur J, Traverso L, Ryan J, Wechter D. Presentation and treatment of annular pancreas in an adult population. *Am J Gastroenterol*, **90**: 995-999, 1995.
10. Faerber EN, Friedman AC, Dabiezies MA. Annular pancreas. *In*: Friedman AC, Dachman AH, eds. *Radiology of the liver, biliary tract, pancreas*. Mosby-Year Book, St. Louis, 745-748, 1994.
11. Jadvar H, Mindelzum RE. Annular pancreas in adults: imaging feature in seven patients. *Abdom Imaging*, **24**: 174-177, 1999.
12. Rizzo RJ, Szucs RA, Turner MA. Congenital abnormalities of the pancreas and biliary tree in adults. *Radiographics*, **15**: 49-68, 1995.
13. Gress F, Yiengpruksawan A, Sherman S, Ikenberry S, Kaster S, Ng RY, Cerulli MA, Lehman GA. Diagnosis of annular pancreas by endoscopic ultrasound. *Gastrointest Endosc*, **44**: 485-489, 1996.
14. Fulcher AS, Turner MA. MR pancreatography: A useful tool for evaluating pancreatic disorders. *Radiographics*, **19**: 5-24, 1999.
15. Lecesne R, Stein L, Reinhold C, Bret MP. MR cholangiopancreatography of annular pancreas. *J Comput Assist Tomogr*, **22**: 85-86, 1998.
16. Yogi Y, Kosai S, Higashi S, Iwamura T, Setoguchi T. Annular pancreas associated with pancreatolithiasis: a case report. *Hepato-Gastroenterology*, **46**: 527-531, 1999.