

[Case Report]

**A SURGICAL CASE OF AORTIC VALVE REPLACEMENT IN PATIENT
WITH CHRONIC IDIOPATHIC THROMBOCYTOPENIC PURPURA**

YOICHI SATO¹⁾, HITOSHI YOKOYAMA¹⁾, MASAOKI WATANABE²⁾
and OSAMI HAMADA²⁾

¹⁾*Department of Cardiovascular Surgery, Fukushima Medical University
School of Medicine, Fukushima*

²⁾*Department of Cardiovascular Surgery, Fukushima Prefectural
Aizu General Hospital, Aizuwakamatsu*

(Received April 8, 2004, accepted May 14, 2004)

Abstract : A 64-year-old man was presented to another hospital with bleeding from the upper jaw with a platelet count of $0.1 \times 10^4 / \mu\text{l}$ one year ago, and idiopathic thrombocytopenic purpura complicated with aortic stenosis and regurgitation was diagnosed. Corticosteroid administration was initiated and the patient was admitted to our hospital for surgery two months after confirmation of symptoms associated with cerebral ischemia. Corticosteroid was administered for one year until the day of surgery, and aortic valve replacement was performed with a platelet count of $8.4 \times 10^4 / \mu\text{l}$. During surgery, bleeding tendency with decreased platelets was confirmed, which was corrected with intraoperative platelet transfusion, postoperative γ -globulin administration, and postoperative oral corticosteroid administration. Caution must be exercised against perioperative bleeding tendency in open heart surgery, even when platelet count is maintained using small amounts of preoperative corticosteroid.

Key words : idiopathic thrombocytopenic purpura (ITP), open-heart surgery, aortic valve replacement

INTRODUCTION

Reports on open-heart surgery in patients with idiopathic thrombocytopenic purpura (ITP) are rare. In addition to managing low platelet counts and decreased function, managing perioperative bleeding using extracorporeal circulation and heparin is important. We performed aortic valve replacement (AVR) on a patient

佐藤洋一, 横山 齐, 渡辺正明, 浜田修三

Correspondence to: Yoichi Sato, Cardiovascular Surgery, Fukushima Medical University
School of Medicine, Fukushima City 960-1295, Japan.

E-mail: yoichi-s@fmu.ac.jp

with aortic stenosis and regurgitation (ASR) complicated by ITP by administering corticosteroid until just before surgery, transfusing platelets during and after surgery, administering γ -globulin after surgery, and resuming corticosteroid administration soon after surgery. Perioperative management of platelet count and the prevention and treatment of bleeding tendency are discussed herein, with reference to the literature.

CASE REPORT

The patient was a 64-year-old man who had noticed purpura appearing on the extremities 2 years earlier. At 63-years-old, he had been admitted to another hospital with bleeding from the upper jaw. On admission to that hospital, platelet count was markedly low ($0.1 \times 10^4/\mu\text{l}$), while PAIgG levels were high at 375 ng/ 10^7 cells. Myelogram only revealed a mild increase in megakaryocytes without platelets. Based on these findings, ITP was diagnosed. Prednisolone (PSL) at 60 mg/day was therefore initiated, and PSL dose was markedly reduced over time. Echocardiography performed for detailed analysis of a heart murmur revealed ASR. The patient was being treated on an outpatient basis, but began to exhibit symptoms associated with cerebral ischemia such as fainting, and was referred to our hospital for surgery.

On admission, the patient was 165 cm tall and weighed 55 kg, with a blood pressure of 118/50 mmHg and a heart rate of 70 beats/minute (sinus rhythm). To-and-fro murmur was audible in the third left intercostal space, but no edema or purpura was seen. When the patient was admitted to our hospital, PSL was reduced to 5 mg/day, and platelet count increased to $9.2 \times 10^4/\mu\text{l}$ and PAIgG level decreased to 62.5 ng/ 10^7 cells. Coombs' test and anti-platelet antibodies yielded negative results, and while no abnormalities in coagulation or fibrinolysis were observed, bleeding time was long, at 5 minutes. Electrocardiography confirmed sinus rhythm, left ventricular hypertrophy and left ventricular overloading, while chest radiography revealed CTR of 54%, but no abnormal shadows were seen in the lung field. Chest CT showed marked calcification of the aortic valve and marked thickening of the left ventricular myocardium. Transesophageal echocardiography revealed calcification and thickening of the aortic valve and fusion of the left and right coronary cusps. The valvular area was reduced to 0.62 cm², and thickening of the left ventricular myocardium and interventricular septum were confirmed. Cardiac catheterization confirmed grade II aortic regurgitation as assessed using the Sellers classification system, and a systolic pressure gradient of 98 mmHg between the left ventricle and aorta.

ASR complicated by ITP was diagnosed based on the above findings, and as symptoms associated with cerebral ischemia had been confirmed, semi-emergency surgery was considered necessary. Preoperative control of ITP was considered important, but since platelet count was maintained using a small dose of PSL,

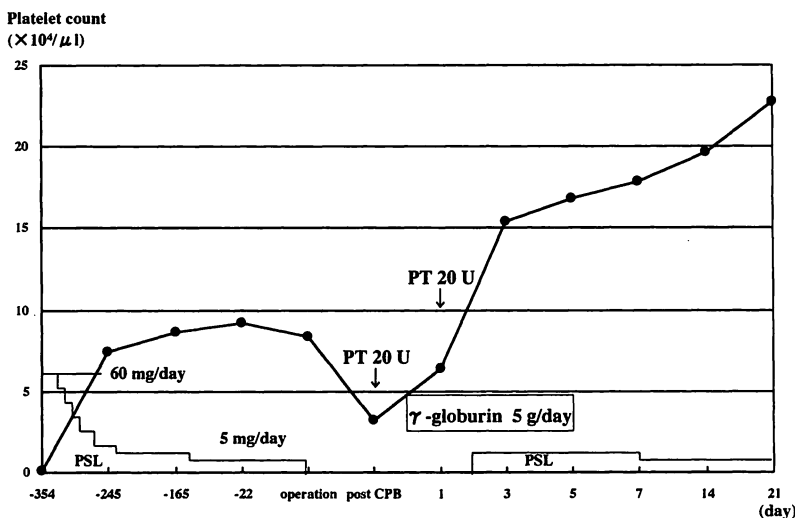


Fig. 1. Changes of pre- and post-operative platelet counts.

PSL : prednisolone, PT : platelet transfusion, CPB : cardiopulmonary bypass

corticosteroid therapy was continued until the day of surgery. Surgery was performed with a platelet count of $8.4 \times 10^4/\mu\text{l}$.

A fusion of the left and right coronary cusps in the aortic valve was marked and was complicated by calcification of the cusp and ring regions. The valvular opening was narrow, and prosthetic valve replacement was performed after valvotomy using a 23-mm Carbomedics valve. During surgery, platelet count decreased to $3.2 \times 10^4/\mu\text{l}$, and bleeding tendency was confirmed. Transfusion of 20 units of platelets was therefore undertaken. Total extracorporeal circulation time was 120 minutes, total duration of aortic clamp was 87 minutes, and total volume of intraoperative hemorrhage was 1,012 ml. For postoperative management of ITP, 5 g/day of γ -globulin was administered for five days starting on the day of surgery, and PSL administration was resumed from two days after surgery. As the amount of bleeding through the drainage tube on the day of surgery was high, at 600 ml, and platelet count one day after surgery was low at $6.4 \times 10^4/\mu\text{l}$, 20 units of platelets were transfused. Bleeding volume subsequently decreased to 170 ml the next day and to 30 ml the day after that. The drainage tube was removed three days postoperatively, and platelet count increased and stabilized (Fig. 1).

DISCUSSION

In ITP, platelets are damaged due to autoantibodies (IgG antibody) and immune complexes. Platelet lifespan is reduced because of this accelerated platelet destruction, and thrombocytopenia leads to bleeding tendency^{1,2)}. Also, in open-heart surgery, use of the cardiopulmonary bypass decreases platelet count by 25–45%

compared to preoperative levels³). Caution must therefore be exercised for patients with ITP to control bleeding during and after surgery.

To the best of our knowledge, 32 cases of open-heart surgery have been performed on patients with ITP in Japan (Table 1). Of these, a prosthetic valve replacement for cardiac valvular disease was performed in 18 patients. Platelet counts immediately prior to surgery ranged from 3.0 to $23.0 \times 10^4/\mu\text{l}$ (mean: $11.7 \pm 5.4 \times 10^4/\mu\text{l}$), and platelets were transfused during and after surgery in 29 patients. Surgery was performed with platelet counts of $<7 \times 10^4/\mu\text{l}$ in seven patients⁴⁻¹⁰, and of these, bleeding during and after surgery posed a problem in only one patient⁶, open-heart surgery and splenectomy were performed concurrently in two patients^{5,10}, and in another patient⁸, aprotinin was administered during surgery. Intraoperative and postoperative bleeding posed a problem in seven patients^{6,11-16}, but of these, platelet counts were $>10 \times 10^4/\mu\text{l}$ just before surgery in four patients^{11-13,16}. Hence, no clear correlation between bleeding complication and platelet count is apparent, and even when platelet count is low, surgery can usually be completed with platelet transfusion and different intraoperative and postoperative measures.

In reality, performing open-heart surgery on patients with low platelet counts carries a certain degree of risk, and when performing surgery on patients with ITP, platelet levels of $3.0-7.0 \times 10^4/\mu\text{l}$ are generally considered necessary¹. Regarding preoperative treatment, corticosteroids and immunosuppressants have been administered and splenectomy has been performed in many patients, but bolus intravenous γ -globulin administration has played a central role in recent years. The reasons for this include safety (low number of severe adverse reactions), efficacy (effective in about 80% of patients with chronic ITP) and relatively quick action^{17,18}. The mechanism of bolus intravenous γ -globulin is considered to be Fc receptor blockade of reticuloendothelium and macrophage decreased auto antibody synthesis, protection of platelets and megakaryocytes from antiplatelet antibody, and clearance of persistent viral infection by specific antibody⁹. However, the effects of γ -globulin administration are mostly transient, and platelet counts return to preoperative levels within about one month after administration^{8,13}. In particular, when anticoagulation therapy is required after prosthetic valve replacement, oral corticosteroid administration or splenectomy may be needed in the chronic stage¹⁹. In Japan, some reports have described patients who have undergone open-heart surgery with preoperative intravenous administration of bolus γ -globulin and platelet transfusion during and after surgery. However, no reports have yet documented ITP management in the chronic stage, and we speculate that either therapy might be required in such cases.

Several studies have reported that platelets bind to anti-platelet antibodies in ITP decrease excessively after cardiopulmonary bypass due to mechanical stimulus^{12,16}. But in the present patient, preoperative platelet counts were maintained using only small doses of PSL, and we thought that transfusion of platelets during and after surgery and resumption of PSL therapy soon after surgery would be

Table 1 Reported cases of open heart surgery with ITP in Japan.

Case No.	Author	Year	Age, Sex	Diagnosis	Procedure	Pre-op. management	Effect	Changes of PLT ($\times 10^4/\mu\text{l}$)	PT	Outcome
1	Abe	1973	46, F	ASD	Direct closure	STE/PT	G/G	3.0 → 14.0	(+)	Hemothorax
2	Nakazawa	1973	28, F	MS	CMC	STE/PT	P/G	—	(+)	Good
3	Kaihotsu	1978	35, F	MSR	MVR	STE/PT/SN	P/G/G	3.0 → 23.0	(+)	Good
4	Ohira	1979	7, M	VSD	Patch closure	STE	P	6.0 → 6.0	(+)	Good
5	Shimamoto	1987	55, M	MR	MVR	GLB	G	—	(+)	Good
6	Iida	1988	63, M	CAD	CABG	GLB	G	2.9 → 16.0	(+)	Bleeding
7	Koike	1989	37, M	CAD	CABG+SN	—	P	0.8 → 2.8	(+)	Good
8	Terada	1990	67, F	CAD	CABG	SN/GLB	P/G	5.8 → 12.8	(+)	Bleeding
9	Yamashita	1990	40, F	ASD	Direct closure	STE	G	0.7 → 20.6	(+)	Good
10	Mori	1991	49, M	ASr	AVR+SN	GLB	G	3.4 → 14.6	(+)	Good
11	Nakayama	1992	58, F	Active IE	AVR	—	P	3.0 → 3.0	(+)	Difficult hemostasis
12	Nimura	1992	67, M	ASr	AVR	GLB	P	8.2 → 7.3	(+)	Good
13	Sunami	1993	62, M	AsR, MSr	DVR	GLB/PT/SN	P/P/P	3.7 → 9.0	(+)	Difficult hemostasis
14	Yoshida	1993	62, M	PVF	Re-MVR	STE/GLB	P/P	5.2 → 5.6	(+)	Good
15	Sato	1994	60, F	MS	MVR	GLB	G	6.8 → 9.1	(-)	Good
16	Sato	1994	60, M	CAD	CABG+SN	GLB	G	1.4 → 8.7	(+)	Bleeding, Thrombocytosis
17	Tanaka	1994	77, F	AS	AVR	STE/GLB/SN	P/G/G	2.6 → 23.0	(+)	Good
18	Hayashi	1996	76, F	CAD	CABG	GLB	G	5.3 → 19.9	(+)	Good
19	Yamada	1996	57, F	MSR	MVR+SN	STE/GLB	G/G	3.0 → 10.0	(-)	Good
20	Yanagiya	1996	68, M	AS, TAA	Bentall+arch	STE	G	3.0 → 5.1	(+)	Good
21	Kohyama	1997	58, M	MR	MVP	GLB/SN	G/G	7.6 → 16.1	(+)	LA thrombus
22	Orime	1997	65, F	MS, TR	MVR+TAP+SN	GLB	G	4.3 → 13.5	(+)	Good
23	Goshima	1999	62, M	MR	MVR	GLB/SN	P/G	5.6 → 12.0	(+)	Good
24	Nagumo	1999	58, F	MR, TR ASD	MAP, TAP Direct closure	GLB	P	5.0 → 6.4	(+)	Good
25	Kumamoto	1999	61, M	AR	AVR	GLB	G	5.0 → 11.4	(-)	Good
26	Kaneda	1999	63, F	AR, MR	DVR	STE/SN	G/G	? → 18.0	(+)	Bleeding
27	Hirose	2000	66, F	AS	AVR+SN	GLB	P	6.0 → 7.0	(+)	Good
28	Oba	2000	41, M	MR	MVR	STE/GLB	P/G	5.0 → 8.2	(+)	Good
29	Tanabe	2000	53, F	MS, LAT	OMC, resection	PT	G	4.0 → 13.0	(+)	Good
30	Koyanagi	2000	53, M	MS (redo)	MVR, SN	GLB	G	3.8 → 12.8	(+)	Good
31	Matsuzaki	2001	80, M	AAA	GR, AVP	GLB	G	1.6 → 11.2	(+)	Good
32	Ohno	2002	76, F	CAD	CABG	GLB	G	5.7 → 11.0	(+)	Good

AAA: ascending aortic aneurysm, AR: aortic regurgitation, AS: aortic stenosis, ASD: atrial septal defect, AVR: aortic valve replacement, AVP: aortic valvuloplasty, CAD: coronary artery disease, CABG: coronary artery bypass grafting, CMC: closed mitral commissurotomy, DVR: double valve replacement, GR: graft replacement, IE: infectious endocarditis, LAT: left atrial thrombus, MR: mitral regurgitation, MS: mitral stenosis, MVP: mitral valvuloplasty, MVR: mitral valve replacement, OMC: open mitral commissurotomy, PVF: prosthetic valve failure, TAP: tricuspid annuloplasty, VSD: ventricular septal defect, SN: splenectomy, GLB: intravenous gammaglobulin, STE: corticosteroids, PT: platelet transfusion, G: good, P: poor.

important, surgery was therefore performed without preoperative γ -globulin administration. Cases of infection due to steroid administration have not yet been reported in Japan, but postoperative infection represents a severe complication associated with steroid administration. In the present patient, γ -globulin was administered postoperatively to not only prevent infection, but also elevate platelet count following unexpected thrombocytopenia and bleeding tendency. As far as simultaneous open-heart surgery and splenectomy is concerned, several studies have reported this combination as highly invasive, associated with complications such as bleeding, and effective only transiently^{13,14}, and platelet count reportedly increases excessively after a splenectomy, making management of anticoagulation therapy following valve replacement difficult¹⁰. But other numerous studies have reported that this combination was effective in more than 70% of cases and was effective for a long period of time with free of oral corticosteroid administration^{16,19}. As a result, splenectomy was not performed on the present patient for fear of bleeding, but in hindsight, preoperative intravenous γ -globulin administration and simultaneous splenectomy should have been performed to prevent intraoperative and postoperative bleeding and to gain complete remission of ITP in remote stage. Although platelet count has remained stable after discharge using low dosage PSL, careful follow-up of the present patient and possible remote-stage splenectomy will be necessary.

REFERENCES

1. Naganuma H, Mashiko K, Tanaka K. Impending ruptured abdominal aneurysm in a patient with chronic idiopathic thrombocytopenic purpura. (in Japanese) *Jpn J Cardiovasc Surg*, **30**: 220-222, 2001.
2. Sato M, Konno S, Maemura T, Goto K, Hayashibe Y, Ito J. A case of mitral valve replacement with chronic idiopathic thrombocytopenic purpura after high-dose immunoglobulin infusion. (in Japanese) *J Jpn Assoc Thorac Surg*, **42**: 2000-2002, 1994.
3. Goshima M, Akiyama K, Koga M, Inoue T, Nemoto M, Negishi S, Sezai Y. A case of mitral valve replacement combined with idiopathic thrombocytopenic purpura (ITP). (in Japanese) *Kyobu Geka*, **52**: 573-577, 1999.
4. Koike R, Suma H, Oku T, Satoh H, Sawada Y, Takeuchi A. Combined coronary revascularization and splenectomy. *Ann Thorac Surg*, **48**: 853-854, 1989.
5. Ohira M, Noto T, Oki T, Kawamura Y. Ventricular septal defect associated with idiopathic thrombocytopenic purpura. (in Japanese) *Kyobu Geka*, **32**: 703-706, 1979.
6. Nakayama Y, Sakai M, Natsuaki M, Ito T, Suda H, Rikitake K. Active infective endocarditis with Idiopathic thrombocytopenic purpura: A case report. (in Japanese) *Kyobu Geka* **45**: 1004-1006, 1992.
7. Yoshida H, Sangawa K, Sakakibara Y, Suehiro K, Okada M, Shitijoh T, Ohba O. A case of mitral valve re-replacement combined with idiopathic thrombocytopenic purpura. (in Japanese) *Jpn J Cardiovasc Surg*, **22**: 372-375, 1993.
8. Yanagiya A, Kazui T, Tanaka H. A successful case report of composite graft and total aortic arch replacement in a patient with chronic idiopathic thrombocytopenic purpura (ITP). (in Japanese) *J Jpn Assoc Thorac Surg*, **44**: 1168-1171, 1996.
9. Nagumo M, Kiso I, Takehashi R, Mori A, Masuda Y. Redo cardiac surgery for atrial

- septal defect in a patient with idiopathic thrombocytopenic purpura. *J Cardiovasc Surg*, **40**: 549-552, 1999.
10. Hirose H, Shiono M, Orime Y, Yagi S, Yamamoto T, Okumura H, Hata M, Negishi N, Sezai Y, Matsukawa Y. A case of aortic valve replacement in patient with chronic idiopathic thrombocytopenic purpura. (in Japanese) *Jpn J Cardiovasc Surg*, **29**: 400-403, 2000.
 11. Abe T, Okamura E, Kamiya T. A case of atrial septal defect with idiopathic thrombocytopenic purpura. (in Japanese) *J Jpn Assoc Thorac Surg*, **21**: 1093-1096, 1973.
 12. Iida H, Kitamura N, Yamaguchi A, Fukushima Y, Ohtaki M, Minoji T. A-C bypass grafting and ligation of coronary arteriovenous fistula in a patient with idiopathic thrombocytopenic purpura. (in Japanese) *J Jpn Assn Thorac Surg*, **36**: 2296-2300, 1988.
 13. Terada Y, Ino T, Wanibuchi Y, Takagi H, Shimoyama Y, Furuta S. A case of CABG in a patient with chronic idiopathic thrombocytopenic purpura. (in Japanese) *J Jpn Assoc Thorac Surg*, **38**: 150-153, 1990.
 14. Sunami H, Nawa S, Nakata T, Hirata S, Yoshitomi I, Miyachi Y, Hayashi K. A case of double-valve replacement in a patient with idiopathic thrombocytopenic purpura. (in Japanese) *Kyobu Geka*, **46**: 486-488, 1993.
 15. Sato Y, Ishikawa S, Ootaki A, Ootani Y, Takahashi T, Morishita Y. Concomitant operation of CABG and splenectomy following high-dose transvenous gamma-globulin therapy in a patient with idiopathic thrombocytopenic purpura—A case report—. (in Japanese) *J Jpn Assoc Thorac Surg*, **42**: 1222-1225, 1994.
 16. Kaneda T, Ku K, Oku H, Inoue T, Matsumoto T, Onoe M, Kitayama H, Iemura J, Nakamoto S, Oka H, Otaki M. Refractoriness to platelet transfusion following double valve replacement in an ITP patient who had undergone splenectomy. *J Card Surg*, **14**: 386-389, 1999.
 17. Mathew TC, Vasudevan R, Leb L, Pezzella SM, Pezzella AT. Coronary artery bypass grafting in immune thrombocytopenic purpura. *Ann Thorac Surg*, **64**: 1059-1062, 1997.
 18. Christiansen S, Schmid C, Redmann K, Jahn UR, Stypmann J, Scheld HH, Hammel D. Preoperative immunoglobulin treatment in patients with werlhof's disease undergoing cardiac operation. *Ann Thorac Surg*, **69**: 61-64, 2000.
 19. Yamada T, Takagi M, Miyagawa N, Shibata R, Hashiyada H, Kugimiya T. Simultaneous mitral valve replacement and splenectomy in a patient with chronic idiopathic thrombocytopenic purpura. (in Japanese) *J Jpn Assoc Thorac Surg*, **44**: 1809-1813, 1996.