

CHANGES IN THE FATTY ACID COMPOSITION AND HYDROXYPROLINE CONTENT IN RAT LUNG IN RELATION TO COLLAGEN SYNTHESIS AFTER PARAQUAT ADMINISTRATION

TETSUHITO FUKUSHIMA¹, KEIKO TANAKA², HEEJIN LIM³
and MASAKI MORIYAMA²

¹*Department of Hygiene & Preventive Medicine, Fukushima Medical University
School of Medicine, Fukushima*

²*Department of Public Health, School of Medicine, Fukuoka University, Fukuoka*

³*Department of Health Education, Ewha Womans University, Seoul, Korea*

(Received March 17, 2003, accepted May 6, 2003)

Abstract : Objectives : Effect of paraquat on the fatty acid composition (weight percentage) of rat lung was studied with particular reference to the change of hydroxyproline content in the course of paraquat-induced dysfunction and subsequent repair.

Methods : Eight-week-old male Wistar rats were administered paraquat at 20 mg/kg body weight subcutaneously, and the wet weight, hydroxyproline content and fatty acid composition of lungs of each group rats were analyzed at 2, 7, 14 or 28 days after treatment, respectively.

Results : The percentage of palmitic acid (C16 : 0), arachidonic acid (C20 : 4) and docosahexaenoic acid (C22 : 6) significantly increased, and the percentage of oleic acid (C18 : 1) and the ratio of monounsaturated fatty acids/saturated fatty acids (M/S) significantly decreased comparing to control on day 28 after paraquat administration. The time-course of each fatty acid was observed for 28 days after paraquat administration. M/S ratio decreased after paraquat administration up to the 28th day, but the polyunsaturated fatty acids/saturated fatty acids (P/S) ratio decreased during the first 7 days, followed by a increase, and then reached higher level than the 0 day control at the 28th day. Hydroxyproline also increased between the 14th and the 28th days. Eicosapentaenoic acid (C20 : 5) had once increased during the first 2 days and decreased gradually, while C20 : 4 maintained high level in this period. C22 : 6 increased after paraquat administration and maintained high level up to the 28th day. This result indicated that desaturation and elongation in n-3 series fatty acids were accelerated after paraquat treatment, and consequently C20 : 5 was rapidly converted into C22 : 6 and decreased.

Conclusions : Paraquat might cause elevation of unsaturated fatty acids, espe-

福島哲仁, 田中景子, 林 姫辰, 守山正樹

Correspondence to : Tetsuhito Fukushima, Department of Hygiene & Preventive Medicine,
Fukushima Medical University School of Medicine, Fukushima City 960-1295, Japan.

cially C20 : 4 but not C20 : 5 by the stimulation of the fatty acid desaturase system, and could consequently stimulate local collagen synthesis by C20 : 4 metabolites in the healing stage.

Keywords : paraquat, lipid peroxidation, fatty acid composition, hydroxyproline, pulmonary fibrosis

INTRODUCTION

1, 1'-dimethyl-4, 4'-bipyridium dichloride (paraquat) is a herbicide used all over the world, and it causes fatal damage to multiple organs, especially pulmonary fibrosis, from accidental and suicidal ingestion. The mechanism of pulmonary fibrosis is still unknown, and there is no effective treatment for it.

The mechanism of fibrosis by bleomycin might be partially different from that by paraquat^{1,2)}, but there should be a common feature between them. Diffuse interstitial fibrosis by paraquat was accompanied by an increase of contractile filament laden cells characterized by an expression of alpha-smooth muscle actin, and this phenomenon was observed in cases of bleomycin-injured lungs, too³⁾. A model of diffuse interstitial pulmonary fibrosis by paraquat was compared with bleomycin-induced pulmonary fibrosis, and was concluded to be an adequate experimental model as it occurs in many of human cases⁴⁾.

Several researchers have reported the effect of several fatty acids on lung fibrosis. Dietary eicosapentaenoic acid (C20 : 5) inhibited bleomycin-induced pulmonary fibrosis⁵⁾ and C20 : 5 was effective in the lung damage of cystic fibrosis by leukotriene B₄⁶⁾. Gamma-linolenic acid attenuated bleomycin-induced lung fibrosis⁷⁾.

Because fatty acid is one of the main targets of free radical attack, the influence of paraquat on the fatty acid composition in lung tissue has been paid attention^{8,9)}. But there were few reports about fatty acid composition change after paraquat treatment with particular reference to pulmonary fibrosis. It was reported that weakness of the defense mechanisms by enhancing thromboxane A₂ synthesis initiated pulmonary fibrosis by paraquat¹⁰⁾. Fatty acid composition change, especially the change of arachidonic acid (C20 : 4) which is the key fatty acid of arachidonate cascade should be important to clarify the mechanism of pulmonary fibrosis by paraquat. In this study, change in the fatty acid composition in rat lung after paraquat administration was observed together with change of hydroxyprolin, a specific amino acid to the collagen molecule, in the course of paraquat-induced dysfunction and subsequent repair. And the relation between the change of fatty acid composition in lung tissue and local pulmonary fibrosis was discussed.

MATERIALS AND METHODS

Animal

Eighteen of seven-week-old male Wistar rats purchased from Kyudo Co. Ltd., Tosu, Japan were housed in cages in an air-conditioned room, with artificial lighting from 8 a.m. to 8 p.m., and maintained on pelleted food (CE-2) from Japan Clea, Tokyo, Japan and water ad libitum. The rats were allowed to acclimate in the facilities for 1 week prior to all treatments. Twelve of the rats were administered paraquat at 20 mg/kg body weight (30 mg/ml in physiological saline) subcutaneously, and each group of 3 rats was killed by decapitation and bled at 2, 7, 14 or 28 days after treatment, respectively. Remaining 6 rats were used for the controls, no treatment (3 rats for the 0 day and another 3 rats for the 28th day). Because this experiment was done in the course of paraquat-induced dysfunction and subsequent repair, this route and the dose, slightly lower than LD50, were selected.

Preparation of fatty acid samples in lung tissue

Rat lungs were immediately dissected and weighed, and were homogenized in physiological saline at 4°C. The total lipids of each rat tissue were extracted and the fatty acids were saponified by the previously described method¹¹⁾. Each extracted sample was methylated with ethereal diazomethane for 1 hr at room temperature in the dark. After evaporation of the solvent, it was dissolved in hexane and washed with saturated sodium chloride solution. The extracted hexane phase was dehydrated with anhydrous sodium sulfate and was concentrated by evaporation.

Preparation of amino acid samples in lung tissue

Each sample of homogenized rat lung tissue containing 0.1 g protein was hydrolyzed in 6 N hydrochloric acid at 110°C for 24 h and was dried. Hydrolyzed amino acids were derivatized by the previously described method¹²⁾. Isonipecotic acid was used for the internal standard. The peak of hydroxyproline was identified by the retention time of standard hydroxyproline.

Analysis of fatty acid composition and hydroxyproline content by gas chromatography

Gas chromatography analysis was carried out with a Shimadzu (Kyoto, Japan) GC-14A gas chromatograph equipped with a hydrogen flame ionization detector. The split ratio was 20:1. DB-WAX column (30 m×0.25 mm i.d., 0.25 μ m film thickness) (J & W, Folsom, CA, USA) was used for fatty acid analysis. The separation was achieved on column at temperature ranging 150–220°C (3°C/min). Helium carrier gas and makeup gas flow rates were 1.7 ml/min and 30 ml/min, respectively. DB-17 column (15 m×0.25 mm i.d., 0.25 μ m film thickness) (J & W, Folsom, CA, USA) was used for amino acid analysis. The separation was achieved on column at temperature ranging 140–290°C (30°C/min). Helium carrier gas and

makeup gas flow rates were 1.7 ml/min and 30 ml/min, respectively. The fatty acid composition was expressed as weight percent. The amount of hydroxyproline content was calculated with the internal standard, and the change of it was indicated as the percentage of control. Student's *t*-test was used for paired observations.

RESULTS

The wet weight of lungs increased on the 7th day, followed by a decrease, and then increased again after the 14th day up to the 28th day after paraquat administration, but the final levels were still lower than those of the 28th day control (Fig. 1). The change in hydroxyproline content in rat lung after paraquat administration is shown in Fig. 2. Hydroxyproline increased during the first 2 days, followed by a decrease, and then increased again after the 14th day. The hydroxyproline content on the 28th day after paraquat administration reached to almost same level as the 28th day control one. From these results, the first seven days after paraquat treatment were determined to represent the acute phase, and the 7th and 14th day were regarded as the turning points, and the 28th day were regarded as the endpoint, of this experiment achieved in the course of paraquat-induced dysfunction and subsequent repair.

Fatty acid composition (weight percentage) of rat lung tissue on day 28 after paraquat administration was shown in Fig. 3. Palmitic acid (C16:0), C20:4 and docosahexaenoic acid (C22:6) significantly increased, and oleic acid (C18:1) and monounsaturated fatty acids/saturated fatty acids (M/S) ratio significantly de-

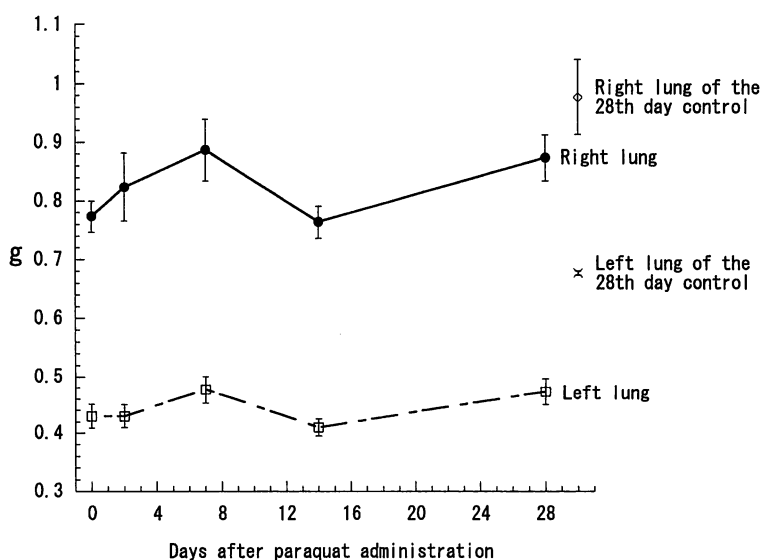


Fig. 1. Change in wet weight of rat lungs after paraquat administration. The point indicates the mean \pm S.E. of three samples.

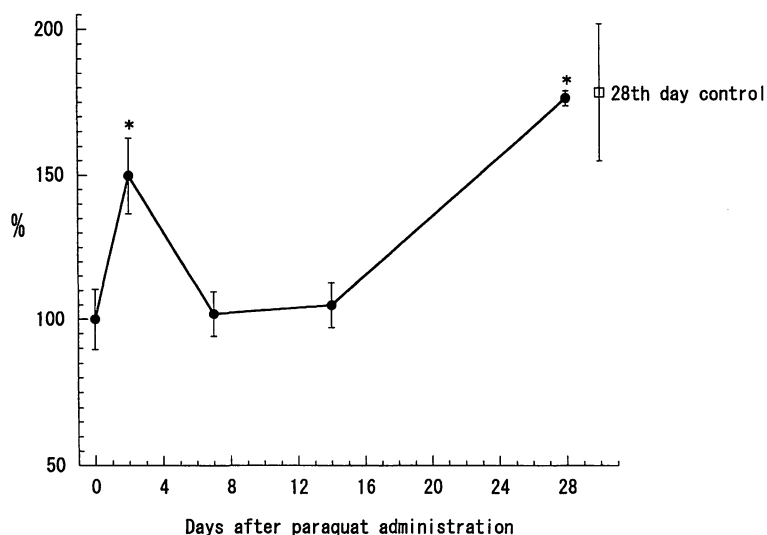


Fig. 2. Change in hydroxyproline content in rat lung after paraquat administration. The point indicates the mean \pm S.E. of the percentage of control from $n=3$ animals. *represents significant difference at $P < 0.05$, comparing with control on day 0.

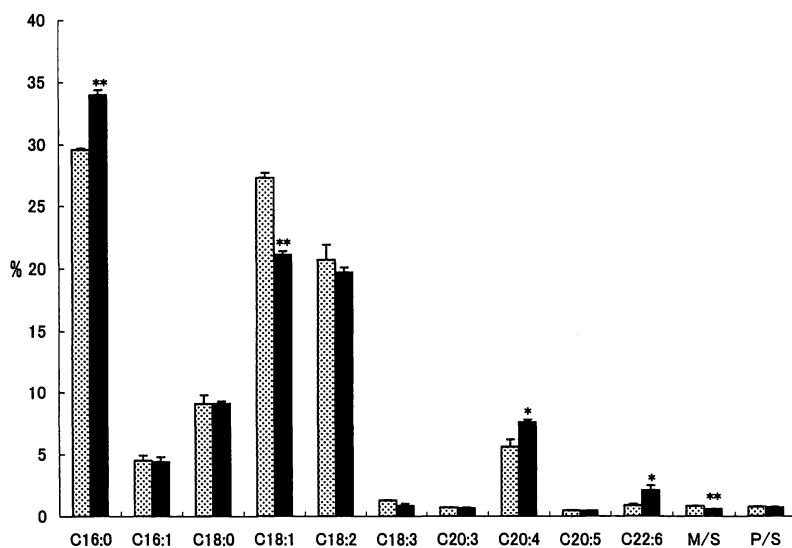


Fig. 3. Fatty acid composition (weight percentage) of rat lung tissue on day 28 after paraquat administration. Each value is mean \pm S.E. of three samples. * and ** represent significant difference at $P < 0.05$ and $P < 0.01$, respectively, comparing with control on day 28. \square , control group; \blacksquare , treated group.

creased comparing to control.

To analyze the change of these fatty acids, the time-course of each fatty acid was observed for 28 days after paraquat administration. Fig. 4 shows the changes

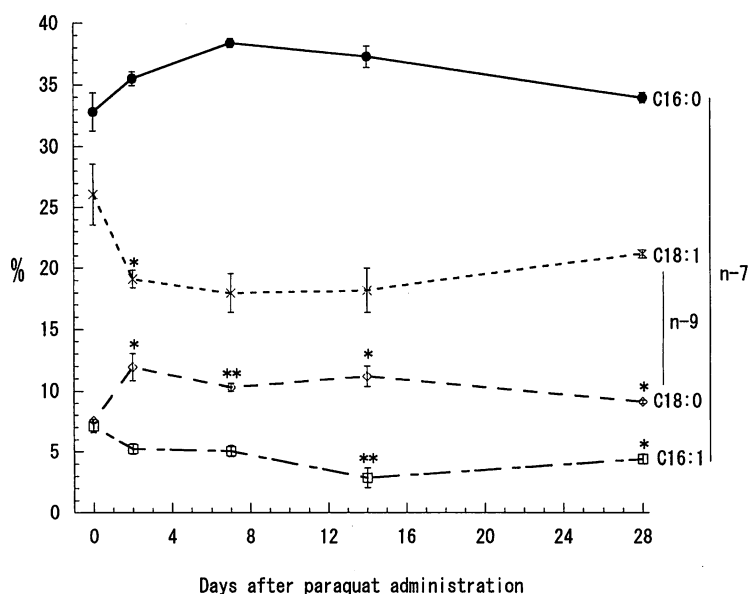


Fig. 4. Changes in the percentage (by weight) of total fatty acids accounted for n-7 (C16:0 and C16:1) and n-9 (C18:0 and C18:1) series fatty acids in rat lung. Each value is the mean \pm S.E. of three samples. * and ** represent significant difference at $P < 0.05$ and $P < 0.01$, respectively, comparing with control on day 0.

in the percentage of total fatty acids accounted for n-7 (C16:0 and palmitoleic acid (C16:1)) and n-9 (stearic acid (C18:0) and C18:1) series fatty acids. In both n-7 and n-9 series, monounsaturated fatty acids (C16:1 and C18:1) decreased, and saturated fatty acids (C16:0 and C18:0) increased after paraquat administration. In both n-7 and n-9 series, saturated fatty acids showed almost opposite change versus the monounsaturated fatty acids. This result indicated that desaturation in n-7 and n-9 series fatty acids was suppressed after paraquat administration.

Changes in the ratios of M/S and polyunsaturated fatty acids/saturated fatty acids (P/S) are shown in Fig. 5. The M/S ratio decreased after paraquat administration up to the 28th day, but the P/S ratio decreased during the first 7 days, followed by an increase, and then reached higher level at the 28th day than the 0 day control.

The changes in the percentage of total fatty acids accounted for n-6 and n-3 series fatty acids are shown in Fig. 6 and in Fig. 7, respectively. In n-6 series fatty acids, linoleic acid (C18:2) decreased during the first two days, and began to increase at the 14th day up to the 28th day. C20:4 increased during the first 2 days, and maintained high level up to the 28th day. C18:2 showed almost opposite change versus C20:4, and desaturation and elongation seemed to be accelerated during the observation period. In n-3 series fatty acids, linolenic acid (C18:3) decreased during the first 2 days and increased, on the other hand C20:5 increased during the first 2 days and decreased gradually. C18:3 showed almost opposite change versus

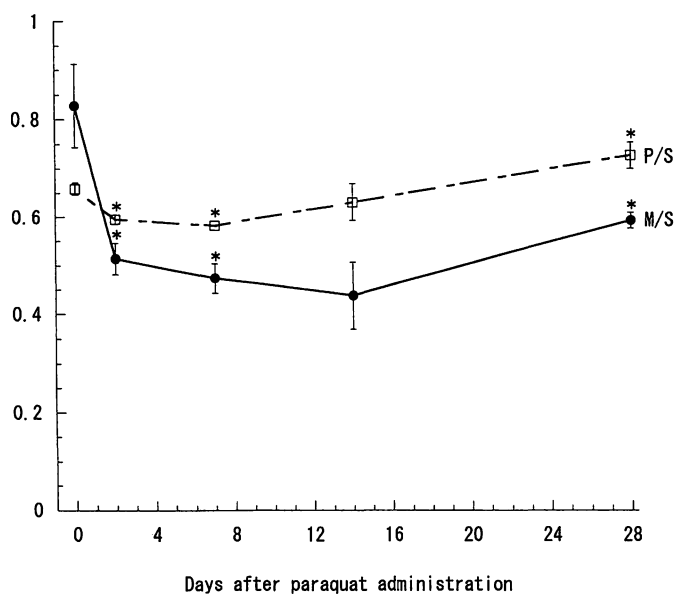


Fig. 5. Changes in the ratios of monounsaturated fatty acids/saturated fatty acids (M/S) and polyunsaturated fatty acids/saturated fatty acids (P/S) in rat lung. Each value is the mean \pm S.E. of three samples. *represents significant difference at $P < 0.05$ comparing with control on day 0.

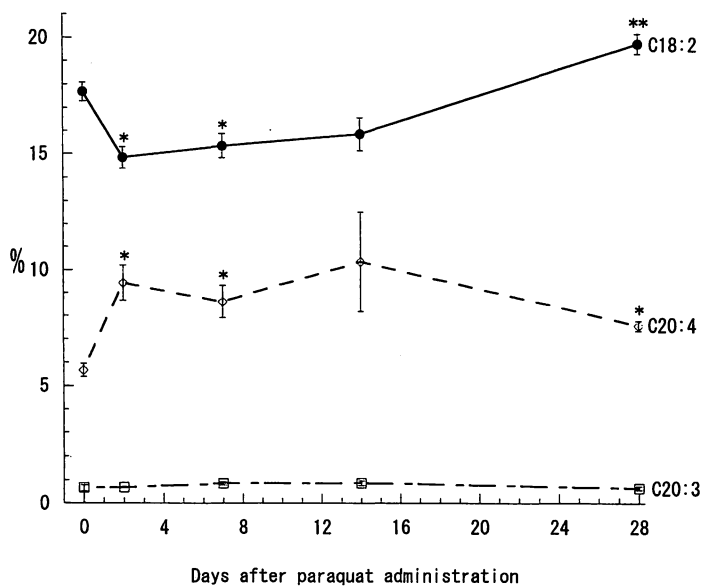


Fig. 6. Changes in the percentage (by weight) of total fatty acids accounted for n-6 series fatty acids (C18:2, C20:3 and C20:4) in rat lung. Each value is the mean \pm S.E. of three samples. * and ** represent significant difference at $P < 0.05$ and $P < 0.01$, respectively, comparing with control on day 0.

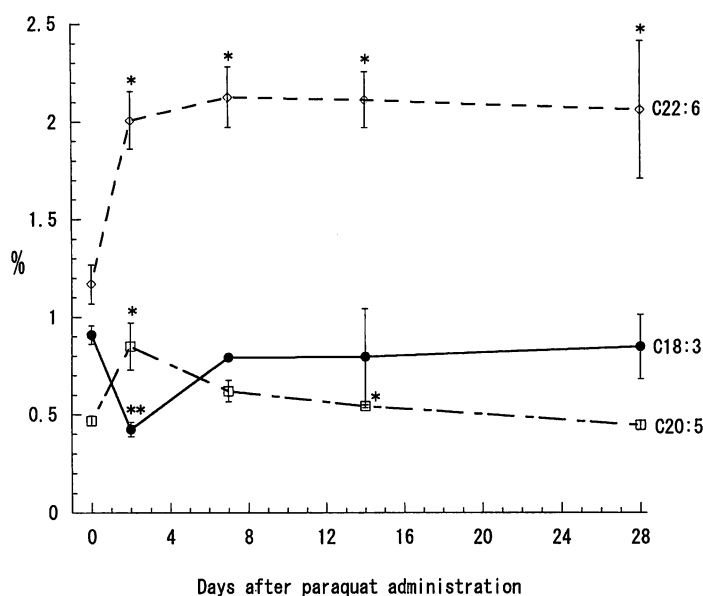


Fig. 7. Changes in the percentage (by weight) of total fatty acids accounted for n-3 series fatty acids (C18:3, C20:5 and C22:6) in rat lung. Each value is the mean \pm S.E. of three samples. * and ** represent significant difference at $P < 0.05$ and $P < 0.01$, respectively, comparing with control on day 0.

C20:5. C22:6 increased after paraquat administration and maintained high level up to the 28th day. These results indicated that desaturation and elongation were accelerated by paraquat treatment in n-3 series fatty acids.

DISCUSSION

According to the reports about paraquat dynamics, the concentration in blood becomes high level quickly, and decreases by excretion in urine via the kidneys. But in lungs, the decrease in paraquat concentration is relatively slow, and it becomes the organ with the highest concentration of paraquat¹³⁻¹⁵). Among complex I subunits, 30-, 42-, and 75- kilodalton proteins are transmembranous and thought to be the sites of paraquat radical formation and initial damage¹⁶). These proteins are encoded by mitochondrial DNA. Compared with nuclear DNA, mitochondrial DNA is sensitive to radical attack. This type of injury to mitochondrial DNA is thought to cause mitochondrial dysfunction and consequently alveolar cell death. Because paraquat is thought to be a "hit and run" poison¹⁷), the candidate sites for future fibrosis might be decided by the degree of damage that occurred when the lung tissue concentration of paraquat was raised in the early stage. Fibrosis is the replacement of injured tissue structures in an organ by fibroblasts and collagen matrix produced by these cells¹⁸).

From the previous study¹⁹), the present observation period shows cytotoxicity

and subsequent healing in the acute and subacute phases following paraquat administration. It was reported that the hydroxyproline content, as an indicator of collagen, was not always increased after paraquat exposure^{20,21}. In the present study, hydroxyproline increased during the first 2 days, followed by a decrease, and then increased again after the 14th day. The hydroxyproline content on the 28th day after paraquat administration was almost same level as the 28th day control one. But there should be difference in the meaning of the level of hydroxyproline content between treated one and control one on the 28th day. It had been reported that presence of fibrosis and increase of hydroxyproline content in rat lung were observed 14 days after 25 mg/kg (i.p.) paraquat exposure²². Lung collagen content also increased steadily between 4 and 14 days after instillation of paraquat (0.001-1.0 mg/kg) into rat lung²³. Hydroxyproline increased in rat lung between days 4 and 10 after total 25 mg/kg of paraquat administration²⁴, while paraquat (0.1-1.0 mM concentration) inhibited hydroxyproline formation and relative collagen synthesis in isolated fibroblasts after 48 h incubation together²⁵. In the present study the first rising of hydroxyproline at the 2nd day seems to reflect the acute phase repair, and the following decrease may reflect this inhibition effect, and the second rising of it after the 14th day may reflect healing stage local fibrosis in the sites those have been destined in the acute phase as the candidate sites for future fibrosis.

Fatty acid is one of the main targets of free radical attack, and its peroxidation leads to lethal cell injury^{26,27}. C16:0, C18:0, C18:1 and C18:2 in rat lung cell debris and nuclei as well as in microsomal membranes decreased within 192 h observation period after paraquat exposure (125 mg/kg orally), and concluded that the results indicated a probable weakening of lipid structure of the membranes⁹. The reduction of these fatty acids should be due to lipid peroxidation. C18:2, C18:3 and C20:4 react well with hydroperoxy radical²⁸, and their peroxidation should affect arachidonic acid cascade. It was suggested that 12-lipoxygenase activity was regulated by reactive oxygen species²⁹. Superoxide radicals produced by oxidative stress may modulate arachidonic acid-lipoxygenase pathway.

It was reported that after 6 days, but not 2 days after paraquat exposure, there was a large increase in the proportion of C20:4 in rat lung, and the changes could be mainly attributed to the increase in numbers of alveolar macrophages⁹. Because the dose (125 mg/kg) and the giving method (orally) were different from us, there were several differences in the results. But the increase of C20:4 is noteworthy. Their observation period was only 6 days, but in our experiment the elevation of C20:4 continued for 28 days, and the level was obviously higher than both the 0 day and the 28th day control levels. It was reported that unsaturated fatty acids in surfactant free fatty acids were significantly increased during the development of bleomycin-induced pulmonary fibrosis between 3 and 120 days after treatment³⁰. In our study, P/S ratio had once reduced between the 2nd and the 7th days, and then increased up to the 28th day. Hydroxyproline also increased between the 14th and the 28th days. The increase of unsaturated fatty acids, especially C20:4 might be

related to collagen synthesis.

The activity of the rat lung fatty acid desaturase system decreased for 24 h after paraquat administration (20 mg/kg i.p.), but the desaturase activity was stimulated 14 days after paraquat treatment³¹⁾. Dietary C20 : 5 inhibited bleomycin-induced pulmonary fibrosis⁵⁾, and C20 : 5 was effective in the lung damage of cystic fibrosis by leukotriene B₄⁶⁾. Bleomycin induced marked elevation of tissue hydroxyproline, and elevated generation of C20 : 4 metabolites which were inflammatory mediators⁷⁾. In the present study C20 : 5 had once increased during the first 2 days and decreased gradually, while C20 : 4 maintained high level in this period. C22 : 6 increased after paraquat administration and maintained high level up to the 28th day, and the level was higher than both the 0 day and the 28th day control levels. This result indicated that desaturation and elongation in n-3 series fatty acids were accelerated after paraquat treatment, and consequently C20 : 5 was rapidly converted into C22 : 6 and decreased. From these results, paraquat might cause elevation of unsaturated fatty acids, especially C20 : 4 but not C20 : 5 by the stimulation of the fatty acid desaturase system, and could consequently stimulate local collagen synthesis by C20 : 4 metabolites in the healing stage. How paraquat stimulates desaturase activity in such late phase should be clarified in the further examination.

ACKNOWLEDGMENTS

The experiments presented in this paper comply with the current laws of Japan and have been approved by the Experimental Animal Care and Use Committee of Fukuoka University (No. 0011331).

REFERENCES

1. Motomiya M. Fibrogenesis and glycoconjugates. *Nihon Kyobu Shikkan Gakkai Zasshi*, **27** : 418-421, 1989.
2. Pozzi E, Luisetti M, Spialtini L, Coccia P, Rossi A, Donnini M, Cetta G, Salmona M. Relationship between changes in alveolar surfactant levels and lung defence mechanisms. *Respiration*, **55** Suppl 1 : 53-59, 1989.
3. Hellerich U, Reinbold WD, Logemann E. Structural changes in the lung in the late stage of fetal paraquat poisoning. *Beitr Gerichtl Med*, **48** : 81-86, 1990.
4. Selman M, Montano M, Montfort I, Perez-Tamayo R. A new model of diffuse interstitial pulmonary fibrosis in the rat. *Exp Mol Pathol*, **43** : 375-387, 1985.
5. Kennedy JJ Jr, Chandler DB, Fulmer JD, Wert MB, Grizzle WE. Dietary fish oil inhibits bleomycin-induced pulmonary fibrosis in the rat. *Exp Lung Res*, **15** : 315-329, 1989.
6. Lawrence R, Sorrell T. Eicosapentaenoic acid in cystic fibrosis: evidence of a pathogenetic role for leukotriene B₄. *Lancet*, **342** : 465-469, 1993.
7. Ziboh VA, Yun M, Hyde DM, Giri SN. gamma-Linolenic acid-containing diet attenuates bleomycin-induced lung fibrosis in hamsters. *Lipids*, **32** : 759-767, 1997.
8. Fletcher K, Wyatt I. The composition of lung lipids after poisoning with paraquat. *Br J Exp Pathol*, **51** : 604-610, 1970.
9. Beretta C, Fadini L, Montesissa C, Pompa G, Stoppani E. Membrane lipid composition

- of subcellular fractions from lungs of rats treated with paraquat. *Pharmacol Res Comm*, **13**: 433-442, 1981.
10. Matkovics B, Barabas K, Mezes M. Effects of gramoxone-induced reactive oxygen radicals on eicosanoid synthesis of mouse lung. *Acta Biol Hung*, **39**: 351-359, 1988.
 11. Fukushima T, Abe K, Nakagawa A, Yamane Y. Fatty acid composition of plerocercoid and adult of *Spirometra erinacei* and the host-parasite relationship. *Int J Parasitol*, **18**: 27-31, 1988.
 12. Matsumura S, Kataoka H, Makita M. Capillary gas chromatographic analysis of protein amino acids as their N(O,S)-isobutoxycarbonyl methyl ester derivatives. *Biomed Chromatogr*, **9**: 205-210, 1995.
 13. Sharp CW, Ottolenghi A, Posner HS. Correlation of paraquat toxicity with tissue concentrations and weight loss of the rat. *Toxicol Appl Pharmacol*, **22**: 241-251, 1972.
 14. Murray RE, Gibson JE. Paraquat disposition in rats, guinea pigs and monkeys. *Toxicol Appl Pharmacol*, **27**: 283-291, 1974.
 15. Yasaka T, Okudaira K, Fujito H, Matsumoto J, Ohya I, Miyamoto Y. Further studies of lipid peroxidation in human paraquat poisoning. *Arch Intern Med*, **146**: 681-685, 1986.
 16. Fukushima T, Tawara T, Isobe A, Hojo N, Shiwaku K, Yamane Y. Radical formation site of cerebral complex I and Parkinson's disease. *J Neurosci Res*, **42**: 385-390, 1995.
 17. Barnes JM. Poisons that hit and run. *New Scientist*, **38**: 619-620, 1968.
 18. Rennard SI, Bitterman PB, Crystal RG. Current concepts of the pathogenesis of fibrosis: lessons from pulmonary fibrosis. *Prog Clin Biol Res*, **154**: 359-377, 1984.
 19. Kaetsu A, Fukushima T, Inoue S, Lim H, Moriyama M. Role of heat shock protein 60 (HSP60) on paraquat intoxication. *J Appl Toxicol*, **21**: 425-430, 2001.
 20. Yamaguchi M, Takahashi T, Togashi H, Arai H, Motomiya M. The corrected collagen content in paraquat lungs. *Chest*, **90**: 251-257, 1986.
 21. Masaoka T, Akahori F, Arai S, Sakaguchi K. Effect of paraquat on plasma fibronectin, serum free hydroxyproline, serum ceruloplasmin and lung collagen content in monkeys. *J Toxicol Sci*, **12**: 329-340, 1987.
 22. Block ER, Schoen FJ. Depression of serotonin uptake by rat lungs exposed to paraquat. *J Pharmacol Exp Ther*, **221**: 254-260, 1982.
 23. Dubaybo BA, Durr RA, Thet LA. Unilateral paraquat-induced lung fibrosis: evolution of changes in lung fibronectin and collagen after graded degrees of lung injury. *J Toxicol Environ Health*, **22**: 439-457, 1987.
 24. Griffin M, Smith LL, Wynne J. Changes in transglutaminase activity in an experimental model of pulmonary fibrosis induced by paraquat. *Br J Exp Pathol*, **60**: 653-661, 1979.
 25. Darr D, Ccombs S, Murad S, Pinnell S. Studies on the inhibition of collagen synthesis in fibroblasts treated with paraquat. *Arch Biochem Biophys*, **306**: 267-271, 1993.
 26. Tomita M, Okuyama T, Ueki A, Watanabe H, Kawai S. Combined action of paraquat and superoxide on the peroxidation of detergent-dispersed linolenic acid. *Biochim Biophys Acta*, **1128**: 174-180, 1992.
 27. Sugihara N, Suetsugu T, Furuno K. High susceptibility to paraquat-driven lipid peroxidation of cultured hepatocytes loaded with linolenic acid. *J Pharmacol Exp Ther*, **274**: 187-193, 1995.
 28. Bielski BJJ, Arudi RL, Sutherland MW. A study of the reactivity of HO₂/O₂⁻ with unsaturated fatty acids. *J Biol Chem*, **258**: 4759-4761, 1983.
 29. Muller K, Gawlik I. Effects of reactive oxygen species on the biosynthesis of 12 (S)-hydroxyeicosatetraenoic acid in mouse epidermal homogenate. *Free Radic Biol Med*, **23**: 321-330, 1997.
 30. Swendsen CL, Skita V, Thrall RS. Alterations in surfactant neutral lipid composition during the development of bleomycin-induced pulmonary fibrosis. *Biochim Biophys Acta*, **1301**: 90-96, 1996.
 31. Montgomery MR. Interaction of paraquat with the pulmonary microsomal fatty acid desaturase system. *Toxicol Appl Pharmacol*, **36**: 543-554, 1976.